

NOWOTWORY 2000 / tom 50

Zeszyt 3 / 241–246

Original contributions

Large core needle biopsy of nonpalpable breast lesions

Ewa Wesołowska¹, Ewa Dziewulska¹, Justyna Oknińska¹,
Monika Nagadowska², Danuta Pietrow³

Introduction. An increasing number of nonpalpable abnormalities requiring breast biopsy are being identified due to the widespread use of screening mammography. The advantage of large-core needle biopsy (LCNB) is that it allows histologic examination. The aim of the study was to present our own experience with LCNB and to determine the value of LCNB in the diagnosis of nonpalpable breast lesions.

Material and methods. A total of 443 LCNB were done during the study period from December 1994 to June 1999. Biopsy were performed with 14-gauge needle with stereotactic or ultrasound guidance. Microcalcifications constituted 90% of all lesions. From each lesion 1–11 (mean 5) cores were taken. Radiography of core specimens was performed in cases in which the target lesion contained microcalcifications.

Results. 84 malignancies were identified. Surgical intervention was performed in 146 cases. Concordance between histologic findings in the core and surgical sample was 86%. Specimen radiography of breast microcalcifications should be routinely performed to ensure appropriate histological tissue. LCNB achieved good diagnostic yield with 5 specimens or more. One cancer was found among 295 women with benign lesions in LCNB in whom follow-up examinations were performed.

Conclusion. With sufficient experience, LCNB may prove to be an acceptable alternative to surgical biopsy in women with breast lesions suspected at mammography.

Biopsja gruboigłowa w niewyczuwalnych zmianach piersi

Wstęp. Rozpowszechnienie badań skryningowych spowodowało wzrost liczby zmian subklinicznych piersi, wymagających weryfikacji mikroskopowej. Biopsja gruboigłowa (BG) jest od niedawna stosowaną procedurą diagnostyczną, pozwalającą na uzyskanie rozpoznania histopatologicznego. Celem pracy była ocena wartości BG.

Materiał i metoda. W okresie od grudnia 1994 do czerwca 1999 r. wykonano 443 BG w niewyczuwalnych zmianach sutka. Mikrozwapnienia stanowiły 90% zmian. Biopsje wykonywano pod kontrolą mammografii (401 przypadków) lub USG (42 przypadki), igłą o średnicy 2,1 mm, z użyciem automatycznego działła. Każdorazowo pobierano średnio 5 preparatów tkankowych do badania histopatologicznego.

Wyniki. Zmianę złośliwą rozpoznano w 84 przypadkach (19%). Operowano 146 chorych. Zgodność rozpoznań dla przypadków operowanych wynosiła 86%. Wykazano zależność między liczbą pobranych preparatów i obecnością w nich mikrozwapnień, a wynikami histopatologicznymi. Wśród 295 kobiet z rozpoznaniem zmiany łagodnej w BG, u których wykonano badania kontrolne, w trakcie obserwacji stwierdzono jeden przypadek raka.

Wnioski. Biopsja gruboigłowa może stanowić alternatywę dla biopsji chirurgicznej pod warunkiem dobrego opanowania techniki badania.

Key words: breast carcinoma, mammography, large core needle biopsy

Słowa kluczowe: rak sutka, mammografia, biopsja gruboigłowa

Introduction

Extensive use of screening programs for breast cancer has led to an increase in the number of detected nonpalpable lesions found in mammography. Microscopic verification of every detected lesion by means of a surgical biopsy is not necessary and, what is more, impossible

¹ Department of Radiology

² Department of Breast Cancer

³ Department of Pathology

The Maria Skłodowska-Curie Memorial Cancer Center and Institute of Oncology, Warsaw, Poland

from the practical standpoint. Large-core needle biopsy (LCNB) is an alternative to diagnostic surgical procedures. According to literature reports, this method has been widely appraised in the diagnosis of breast lesions as less invasive, more rapid and economically advisable [1-6].

The aim of this paper is to present our own experiences acquired during several years of LCNB use and analysis of its usefulness in clinically symptomless breast lesions with particular reference to mammographically detected microcalcifications.

Material and methods

Between December 1992 and June 1999, LCNB was performed in 443 cases of nonpalpable lesions revealed by mammography. Biopsy was performed in 360 cases where microcalcifications

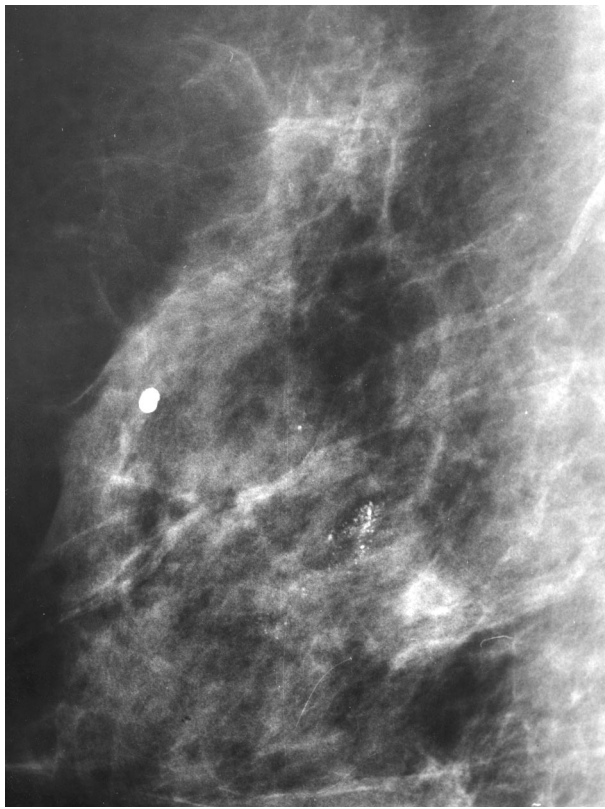


Fig. 1b. BIRADS „4” – Granular microcalcifications. Pathology: atypical ductal hyperplasia

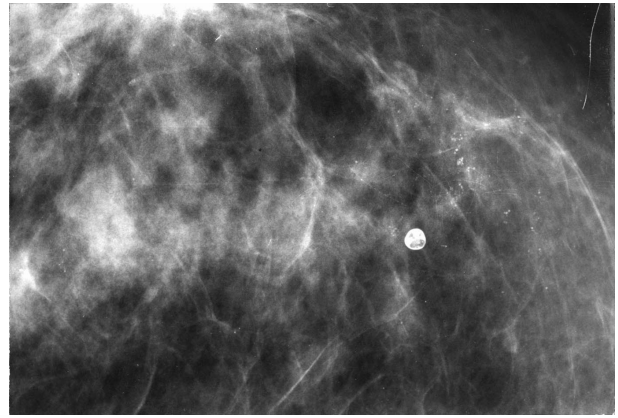


Fig. 1 a. BIRADS „3” – Round, regular microcalcifications. Pathology: fibrocystic changes

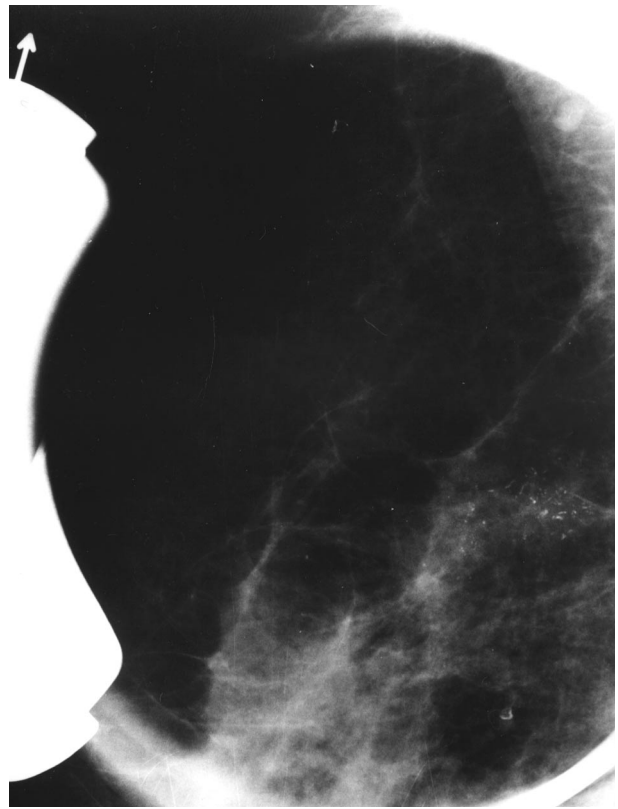


Fig. 1c. BIRADS „5” – Cluster of fine linear branching microcalcifications. Pathology: ductal carcinoma in situ

were the predominating finding and in 83 cases of the presence of nodular changes. For each lesion the probability of malignancy was predicted determining its category according to the BI-RADS classification (Breast Imaging Reporting and Data System) acc. to which category 3 stands for a probably benign lesion, category 4 – a probably malignant lesion and category 5 a malignant lesion (Fig.1).

All biopsies were performed with a 2.1 mm diameter (14G) needle using an automatic gun (Biopty, Bard) with a shooting range 23 mm. In 401 cases biopsy was done under mammographic guidance using a device for invasive stereotactic procedures connected with digital image processing (Lorad DSM). In 42 cases of nodular lesions the procedure was performed under ultrasound (US) control (HDI 3000 ATL). All stereotactic procedures were carried out by radiologists specialized in invasive

diagnostic procedures. In 16 cases the biopsies were carried out under US guidance by a surgeon cooperating with a radiologist. The choice of guidance modality was determined by the radiologist.

Every procedure provided from 1 to 11 core biopsy specimens for histological examination (mean: 5). If microcalcifications were discerned the specimens were subjected to radiography in order to confirm their presence within the tissue sample. Indications for surgical intervention were as follows:

- diagnosis of malignancy
- diagnosis of atypical lesions
- high probability of malignancy in mammographic examination independently of LCNB results
- absence of microcalcifications in the obtained cores both on X-ray films and in histological examination.

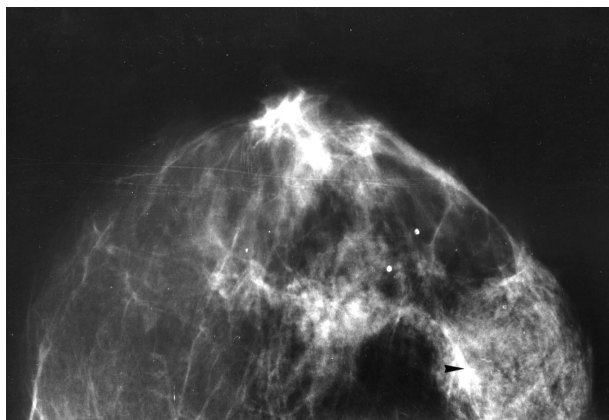


Fig. 2 a. Cluster of fine, irregular microcalcifications.
Pathology: LCNB – fibrocystic changes

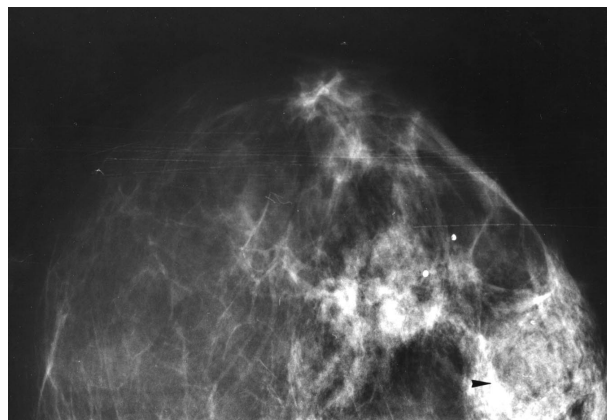


Fig. 2 b. After 6 months increasing in number of microcalcifications (b' – magnified view). Pathology: Excisional biopsy – invasive lobular carcinoma 5 mm in size

Results

Histological examination of 443 samples revealed 84 cases of malignant lesions, with ductal carcinoma in situ (DCIS) in 46 cases. In 359 cases benign lesions were found, among them fibrocystic changes in 308 cases, atypical ductal hyperplasia (ADH) in 28 cases, fibroadenoma in 7 cases and normal glandular tissue in 16 cases.

In 295 cases of benign lesions diagnosed by LCNB there followed a suggestion of observation and clinical examination with mammography. In 285 cases it took place after 6 months with stationary mammographic findings in 281 patients. In the four remaining cases an increase of microcalcifications was found and another microscopic verification was suggested; in three cases diagnostic surgical biopsy revealed benign lesions, while in one case carcinoma was found (Fig. 2).

148 patients were qualified for operation, two of them refused surgical treatment despite malignancies in LCNB; 146 patients underwent operation.

In case of 38 patients with invasive carcinoma surgical intervention provided material which confirmed the presence of malignancy in histological examination.

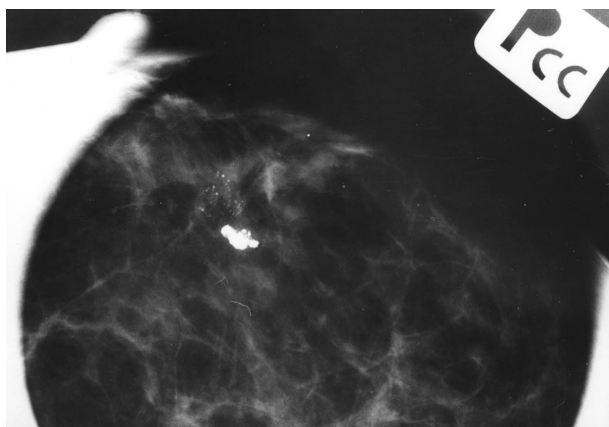


Fig. 3. Close to coarse, popcorn-like calcification cluster of fine, punctate microcalcifications.
Pathology: LCNB – Atypical ductal hyperplasia.
Excisional biopsy – Ductal carcinoma *in situ* closed, but not related to involuting fibroadenoma.

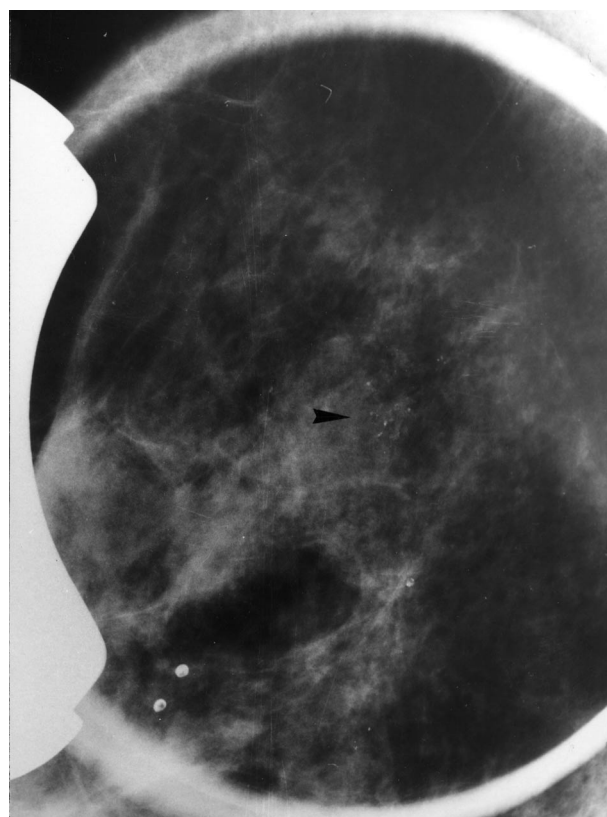

Fig. 2 b'.

The diagnosis of DCIS was confirmed in 32 cases (71%) while in 12 cases (27%) invasive carcinoma coexisted with intraductal component. In one patient no cancer was found in the surgical specimen.

Further analysis of the 28 cases of ADH revealed the following figures: 11 cases (39%) of confirmed diagnosis, 3 cases (11%) of benign lesions without atypia, 14 cases (50%) of malignancy, including 7 cases of DCIS (Fig. 3).

Despite a diagnosis of benign lesions in LCNB 20 patients qualified for surgical biopsy because the changes found in mammographic picture were highly suggestive of malignancy. Among them 11 carcinomas were found in

postoperative histological examination, including 7 cases of DCIS.

In 23 cases microcalcifications were not revealed in specimen radiographies and histological examinations. Surgical biopsy was performed in 21 of these patients revealing 8 cases (38%) of carcinoma. It shows that the accuracy of diagnosis by histological examination depends on the presence of microcalcifications in the core biopsy specimens (Table I).

Tab. I. Biopsy results related to the presence of microcalcifications in radiography of core specimens (in 121 cases of microcalcifications)

Microcalcifications in core specimens	LCNB versus excisional biopsy	
	Concordant	Discordant
yes	90	10
no	13	8
p<0.001		

In the group of 146 surgically treated patients there were 42 cases in which LCNB provided from 1 to 4 core biopsy specimens. In this group the diagnoses were correct in 57% of cases. However when 5 to 11 specimens were taken the histological diagnosis was correct in 95 out of 104 cases (91%) (Table II).

Tab. II. Biopsy results related to the number of core biopsies.

No. of cores	LCNB versus excisional biopsy	
	Concordant	Discordant
1-4	24	18
5-11	95	9
p<0.001		

The results of histological examinations after LCNB and after surgical biopsy are compared in Table III. Complete concordance between core biopsy findings and surgical findings was found in 107 cases (73%) including a case of carcinoma correctly diagnosed after LCNB but not found in the surgical specimen. Partial concordance

occurred in 19 cases (13%). This group includes ADH cases with a final diagnosis of DCIS and cases of DCIS found to be invasive in surgical biopsy material.

A lack of concordance in diagnosis occurred in 20 cases (14%) initially pronounced as benign lesions, and found to be malignant in postoperative verification.

Table IV presents the diagnostic value of LCNB. The sensitivity of the method is 75%, specificity – 100%. In the entire material consisting of 443 patients undergoing LCNB there were only two cases (0.5%) of complications: in one case moderately profuse bleeding rendered completion of the procedure impossible, however surgical intervention was not necessary; in another case infection developed, successfully treated with antibiotics.

Tab. IV. Diagnostic value of LCNB

	Ex. biopsy		
	+	-	
LCNB +	82	0	82
LCNB -	27	37	64
Total	109	37	146

Discussion

Nonpalpable lesions detected in mammography demand microscopic verification, which is indispensable for establishing diagnosis and applying adequate treatment. The accepted standard management is surgical removal of the lesion under image guidance followed by histological examination. This is an invasive procedure associated with certain risks, costly and not necessarily effective [7]. In many clinical centers stereotactic fine-needle biopsy has been introduced in diagnostic management as a more simple and effective method [8-10] however it has significant drawbacks. Insufficient sampling rates range from 6% to 47%, false negative results occur in 1% to 31% of cases, false positive results occur also, but sporadically (below 1%). It is not possible to differentiate between in situ and invasive carcinomas. Cytological examination must be performed by a specially trained pathologist. For

Tab. III. Comparison of histopathologic results of LCNB and excisional biopsy

LCNB	Excisional biopsy				Total
	Benign lesions	Atypical ductal hyperplasia	Ductal carcinoma in situ	Invasive carcinoma	
Benign lesions	19	4	7	6	36
Atypical ductal hyperplasia	3	11	7	7	28
Ductal carcinoma in situ	1		32	12	45
Invasive carcinoma				37	37
Total	23	15	46	62	146

these reasons, LCNB seems most appropriate for obtaining tissue fragments for histological examination. The pathologist can establish a final diagnosis with a more complete characterization of malignant lesions or may recognize the type of benign lesions. Diagnostic effectiveness of LCNB equals that of surgical biopsy being, at the same time, less invasive and bringing on no changes in mammographic pattern or skin scar [1-3, 11]. If a lesion observed in mammography may be discerned under US the biopsy should be performed under ultrasound guidance. Such a procedure is less time-consuming, less costly and allows for a more correct estimation of the actual position of needle tip in relation to the lesion. A perusal of the pertinent literature shows that the percentage of US-guided biopsies ranges from 0% to 60% in various centers [3]. In our laboratory about 10% of biopsies were US-guided, performed exclusively in cases of nodular lesions.

An important factor affecting the quality of the results is the experience of the radiologist performing this procedure. In our material a majority of the false negative results occurred in the initial period of LCNB introduction as a diagnostic method.

The presented results assessing LCNB value are somewhat poorer than those reported in literature, in which the unison of LCNB diagnoses with the results of surgical biopsy frequently exceeded 90% and the ratio of false negative results was below 10% [1-3]. This is evidence of LCNB limitations as a diagnostic method which are due, most frequently, to inadequate calibration of the unit, faulty localization of the lesion or qualifying lesions below 5 mm for the procedure i.e. too small in size.

Significant diagnostic problems are encountered in cases of ADH diagnosed by LCNB, since their differentiation against DCIS is difficult. Therefore all cases of ADH should be verified by surgical biopsy. According to literature data the amount of carcinoma found in surgical specimens reaches 50% [12, 13].

The concordance between the results of histological examinations of LCNB material and postoperative results depends also on the number of core biopsy specimens obtained during the procedure and the presence of microcalcifications in the samples. In our material the percentage of false negative results was high (38%) when no microcalcifications were found either in specimen radiographies and on histological examination. This was probably caused by erroneous localization of the biopsy site.

There exist no absolute contraindications to LCNB. When the procedure is performed under mammography guidance the limitations result from technical difficulties eg. lesions situated at the periphery (that is near the chest wall or skin), or in cases of small breasts with thickness after compression insufficient for biopsy gun shot (breast thickness below 3 cm).

LCNB is well tolerated by the patients and only rarely causes major complications, such as bleeding requiring surgical intervention, purulent mastitis requiring drainage and antibiotic treatment or pneumothorax [3, 6].

In the population of women with lesions detected by screening mammography the majority of findings are probably benign (BIRADS 3). In these cases negative LCNB results confirms the benign character of the lesions. After a time interval previously unrecognized malignant lesions may occur which had not been recognized before despite correctly performed LCNB. These cases are rare and owing to slow progression the prognosis is usually good despite a delay in diagnosis and treatment. LCNB was shown to produce no changes in the breast, contrary to surgical biopsy [11] and thus control mammographic examinations are more effective after LCNB than after surgical biopsy.

In recent years vacuum assisted biopsy (VAB) has been introduced for invasive procedures. This method is an automated biopsy gun-needle combinat with a directional, stereotactic, vacuum-assisted biopsy system. The procedure has all the advantages of LCNB and ensures better quality of the obtained samples. An important advantage is the possibility of obtaining many, samples without removing the needle and cutting samples of a greater volume. According to literature data the percentage of false negative results does not exceed 5% [16-18].

Conclusions

On the basis of the presented material it may be stated that LCNB renders histological diagnosis of nonpalpable breast lesions without the necessity of performing costly and risky open biopsy possible in most cases. At least five core specimens should be taken for histological examination and, in case of microcalcifications, their presence should be ascertained. The results of mammography must be considered when planning further management. Obtaining high value diagnostic results requires mastering the procedure technique and acquiring extensive experience as well as close cooperation of radiologists, surgeons and pathologists.

Ewa Wesolowska M.D., Ph.D.

Department of Radiology
The Maria Skłodowska-Curie Memorial Cancer Center and
Institute of Oncology
W.K.Roentgena 5, 02-781 Warsaw, Poland

References

1. Parker SH, Lovin JD, Jobe WE, et al. Stereotactic breast biopsy with a biopsy gun. *Radiology* 1990; 176: 741-747.
2. Parker SH, Lovin JD, Jobe WE, et al. Nonpalpable breast lesions: stereotactic automated large-core biopsies. *Radiology* 1991; 180: 403-407.
3. Parker SH, Burbank F, Jackman RJ, et al. Percutaneous large-core breast biopsy: a multi-institutional study. *Radiology* 1994; 193: 359-364.
4. Gisvold JJ, Goellner JR, Grant CS, et al. Breast biopsy: a comparative study of stereotactically guided core and excisional techniques. *AJR* 1994; 162: 815-820.

5. Lee CH, Eglin TK, Philpotts L, et al. Cost-effectiveness of stereotactic core needle biopsy: analysis by means of mammographic findings. *Radiology* 1997; 202: 849-854.
6. Meyer JE, Smith DN, Lester SC, et al. Large-core needle biopsy of non-palpable breast lesions. *Jama* 1999; 281: 1638-1641.
7. Jackman RJ, Marzoni FA. Needle-localized breast biopsy: why do we fail? *Radiology* 1997; 204: 677-684.
8. Azavedo E, Svane G, Auer G. Stereotactic fine needle biopsy i 2594 mammographically detected non-palpable lesions. *Lancet* 1989; 1: 1033-1036.
9. Ciatto S, Rosselli del Turco M, Bravetti P. Nonpalpable breast lesions: stereotaxic fine-needle aspiration cytology. *Radiology* 1989; 173: 57-59.
10. Sheikh FA, Tinkoff GH, Kline TS, et al. Final diagnosis by fine-needle aspiration biopsy for definitive operation in breast cancer. *Am J Surg* 1987; 154: 470-474.
11. Kaye MD, Vicinanza-Adami CA, Sullivan ML. Mammographic findings after stereotaxic biopsy of the breast performed with large-core needles. *Radiology* 1994; 192: 149-151.
12. Liberman L, Cohen MA, Dershaw DD, et al. Atypical ductal hyperplasia diagnosed at stereotaxic core biopsy of breast lesions: an indication for surgical biopsy. *AJR* 1995; 164: 1111-1113.
13. Brown T, Wall J, Christiansen E, et al. Atypical hyperplasia in the era of stereotactic core needle biopsy. *J Surg Oncol* 1998;67: 168-173.
14. Liberman L, Evans WP, Dershaw DD, et al. Radiography of microcalcifications in stereotaxic mammary core biopsy specimens. *Radiology* 1994; 190: 223-225.
15. Liberman L, Dershaw DD, Rosen PP, et al. Stereotaxic 14-gauge breast biopsy: how many core biopsy specimens are needed? *Radiology* 1994; 192: 793-795.
16. Heywang-Kobrunner SH, Schaumloffel U, Viehweg P, et al. Minimally invasive stereotaxic vacuum core breast biopsy. *Eur Radiol* 1998; 8: 377-85.
17. Jackman RJ, Marzoni FA, Nowels KW. Percutaneous removal of benign mammographic lesions: comparison of automated large-core and directional vacuum-assisted stereotactic biopsy techniques. *AJR* 1998; 171: 1325-30.
18. Burbank F. Stereotactic breast biopsy of atypical ductal hyperplasia and ductal carcinoma in situ lesions: improved accuracy with directional, vacuum-assisted biopsy. *Radiology* 1997; 202: 843-847.

Paper received 19 January 2000

Accepted 17 May 2000