

The value of hysteroscopy in the diagnosis and treatment of persistent trophoblastic disease - a preliminary report

Mariusz Bidziński

Background. Persistent trophoblastic disease (PTD) may cause a diagnostic and therapeutic dilemma. Hysteroscopy helps to inspect the uterine cavity, allows to take the biopsy and also to remove the tumor. The purpose of this study was to estimate the value of hysteroscopy in the diagnosis and treatment of PTD under visual control.

Material and methods. Since 1995 to 1999 ten patients with PTD were treated with the use operative hysteroscopy. The initial diagnosis was obtained using USG examination.

Results. The tumor was visualised by hysteroscopy in all patients. Removal of tumor resulted in over 84% reduction HCG level in 9 patients. In these cases the volume of the tumor did not exceed 4cc. Partial tumor resection was done in the remaining case with larger volume due to excessive bleeding.

Conclusion. This preliminary report indicates that hysteroscopy may be effective in diagnosis and treatment of patients with persistent trophoblastic disease.

Wartość histeroskopii w diagnostyce i leczeniu przetrwałej ciąży choroby trofoblastycznej - doniesienie wstępne

Wstęp. Przetrwała ciążowa choroba trofoblastyczna (PTD) może stanowić problem terapeutyczny. Pomimo doskonałych wyników chemioterapii, w przypadku izolowanych ognisk w macicy, istnieje możliwość ich usunięcia przy użyciu histeroskopii. W ten sposób eliminujemy konieczność stosowania leczenia uzupełniającego lub ograniczamy liczbę wlewów chemioterapii. Docelową korzyścią jest zmniejszenie lub wyeliminowanie toksycznych efektów chemioterapii. Histeroskopia pozwala dokładnie uwidocznnić endometrium, pobrać materiał do badania histopatologicznego, a także usunąć patologiczne ogniska w macicy. Celem pracy była wstępna ocena przydatności histeroskopii do leczenia chorych na PTD.

Materiał i metodyka. Badaniem objęto grupę 10 chorych z rozpoznaniem PTD, leczonych w latach 1995-1999. U wszystkich chorych, za pomocą badania USG, uwidoczniiono przetrwałe ogniska choroby w macicy. Stosując technikę histeroskopii operacyjnej, usuwano patologiczne ogniska z macicy.

Wyniki. U 9 chorych wykonany zabieg spowodował obniżenie stężeń HCG powyżej 84% w stosunku do stężenia wyjściowego. U jednej chorej z guzem o objętości 7,4 cm³ zabieg powikłany był krwawieniem z wnętrza macicy, co uniemożliwiło dokładne wycięcie zmiany. Dwie chore po wykonaniu histeroskopowej resekcji nie wymagały żadnego uzupełniającego leczenia. Optymalny wynik zabiegu uzyskiwano przy objętości guza nie przekraczającej 4 cm³.

Wnioski. Pomimo wstępnego charakteru doniesienia należy podkreślić, że metoda potwierdziła swoją przydatność w leczeniu chorych na przetrwałą ciążową chorobę trofoblastyczną.

Key words: gestational trophoblastic disease, hysteroscopy, ultrasound

Słowa kluczowe: ciążowa choroba trofoblastyczna, histeroskopia, ultrasonografia

Hydatid mole (GTD) is a trophoblast proliferation resulting from abnormal differentiation of a fertile egg cell. In Poland, GTD is recognized in one case out of 2000 pregnancies. The diagnosis is based on histopathological

examination of tissue removed from the uterine cavity. In a majority of cases, a whole hydatid mole is removed from the uterus. However, in some patients, the parts of trophoblast may remain and produce chorionic gonadotropin (HCG). Persistent trophoblastic disease is recognized in such cases. The quantity of HCG depends on the mass and histopathological type of tumor. HCG blood level is often very high.

The removal of hydatid mole tissue is difficult due to a considerable softness of uterus wall caused by trophoblast infiltration and congestion of myometrium. Therefore, some interventions are inconclusive. Hysteroscopy allows a more precise inspection of the uterine cavity and, eventually, the removal of the remaining parts of the molar tissue. It may limit or eliminate chemotherapy in individual cases.

The purpose of this study was to estimate the usefulness of hysteroscopy in diagnosis and removing of pathological tissue under visual control.

Materials and methods

Since January 1995 to July 1999 ten patients with microscopically confirmed non metastatic persistent trophoblastic disease were treated with the use of operative hysteroscopy. The time gap after uterine cavity curettage ranged from 2 to 5 months. Persistent elevated level of HCG was the indication for operation. Distant spread was excluded by imaging techniques.

HCG blood concentration was determined two hours before operation and two and seven days after hysteroscopy procedure. Whole removed tissue was sent for histopathological examination.

In addition, the size of molar tumor assessed by transvaginal USG was compared with that obtained by hysteroscopy. Storz resectoscope with Hamou II optics was used. Uterine cavity was filled with 1.5% glycine solution by Storz endomat. Resectoscope was connected to a Storz Autocon 350 surgical diathermy. This type of equipment allows not only to cut tissue, but also to coagulate with a „spray” function, enabling a fast and effective haemostasis. All procedures were performed under general anesthesia.

Results

The volumes of the tumor ranged 0.8-7.4 cc, was shown by transvaginal USG examination performed before hysteroscopy. The values of HCG blood concentration and results of USG examination before and after the treatment are presented in Tables I and II.

Pathological lesions in the uterine cavity were shown during hysteroscopy in all patients. Majority of them looked like a polypus with light red color. Their surfaces bled after a soft touch. The time of operation ranged between 7 and 35 minutes. All visible lesions were removed in nine cases. In the remaining case only partial tumor resection was done due to of the size of tumor and intensive bleeding. Only a slight decrease of HCG blood level and tumor size as assessed by USG examination was observed (patient 1). No complications during and after operations were observed (see Tables I and II).

Histopathological examination showed choriocarcinoma in 3 patients, invasive mole in one case and hydatid mole in the remaining cases. Chemotherapy was introduced in 8 patients due to persistence of higher HCG blood concentration. In two patients (case 9 and 10), such treatment was not required. HCG blood levels returned to normal three weeks after hysteroscopy.

Discussion

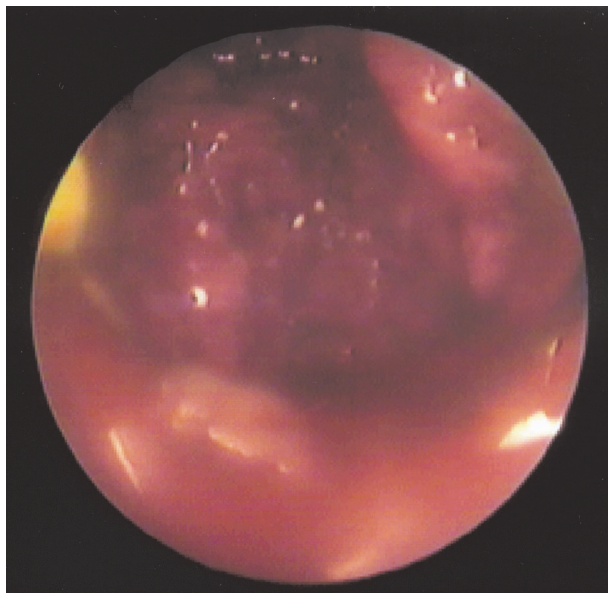
Residues of hydatid mole inside uterine cavity may lead to the development of persistent gestational trophoblastic di-

Tab. I. HCG blood levels in patients with PTD before and after hysteroscopy

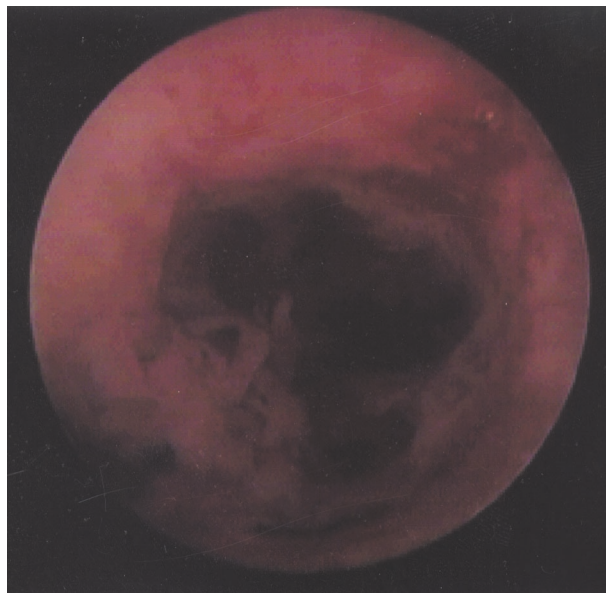
No	HCG – before treatment (IU/l)	HCG – 2 days after hysteroscopy (IU/l)	HCG – 7 days after hysteroscopy (IU/l)	Percent of HCG decrease in 7th day in comparison with initial level
1	300000	283000	254670	15%
2	111245	62200	17572	84%
3	22108	17320	380	98%
4	19110	17920	512	97%
5	17435	11932	1202	93%
6	11200	7429	1206	89%
7	9870	1759	174	98%
8	7205	1274	183	97%
9	1125	417	79	93%
10	720	104	26	96%

Tab. II. The volume of uterine lesions before and after hysteroscopy treatment

No	USG before hysteroscopy (cc)	USG – 2 days after hysteroscopy (cc)	USG – 7 days after hysteroscopy (cc)	Percent of decrease of tumor capacity in 7 days in comparison with initial size
1	7.4	5.3	6.2	16%
2	4.2	1.4	1.2	71%
3	2.1	1.1	1.2	43%
4	2.4	1.5	0.8	67%
5	1.7	0.7	0.4	76%
6	2.1	1.3	0.9	57%
7	3.1	1.1	0.8	74%
8	1.1	0.4	0	100%
9	1.0	0.3	0	100%
10	0.7	0.4	0	100%



Ryc. 1. The picture of choriocarcinoma lesion inside uterine cavity



Ryc. 2. The picture of uterine cavity just after the removal of choriocarcinoma lesion

sease (PTD). Such syndrom occurs in 18-29% of pregnancies with complete mole, and 2-4% of patients with partial mole [1, 2]. Histologically PTD may have a nature of mole or choriocarcinoma. A distinction between these two types of trophoblast pathologies is crucial for optimal selection of treatment. The diagnosis of choriocarcinoma qualifies a patient to a high risk group and requires polichemotherapy [3]. Unfortunately, precise histological diagnosis of PTD is not always performed. This may result in a suboptimal treatment.

Berkowitz i Goldstein [4, 5] observed a resistance to chemotherapy in 6.4% cases of clinical stage I of GTD. All these patients were included into a high risk group because choriocarcinoma diagnosis.

Hysteroscopy, allows a precise evacuation of lesions from the uterine cavity. The magnification of picture allows to take a precise biopsy.

Hysteroscopy is not widely used in the treatment of PTD [6-10]. Our initial experience is very promising. In nine cases the tumor size was significantly reduced and HCG serum levels were also reduced. Two patients avoided chemotherapy after successful evacuation of molar tissue. This method may contribute to a reduction of the number of chemotherapy courses to obtain total remission. The size of tumor influences the number of courses of chemotherapy. It is also a significant factor in statistical analysis [11].

Hysteroscopic operations are more effective in patients with small tumors, with the volume of less than 4 cc. In such cases in our group HCG levels decreased by as much as 84%. Bigger tumors caused more technical difficulties and they should be qualified to the other type of therapy, or be done by a very experienced surgeon. There is a clear border between pathological changes and a normal tissue in small and limited tumors. The safety of operations is than higher. We suggest that patients with small tumors should be qualified to this method of treat-

ment. Electric resectoscope with a „spray” coagulation is very helpful in achieving effective haemostasis.

It should be stressed that endoscopy method of treatment limits a necessity of hysterectomy in cases in which the tumor is chemoresistent. Future investigations may result in a more detailed evaluation of the advantages and eventual disadvantages of this method.

Conclusions

1. Hysteroscopy should be considered as a useful method of treatment of non metastatic persistent trophoblastic disease.
2. Hysteroscopy is particularly useful in small tumors (<4 cc). In such cases HCG blood levels decrease by as much as 84%.

Mariusz Bidziński M.D., Ph.D

Department of Gynecological Oncology
The Maria Skłodowska-Curie Memorial Cancer Center
and Institute of Oncology
Roentgena 5
02-781 Warsaw
Poland

References

1. Berkowitz RS, Goldstein DP. Chorionic tumors. *N Engl J Med* 1996; 335: 1740-1748.
2. Freedman RS, Tortorelo – Luna G, Pandey DK et al. Gestational trophoblastic disease. *Obstet Gynecol Clin North Am* 1996; 23: 545-571.
3. Griffiths CT, Silverstone A, Tobias J et al. Gestational Trophoblastic Disease. In: *Gynecologic Oncology*. Barcelona Spain: Mosby Wolfe; 1997, 195-205.
4. Berkowitz R.S, Goldstein DP. Recent advances in gestational trophoblastic disease. *Curr Opin Obstet Gynecol* 1998; 10: 61-64.

5. Berkowitz RS, Goldstein DP. Presentation and management of persistent gestational trophoblastic disease and gestational trophoblastic tumors in the USA. In: Hancock BW, Newlands ES, Berkowitz RS (eds.) *Gestational Trophoblastic Disease*. London: Chapman & Hall Medical; 1997, 157-172.
6. Millar DR. Role of surgery. In.: Hancock BW, Newlands ES, Berkowitz RS (eds.) *Gestational trophoblastic disease*. London: Chapman & Hall Medical; 1997, 217-232.
7. Braendle W. Hysteroscopy in a case of hydatiform mole. In: Van der Pas H, Van Herendael B, Van Lith D, Keith L (eds.). *Hysteroscopy*. MTP Press Ltd; 1983, 134-135.
8. Wilczak M, Sajdak S, Woźniak J, Cwojdzński M et al. Histeroskopia w diagnostyce i leczeniu zmian wewnątrzmacicznych po usunięciu zaśniadu groniastego. *Gin Pol* 1994; 65: 522-526.
9. Flam F, Radestad A. Hysteroscopy in gestational trophoblastic diseases. *Eur J Gynaecol Oncol* 1996; 17: 274-277.
10. Lindholm H, Radestad A, Flam F. Hysteroscopy provides proof of trophoblastic tumors in three cases with negative color doppler images. *Ultrasound Obstet Gynecol* 1997; 9: 59-61.
11. Nevin J, Silcocks P, Hancock B et al. Guidelines for the stratification of patients recruited to trials of therapy for low-risk Gestational Trophoblastic Tumor. *Gynecol Oncol* 2000; 78: 92- 6.

Paper received: 19 September 2000

Accepted: 1 March 2001