

Invited article

Paediatric stereotactic radiosurgery for malignant CNS tumours using CyberKnifeCole A. Giller¹, Brian D. Berger¹, Janice L. Delp¹, Daniel Bowers²

Although the value of stereotactic radiosurgery for the treatment of brain tumours in children is well recognized, the widespread use of stereotactic radiosurgery in paediatrics has been limited by difficulties with rigid fixation for young children, the need for general anaesthesia, and certain characteristics of some paediatric brain tumors which may promote the risk of radionecrosis. The CyberKnife radiosurgery system is both frameless and precise and therefore offers potential solutions to these problems. We review the advantages of frameless radiosurgery for paediatric patients, discuss factors specific to CyberKnife stereotactic radiosurgery for children, and report our preliminary experience with a group of 21 patients.

Key words: stereotactic radiosurgery, paediatrics, CNS tumours

Introduction

Three tragedies mark the use of radiation to treat brain tumours in children. The most obvious is the injustice of fate that forces such young patients to suffer such serious disease. The second tragedy is that brain tumours of childhood tend to have malignant courses and act more aggressively than their counterparts in adults. They are also the most common solid tumours of childhood [1, 2]. The third tragedy is the frustrating fact that what would otherwise be a valuable mainstay of treatment, radiation therapy, is virtually forbidden in young children because of the high risk of devastating cognitive deficits in later life [1, 3-6]. This has produced the common strategy of restricting the treatment of young children to chemotherapy and surgery, hoping to delay until the child is older and the brain better able to withstand radiation. Nevertheless, paediatric oncologists can find themselves facing very aggressive brain tumours in very young patients without a full complement of therapeutic tools.

The possibility that stereotactic radiosurgery (SRS) might restore the use of radiation to the treatment armamentarium is not new and has not been overlooked by the oncology community. Because little radiation is delivered by SRS treatment plans to normal tissue outside the treatment field, the risk of damage to eloquent cortex and the accompanying decline in cognitive function should be vanishingly small. This realisation has prompted

a large number of paediatric centres to incorporate SRS into their treatment strategies [7-27].

Many radiosurgery centres have chosen frame-based systems such as the Gamma Knife to treat paediatric tumours, perhaps motivated by the stringent requirements of SRS for precision. Treatment of infants is prohibited with this method because the fragile infant skull cannot withstand placement of a stereotactic frame required for rigid fixation. Furthermore, rigid fixation in children requires general anaesthesia with its attendant problems of vomiting, tube obstruction and post-extubation croup. These are magnified by the limited airway access imposed by the rigid frame [16, 28]. That such problems can be significant has been shown by a report in 1995 [29] of four serious anaesthetic events in 68 frame-based SRS procedures for children.

A proposed solution to these problems is the use of non-invasive devices to immobilise the head during SRS. However, devices relying on fixation to the teeth with a dental mould (such as the Greitz-Bergstrom method or the Gill-Thomas-Cosman frame) are unsuitable for infants and for children requiring general anaesthesia [30, 31]. Devices such as the Laitinen stereoadapter have been widely used for adults but the effect of this tight device on the pliable infant skull is uncertain and errors have been reported as large as 3.75 mm [32, 33]. Even the Boston children's frame, which uses customised occipital and chin moulds to successfully deliver SRS to high doses using a small number of fractions, is not advocated for single-shot SRS because of associated errors as large as several millimetres [34].

What is needed for effective SRS for children is therefore almost precisely what the CyberKnife has to offer: a frameless delivery system with accuracy approaching that of frame-based SRS [35, 36]. This theory

¹ Baylor Radiosurgery Center
Baylor University Medical Center
Dallas, USA

² Department of Pediatrics
University of Texas Southwestern Medical Center at Dallas
Dallas, USA

has been translated to practice, the feasibility of CyberKnife SRS for infants has been proven [37] and the initial clinical experience in a group of paediatric patients with brain tumours has been reported [38].

Patient selection

Appropriate selection of children for SRS is similar to the selection process for adults. The tumour must have a focal component amenable to SRS targeting and must not be so large that effective doses are prevented. The longevity and overall performance status of the patient should be assessed as should any reasonable expectations of treatment efficacy or failure.

We believe that the special characteristics of paediatric illness require that SRS decisions be made in the context of a paediatric tumor board consisting of a full complement of paediatric specialists: including paediatric oncologists, neurosurgeons, radiation oncologists, pathologists, neurologists and social workers. The advantage of this approach is that all the nuances of treatment peculiar to the paediatric patient can be considered at once, including aspects of pathology and clinical response particular to children. Moreover, such groups are often the only access to paediatric clinical trials and the best access to the specific social and psychological support so essential to the family of a child with a brain tumour. Given the complexity of paediatric patients and the variety of treatment options available in a children's hospital, the overall goal should be to incorporate SRS as part of a comprehensive treatment strategy rather than as a stand-alone tool.

Parents and consent

The discussion and consent process for SRS should be modelled on that for conventional surgery, including frank discussions with the parents or guardians and an explanation to the patient that is appropriate for age and sensitive to the child's ability to understand these serious issues. The risk of radiation induced malignancy is particularly relevant for young patients and should be included in the adult portion of the informed consent. 'Kid friendly' touches such as children's books and posters, music, toys and a receptive staff are appreciated tremendously by patients and even more by parents.

Anaesthesia

The delivery of CyberKnife SRS to an older child is virtually identical to that for an adult, but there are important differences when the patient is an infant or young child. Because rigid head fixation is not required for CyberKnife SRS, most adults are quite comfortable during the procedure and general anaesthesia is not needed. The same is true for older children and occasionally for a young child. We have seen completely uneventful treatments without anaesthesia for children as young as five years old. However, even the superb

tracking abilities of the CyberKnife system are no match for a squalling infant, therefore general anaesthesia should be available for babies and younger children. Anaesthesia adds to the risk and complexity of the procedure and must be thoroughly discussed with the parents as part of the consent process.

Because most SRS suites are relatively far from the surgical areas of the hospital, it is important to carefully plan how the patient will be transported. Some centres induce anaesthesia in a remote area, transport the patient to the CyberKnife suite, and bring the patient back to the anaesthesia department for recovery after treatment. Other centres induce anaesthesia in the CyberKnife suite with the patient recovering elsewhere. In either case, the transportation route and the roles of each member of the team must be rehearsed to avoid accidents.

Other anaesthetic issues are also relevant for children. Some arise because the anaesthesiologist cannot remain with the patient during treatment. These include the need to carefully monitor the temperature of these small patients within the relatively cold SRS vault, to monitor physiological variables during treatment by using a videocamera or a direct link, and to establish a protocol for rapid access to the patient if this is needed during treatment. Another anaesthesia issue is that of hyperventilation and diuresis. We prefer that physiological variables such as end tidal CO₂ and volume be kept as constant as possible during imaging and treatment. This is to ensure that the brain does not move in a way that would corrupt the stereotactic targeting.

Anaesthesia for paediatric SRS poses unique problems for neurologically ill young patients: remote access during the procedure and the necessity for transportation. We also believe that it is a task best suited for anaesthesiologists with paediatric skills and credentials.

Immobilisation

Immobilisation during imaging and treatment for older children is identical to that for adults in which a custom-made mask immobilises the head and neck. For children requiring general anaesthesia, the mask can be made to accommodate the endotracheal tube without compromising immobilisation [37]. However, problems arise for younger children because their heads are large in comparison to their bodies. This means that flexibility can defeat a head mask alone. We have found that effective immobilisation can be achieved in these cases by using a VacLok bag to immobilise the body and attaching it to the mask and a supporting Timo headrest (Figure 1) [37].

Imaging and tracking

The CT images which are used for treatment and the MR images which are used for tumour evaluation should be obtained with contrast even if intravenous access is technically difficult. For young children with small heads and subtle anatomy, we have found the use of thin sections and image fusion to be helpful. Attenuation of

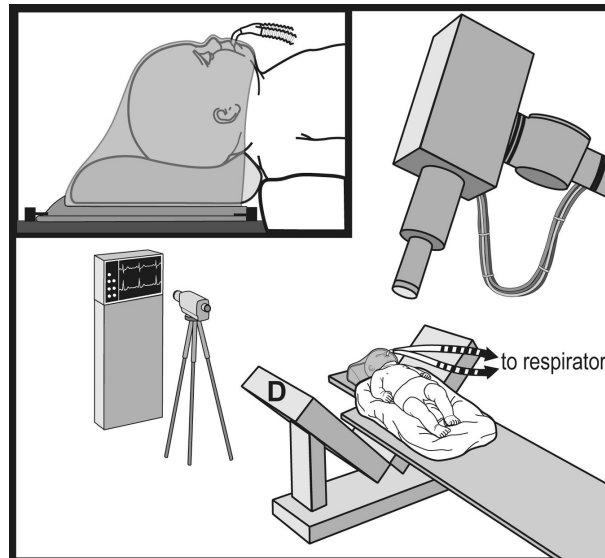


Figure 1. Schematic drawing of the CyberKnife SRS method for infants. In some cases a face mask is used (*top left inset*). **D** denotes the X-ray detector. (This figure and portions of Figures 2, 3 and 4 are used with permission and appear in Giller CA et al. Feasibility of radiosurgery for malignant brain tumors in infants: preliminary report. *Neurosurgery* 2004; 55: 916-925)

the kilovoltage used to obtain the treatment radiographs and CT scans for planning may be necessary to track the thin skulls of younger patients.

Dose magnitude

Although many centres have found that the radiation doses accepted for adult radiosurgery are also appropriate for older children [7-14] there are only a few reports on doses for single-shot SRS for infants and younger children. During our early experiences, we reduced our doses from those suitable for adults by about 25% because of the lack of guidance in the literature and concern about the fragility of the young brain. Then, because of a poor response observed in several of our patients treated with these doses, and also encouraged by a low rate of radiation necrosis [37, 38], we became more aggressive so that our current strategies are similar to those for adult radiosurgery.

This philosophy is in agreement with that of Smyth et al [39] who believe that their relatively low rate of success for the treatment of arteriovenous malformations (AVMs) was due to conservative dose prescriptions and with Tanaka et al [40] who reported better results in children than in adults with AVMs when using similar doses. Based on this admittedly anecdotal experience we consider that the paediatric brain is only slightly more susceptible to radiation induced oedema and necrosis than the adult brain.

Hypofractionation

Brain tumours of childhood are often large and frequently located in the posterior fossa or other sensitive areas such as those adjacent to the optic apparatus. Moreover, many children referred for SRS have already received and failed conventional radiotherapy. Because these factors increase

the risk of radiation induced injury when single-shot SRS is chosen, we frequently consider a hypofractionated regimen in which the dose is delivered over several days instead of all at once. Nevertheless, the theory that the use of SRS with a small number of fractions will retain the efficacy of single-shot SRS and at the same time enjoy the safety of conventional fractionation although appealing is unproven and the optimal parameters of hypofractionation (total and daily dose) are unclear.

During our early experience, our hypofractionation regimens were conservative (for example, a total dose of 15 Gy delivered in five daily fractions), but encouraged by a lack of radionecrosis and motivated by tumour recurrence, we now use a regimen of 20-25 Gy delivered in 4-5 daily fractions. Such a hypofractionated regimen was used in eight of our 38 treatments (21%) without any difficulties related to the need for daily anaesthesia [38]. We believe that hypofractionated regimens made available by the frameless CyberKnife SRS technique will continue to be useful clinical tools.

Patient population

A total of 38 radiosurgical treatments were delivered to 21 paediatric patients (8/21 male and 13/21 female) with ages ranging from 8 months to 16 years with a mean age of 7.0 years and a median age of 6.0 years at the time of their first CyberKnife SRS treatment (Table I). There were three patients with pilocytic astrocytomas, two with anaplastic astrocytomas, three with ependymomas (two anaplastic), four with medulloblastomas, one with a primitive neuroectodermal tumour (PNET), three with craniopharyngiomas, three with atypical teratoid-rhabdoid tumors, one with a pineoblastoma and one with a meningioma. Also, 10/21 had previously received external beam radiotherapy to the regions ultimately treated with SRS. The mean time lapse between radiotherapy and

SRS was 2.6 years \pm 2.2 years. Chemotherapy had been administered to 16/21, 20/21 had received resective surgery, and 12/21 had undergone two or more surgical procedures. In addition, 14/21 had been treated for residual tumour following surgery and 4/21 had been treated for recurrent tumour.

Table I. Age distribution of our 21 patients treated using CyberKnife SRS at the University of Texas Southwestern Medical Center in Dallas [37, 28]

Age range (years)	Number of patients
≤ 3	6
4-6	6
7-9	2
10-12	3
13-16	4

SRS treatment characteristics

The mean number of treatments per patient was 1.8 (range 1-7) with 7/21 receiving more than one SRS treatment and 6/21 receiving SRS to more than one lesion. The mean target volume was 10.7 cm³ (range 0.06-103 cm³), the mean number of paths was 2.4 and the mean number of beams 127. The mean dose at the margin was 18.8 Gy (range 9.2-50 Gy and median of 17 Gy) and the mean marginal isodose line was 57% (range 35-90% and median of 60%). A total of 27/38 of

the SRS treatments were delivered using a single dose and 8/38 using 3-5 fractions. The three patients with craniopharyngiomas were treated with a conventional fractionation schedule.

Results

Our most recent results are given in Table II. The mean follow-up period is 18 months (range 1-40 months). For the 15/21 patients still alive, the mean follow-up is 21 months (range 1-40 months). The time between the initial CyberKnife SRS treatment and death for the 6/21 patients who died, was 10 months (range 6-16 months).

There were no deaths or complications related to the procedures, although there was 29% (6/21) mortality during the periods of currently available follow-up. Symptomatic radionecrosis was seen in only one patient who had been heavily treated for a recurrent atypical teratoid-rhabdoid tumour. Asymptomatic radionecrosis was noted in a further two patients.

As an example case history, a one-year old boy suffered a posterior fossa haemorrhage and a biopsy obtained during evacuation showed a low grade glioma. It was elected to observe him but the tumour grew six months later, and a second biopsy demonstrated anaplastic astrocytoma. Because the tumour involved the cranial nerves and invaded the brainstem, aggressive debulking was deferred and the patient was referred for SRS. With the exception of hearing loss on the right, he was neurologically intact. Chemotherapy was given consisting of BCNU, thalidomide, imatinib meslate and temozolamide. The tumour was treated with 19 Gy

Table II. Results by tumour type as a function of tumour regression and survival

Tumour type	Result
Pilocytic astrocytoma	Tumour regression was seen in two of three patients after 26 months and tumour stability in the third after one month without any change in neurological status.
Anaplastic astrocytoma	Tumour regression without neurological change was achieved in one of these patients after 19 months (Figure 2). Asymptomatic radionecrosis with tumour regression was observed in the second patient.
Ependymoma	Tumour recurrence was seen in the first patient before he was lost to follow-up. The other two patients died due to tumour progression at six and seven months post-treatment.
Medulloblastoma	Two of these patients with discrete lesions are stable at 25 and seven months post-treatment. The third child (Figure 3) had a complete response initially but a small recurrent nodule was treated 11 months after the initial treatment. The fourth child died 16 months post-treatment.
PNET	The child with a PNET died of diffuse recurrence at nine months post-treatment.
Craniopharyngioma	Tumour regression without visual changes was achieved in all three patients at 29, 39 and 40 months post-treatment.
Rhabdoid tumour	The right cerebellar nodule treated in the first of these patients is stable 28 months following treatment, but treatment of a left cerebellar nodule resulted in symptomatic radionecrosis. The patient is improving and the MRI changes are resolving (Figure 4 illustrates this dramatic result). Asymptomatic radionecrosis with tumor regression developed in the second patient whose PET scan did not show hypermetabolic activity. The third patient died seven months post-treatment from tumour progression.
Pineoblastoma	The patient died 14 months post-treatment due to distant tumour progression.
Meckel's cave meningioma	The patient showed progression 12 months post-treatment. The tumour bed was retreated following surgical resection because similar tumours in her spine had recurred with resection alone.

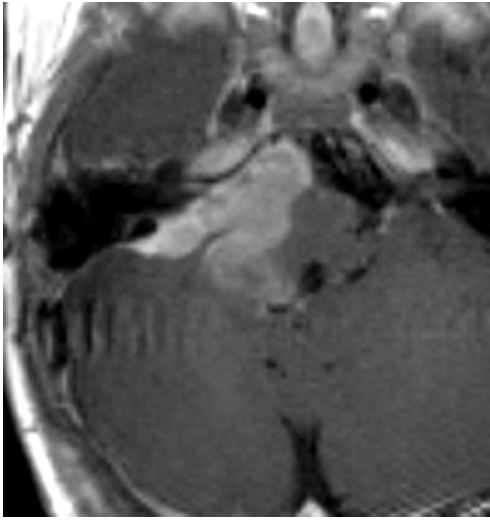


Figure 2a

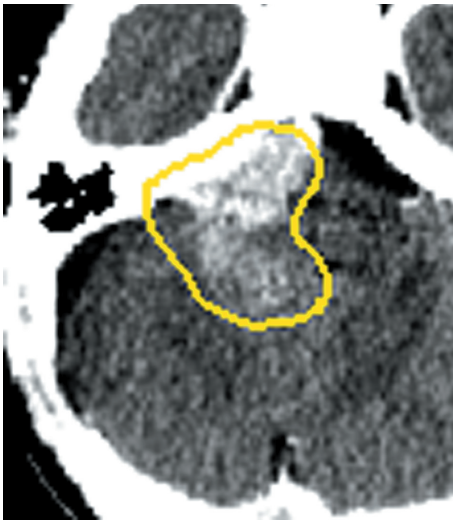


Figure 2b

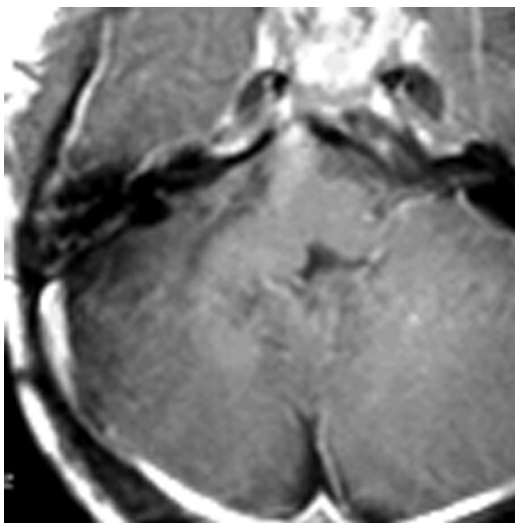


Figure 2c

Figure 2. (a) Enhanced axial image of an 18-month old boy with anaplastic astrocytoma: before radiosurgery. (b) Enhanced axial CT image CyberKnife SRS treatment plan for patient showing the 55% isodose line. (c) Enhanced axial MR image of same patient three years post-treatment after 19 Gy delivered to the 55% isodose line in five fractions

delivered in five daily fractions (3.8 Gy *per day*) to the 55% isodose line (Figure 2). An MRI scan three years after treatment showed a decrease in tumor size, and the patient remained neurologically unchanged.

As a second example case history, a seven-month old girl underwent an occipital craniotomy for resection of a posterior fossa medulloblastoma. Post-operative MRI showed residual enhancement believed to be tumour. She received chemotherapy consisting of cisplatin, cyclophosphamide, etoposide and vincristine. She was then treated with a hypofractionated regimen consisting of 20 Gy delivered in five fractions of 4 Gy prescribed to the 55% isodose line (Figure 3). Five months later, the patient was neurologically unchanged and MRI scanning showed that the tumour was smaller.

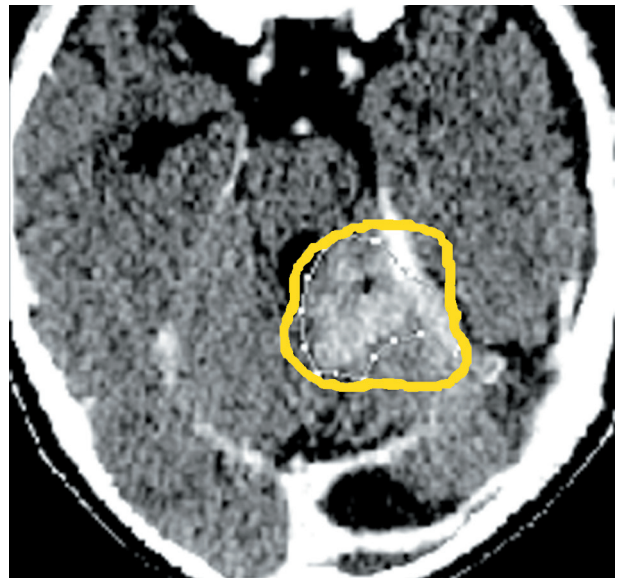


Figure 3a

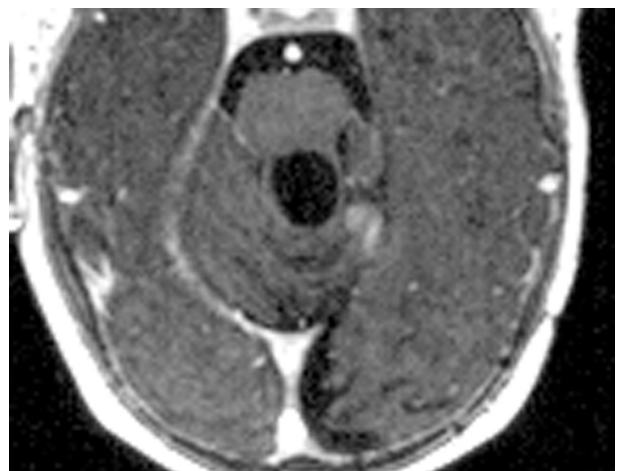


Figure 3b

Figure 3. (a) Enhanced axial CT image of a seven-month old girl with medulloblastoma before SRS showing the 55% isodose line. (b) Enhanced axial MR image of the patient five months post-treatment after 20 Gy delivered to the 55% isodose line in five fractions

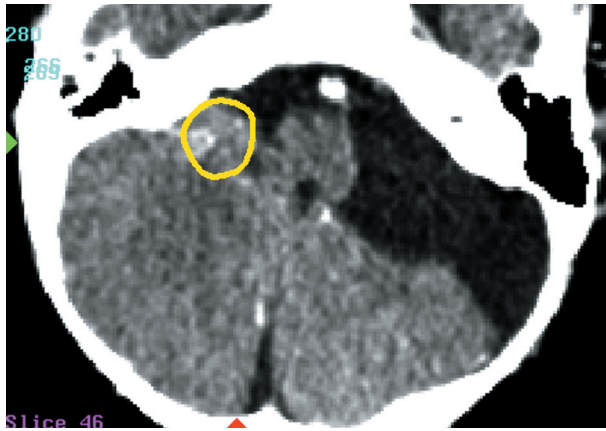


Figure 4a

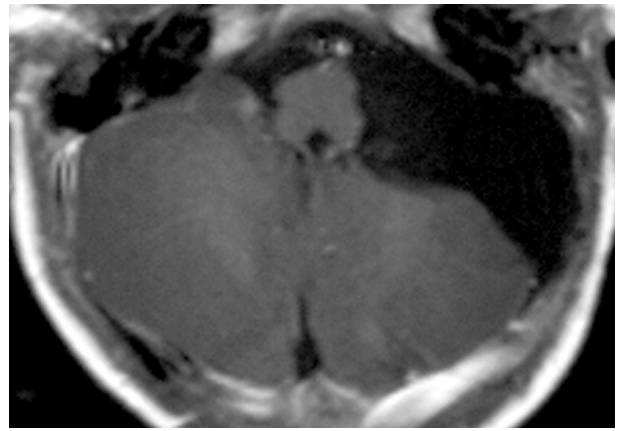


Figure 4b

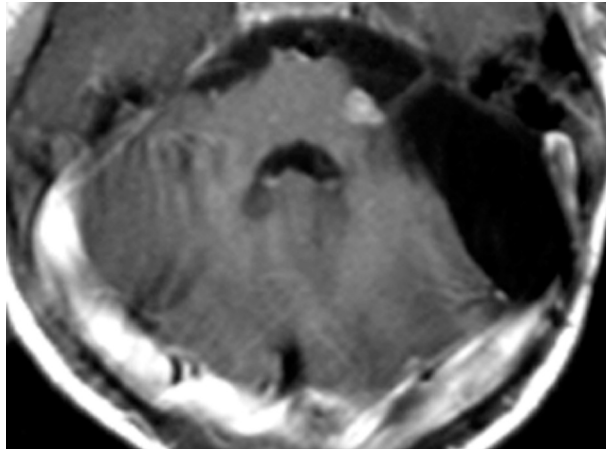


Figure 4c

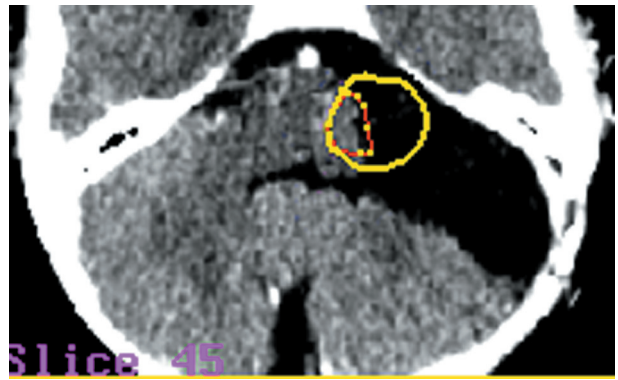


Figure 4d

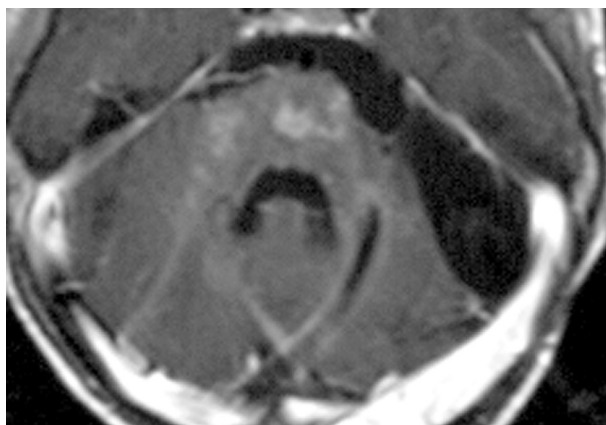


Figure 4e

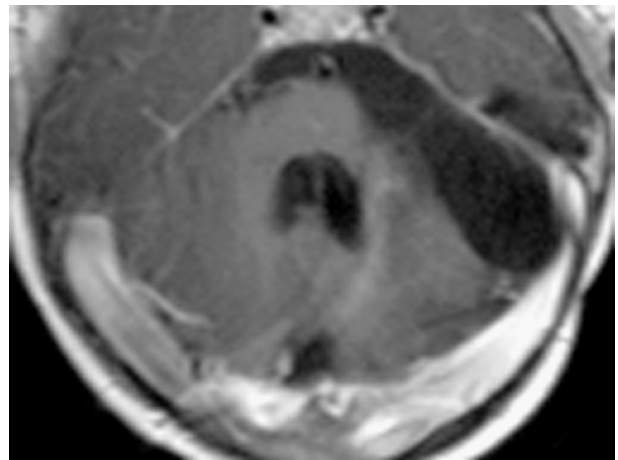


Figure 4f

Figure 4. (a) Enhanced axial CT image of a nine-month old girl with a residual nodule following resection of an atypical teratoid-rhabdoid tumor. The nodule had progressed in size following resection. The 65% isodose line is shown. (b) Enhanced axial MR image four months post-treatment with chemotherapy and 16.5 Gy prescribed to the 65% isodose line in one fraction. The nodule is smaller. (c) Enhanced axial MR image 19 months after SRS showing development of a contralateral nodule. (d) Enhanced axial CT image showing the second treatment plan to treat the resection bed (after resection of the contralateral nodule) with 24 Gy prescribed to the 60% isodose line (shown as the yellow curve) in four fractions. (e) Enhanced axial MR image showing diffuse enhancement in the brain stem seven months after the second SRS treatment. The patient was sent for hospice care. (f) Enhanced axial MR image showing resolution of enhancement 13 months after the second SRS. The clinical symptoms had markedly improved

Discussion

It is difficult to draw conclusions regarding the response rates for individual tumour types because of the very small size of each of our patient groups. Nevertheless, tumour responses were observed in each group. For

example, the patients with pilocytic astrocytoma and anaplastic astrocytoma responded well to radiosurgery. Our results were mixed for medulloblastoma, with two patients responding well and two showing tumor progression. Long-term control was achieved in all three patients with craniopharyngioma, although our fractio-

nation schedule in these cases is better described as stereotactic radiotherapy (SRT) than SRS [41, 42].

Our experience with rhabdoid tumours suggests that aggressive radiosurgical treatment can contribute to tumour control, but it is still too early to say whether the results are durable. The three patients with ependymoma all experienced poor results. This is in agreement with other reports [15]. Finally, the failure of radiosurgery in our patients with PNET and pineoblastoma is further testimony that SRS treatment is ineffective against diffuse disease.

These results should be viewed in light of the aggressive nature of the treated tumours. A total of 20/21 patients had a surgical resection in their course, with 12/21 having had more than one resection. Also, 16/21 had received chemotherapy and 10/21 conventional radiotherapy, whereas 3/21 had previously received Gamma Knife SRS.

In terms of radiation doses, because the tumours in our population were aggressive and because many of our patients were referred after failure of other modalities, our dose schedules tended to be aggressive. This can be seen in our mean dose of almost 19 Gy and our use of single-shot SRS regimens in 71% (27/38) of the treatment plans.

The only toxicity seen was in the four children who developed radionecrosis and who received deliberately aggressive treatment plans because of otherwise dismal prognosis. Because rhabdoid tumours are notoriously aggressive [43] the first of these patients was initially treated with both resection and chemotherapy, and radiotherapy was withheld because of her young age. Although a residual cerebellar nodule is stable 28 months following SRS, she developed symptomatic radionecrosis in the region of a second contralateral nodule that had been treated with resection and a second SRS. However, 11 months later both the symptoms and radiological findings are resolving (Figure 4). Our second patient with a rhabdoid tumour was also treated with an aggressive dose, resulting in asymptomatic biopsy proven radionecrosis 11 months after his initial treatment. He has also received chemotherapy and underwent two surgical resections.

One of our patients with an anaplastic astrocytoma had developed a local recurrence after three surgical resections, radiotherapy, a Gamma Knife SRS treatment and chemotherapy. The most recent follow-up results, 18 months after his initial CyberKnife SRS demonstrated that he is clinically stable, but has developed asymptomatic radionecrosis.

An anaplastic ependymoma patient also failed locally after five surgical resections, radiotherapy, Gamma Knife SRS and chemotherapy. He remained stable with radiological findings of radionecrosis, but has unfortunately been lost to follow-up after 10 months.

Finally, use of the CyberKnife allowed avoidance of anaesthesia in 8/21 patients. Rather surprisingly, patients as young as five years old did not require anaesthesia.

Conclusions

The advantages of CyberKnife SRS for the paediatric population include the ability to treat infants and younger children. The increased comfort of a frameless system, permits the opportunity to offer hypofractionated regimens and a reduced requirement for general anaesthesia. These advantages are particularly important for children because of the malignant nature of their tumours and the frequency of settings better suited for hypofractionation than single-shot SRS. The feasibility of CyberKnife SRS in infants has been proven, preliminary reports in a relatively large population have been reported, and we believe that CyberKnife SRS will become an invaluable tool for the treatment of these serious tumours in young patients.

Cole A. Giller MD, PhD

Baylor Radiosurgery Center
Baylor University Medical Center
3500 Gaston Avenue
Hobblitzelle 1
Dallas, TX 75246
USA

References

- Duffner PK, Horowitz ME, Krischer JP et al. Postoperative chemotherapy and delayed radiation in children less than three years of age with malignant brain tumors. *N Engl J Med* 1993; 328: 1725-31.
- Ries LAG, Smith MA, Gurney JG et al. (eds.). *Cancer incidence and survival among children and adolescents*. United States SEER program 1975-1995, National Cancer Institute. NIH pub No 99-4649. Bethesda: National Institutes of Health, 1999.
- Hoppe-Hirsch E, Brunet L, Laroussinie F et al. Intellectual outcome in children with malignant tumors of the posterior fossa: influence of the field of irradiation and quality of surgery. *Child's Nerv Syst* 1995; 11: 340-6.
- Inoue HK, Kohga H, Nakamura M et al. Long-term follow-up study of conventional irradiation for brain tumours in children: a role for radiosurgery. *Acta Neurochir* 1994; 62 suppl: 83-8.
- Mostow EN, Byrne J, Connelly RR et al. Quality of long-term survivors of CNS tumors of childhood and adolescence. *J Clin Oncol* 1991; 9: 592-9.
- Walter AW, Mulhern RK, Gajjar A et al. Survival and neurodevelopmental outcome of young children with medulloblastoma at St. Jude Children's Research Hospital. *J Clin Oncol* 1999; 17: 3720-8.
- Baumann GS, Wara WM, Larson DA et al. Gamma Knife radiosurgery in children. *Pediatr Neurosurg* 1996; 24: 193-201.
- Colombo F, Benedetti A, Casentini L et al. Stereotactic radiosurgery of intracranial tumors in children. *J Neurosurg Sci* 1985; 29: 233-7.
- Eder HG, Leber KA, Eustacchio S et al. The role of Gamma Knife radiosurgery in children. *Child's Nerv Syst* 2001; 17: 341-6.
- Gerszten PC, Adelson PD, Kondziolka D et al. Seizure outcome in children treated for arteriovenous malformations using Gamma Knife radiosurgery. *Pediatr Neurosurg* 1996; 24:139-44.
- Grabb, PA, Lunsford LD, Albright AL et al. Stereotactic radiosurgery for glial neoplasms of childhood. *Neurosurgery* 1996; 38: 696-702.
- Hodgson DC, Goumnerova LC, Loeffler JS et al. Radiosurgery in the management of pediatric brain tumors. *Int J Radiat Oncol Biol Phys* 2001; 50: 929-35.
- Kondziolka D, Lunsford LD, Flickinger JC. Stereotactic radiosurgery in children and adolescents. *Pediatr Neurosurg* 1990-1991; 16: 219-21.
- Somaza SC, Kondziolka D, Lunsford LD et al. Early outcomes after stereotactic radiosurgery for growing pilocytic astrocytomas in children. *Pediatr Neurosurg* 1996; 25: 109-115.

15. Aggarwal R, Yeung D, Kumar P et al. Efficacy and feasibility of stereotactic radiosurgery in the primary management of unfavorable pediatric ependymoma. *Radiother Oncol* 1997; 43: 269-73.
16. Benk V, Clark BG, Souhami L et al. Stereotactic radiation in primary brain tumors in children and adults *Pediatr Neurosurg* 1999; 31: 59-64.
17. Dunbar SF, Tarbell NJ, Kooy HM et al. Stereotactic radiotherapy for pediatric and adult brain tumors: preliminary report. *Int J Radiat Oncol Biol Phys* 1994; 30: 531-9.
18. Freeman CR, Souhami L, Caron JL et al. Stereotactic external beam irradiation in previously untreated brain tumors in children and adolescents. *Med Pediatr Oncol* 1994; 22: 173-80.
19. Hirth A, Pedersen P-H, Baardsen R et al. Gamma Knife radiosurgery in pediatric cerebral and skull base tumors. *Med Pediatr Oncol* 2003; 40: 99-103.
20. Jawahar A, Kondziolka D, Flickinger JC et al. Adjuvant stereotactic radiosurgery for anaplastic ependymoma. *Stereotact Funct Neurosurg* 1999; 73: 23-30.
21. Levy EI, Niranjan A, Thompson TP et al. Radiosurgery for childhood intracranial arteriovenous malformations. *Neurosurgery* 2000; 47: 834-41.
22. Loeffler JS, Rossitch E, Siddon R et al. Role of stereotactic radiosurgery with a linear accelerator in treatment of intracranial arteriovenous malformations and tumors in children. *Pediatrics* 1990; 85: 774-82.
23. Patrice S, Tarbell NJ, Goumnerova LC et al. Results of radiosurgery in the management of recurrent and residual medulloblastoma. *Pediatr Neurosurg* 1995; 22: 197-203.
24. Raco A, Raimondi AJ, D'Alonzo A et al. Radiosurgery in the management of pediatric brain tumors. *Child's Nerv Syst* 2000; 16: 287-95.
25. Suh JH, Barnett GH. Stereotactic radiosurgery for brain tumors in pediatric patients. *Technol Cancer Res Treat* 2003; 2: 141-6.
26. Weprin BE, Hall WA, Cho KH et al. Stereotactic radiosurgery in pediatric patients. *Pediatr Neurol* 1996; 15: 193-9.
27. Zissiadis Y, Dutton S, Kieran M et al. Stereotactic radiotherapy for pediatric intracranial germ cell tumors. *Int J Radiat Oncol Biol Phys* 2001; 51: 108-12.
28. Baker KC, Isert PR. Anaesthetic considerations for children undergoing stereotactic radiosurgery. *Anaesth Intens Care* 1997; 25: 691-5.
29. Stokes MA, Soriano SG, Tarbell NJ et al. Anesthesia for stereotactic radiosurgery in children. *J Neurosurg Anesthesiol* 1995; 7: 100-8.
30. Greitz T, Bergstrom M, Boethius J et al. Head fixation system for integration of radiodiagnostic and therapeutic procedures. *Neuroradiology* 1980; 19: 1-6.
31. Kingsley DPE, Bergstrom M, Berggren BM. A critical evaluation of two methods of head fixation. *Neuroradiology* 1980; 19: 7-12.
32. Hariz MI. Clinical study on the accuracy of the Laitinen CT-guidance system in functional stereotactic neurosurgery. *Stereotact Funct Neurosurg* 1991; 56: 109-28.
33. Hariz MI, Henriksson R, Lofroth PO et al. A non-invasive method for fractionated stereotactic irradiation of brain tumors with linear accelerator. *Radiother Oncol* 1990; 17: 57-72.
34. Kooy HM, Dunbar SF, Tarbell NJ et al. Adaptation and verification of the relocatable Gill-Thomas-Cosman frame in stereotactic radiotherapy. *Int J Radiat Oncol Biol Phys* 1994; 30: 685-91.
35. Adler JR, Murphy MJ, Chang SD et al. Image-guided robotic radiosurgery. *Neurosurgery* 1999; 44: 1299-1307.
36. Chang SD, Main W, Martin DP et al. An analysis of the accuracy of the CyberKnife: a robotic frameless stereotactic radiosurgical system. *Neurosurgery* 2003; 52: 140-147.
37. Giller CA, Berger B, Gilio JP et al. Feasibility of radiosurgery for malignant brain tumors in infants using image-guided robotic radiosurgery: preliminary report. *Neurosurgery* 2004; 55: 916-25.
38. Giller CA, Berger BD, Pistenmaa DA et al. Robotically guided radiosurgery for children. *Pediatr Blood Cancer* 2005; 44: 1-7.
39. Smyth MD, Sneed PK, Ciricillo SF et al. Stereotactic radiosurgery for pediatric intracranial arteriovenous malformations: the University of California at San Francisco experience. *J Neurosurg* 2002; 97: 48-55.
40. Tanaka T, Kobayashi T, Kida Y et al. Comparison between adult and pediatric arteriovenous malformations treated by Gamma Knife radiosurgery. *Stereotact Funct Neurosurg* 1996; 66 suppl 1: 288-95.
41. Kalapurakal JA, Kepka A, Bista T et al. Fractionated stereotactic radiotherapy for pediatric brain tumors: the Chicago children's experience. *Child's Nerv Syst* 2000; 16: 296-300.
42. Saran FH, Baumert BG, Khoo VS et al. Stereotactically guided conformal radiotherapy for progressive low-grade gliomas of childhood. *Int J Radiat Oncol Biol Phys* 2002; 53: 43-51.
43. Packer RJ, Biegel JA, Blaney S et al. Atypical teratoid-rhabdoid tumor of the central nervous system: report on workshop. *J Pediatr Hematol Oncol* 2002; 24: 337-42.