

## Clear cell carcinoma of the uterine cervix in a 16-year old patient – a case report

Piotr Sobiczewski<sup>1</sup>, Mariusz Bidziński<sup>1</sup>, Anna Nasierowska-Guttmejer<sup>2</sup>, Alicja Ceran<sup>3</sup>

*We report a case of clear cell carcinoma of the uterine cervix not related to DES (diethylstilboestrol) exposure in a 16-year old patient. USG and MRI imaging were useful in excluding parametrial infiltration and assessing the stage of disease. Combined modality treatment consisted of Wertheim-Meigs operation followed by adjuvant HDR (high-dose-rate) brachytherapy to the vaginal vault.*

### Jasnokomórkowy rak szyjki macicy u 16-letniej chorej - opis przypadku

*Przedstawiono przypadek raka jasnokomórkowego szyjki macicy u 16-letniej chorej, nie związany z ekspozycją na DES (diethylstilboestrol). Badania obrazowe (USG i NMR) pozwoliły wykluczyć naciekanie przymacic i okazały się przydatne w ustaleniu stopnia zaawansowania. Leczenie skojarzone polegało na operacji Wertheima-Meigsa i brachyterapii pochwowej (HDR).*

**Key words:** clear cell carcinoma, uterine cervix, Wertheim-Meigs operation, brachytherapy

**Słowa kluczowe:** rak jasnokomórkowy, szyjka macicy, operacja Wertheima-Meigsa, brachyterapia

### Introduction

Some 7 to 15 % of cervical cancers are adenocarcinomas and their incidence has recently increased with reference to squamous cell carcinoma [1, 2]. The higher rate of clear cell carcinoma has been observed in girls and young women exposed *in utero* to hormonal treatment with diethylstilbestrol (DES). The age of the patients with clear cell carcinoma induced by DES ranged from 15 to 25 years, unlike the age of patients with spontaneous tumors (unrelated to DES exposure) in which the disease typically occurs at an older age (50-80 years) [1, 3].

### Case report

A 16-year old patient was admitted to the pediatric department of a local hospital on the 28-th of February 2002 with the symptoms of anemia, general weakness, palpitation and hair loss. Total blood cell count revealed low erythrocyte level (RBC  $3.97 \times 10^{12}/L$ ). Laboratory test showed decreased iron (Fe) level of 63mg% and hemoglobin (Hb) 7.8 g/dl. The medical history noted

polymenorrhea and hypermenorrhea occurring for 2 years. Gynecological examination revealed a mass of hemorrhagic appearance extending in the 1/3 upper part of the vagina.

A biopsy of the tumor revealed clear cell carcinoma of high-grade (G3).

Ultrasonographic examination and consultation in the Gynecologic Department of the Medical Academy in Warsaw confirmed the diagnosis of uterine cervical tumor. The patient was given packed red blood cells due to the low hemoglobin level and was referred to the Department of Gynecological Oncology of the Maria Skłodowska-Curie Memorial Cancer Center for further evaluation and treatment. Gynecological examination confirmed the presence of an exophytic cervical lesion 4 cm in diameter. Rectovaginal examination did not reveal parametrial induration. The parametrium thickness measured by transvaginal echography was 11mm on the right side and 9 mm on the left side, without any signs of neoplastic infiltration. Evaluation of the pelvis with NMR imaging showed a cervical tumor 45 x 48 mm and also excluded parametrial invasion (Figures 1, 2). Eventually, the tumor was clinically diagnosed as FIGO stage I b and the patient was scheduled for surgery. On the 25<sup>th</sup> of March 2002 radical hysterectomy, bilateral salpingo-oophorectomy and pelvic lymphadenectomy (the Wertheim-Meigs operation) was performed. Postoperative recovery was uncomplicated and the patient was discharged after 8 days.

<sup>1</sup> Department of Gynaecological Oncology

<sup>2</sup> Department of Pathology  
The Maria Skłodowska-Curie Memorial Cancer Center  
and Institute of Oncology  
Warsaw, Poland

<sup>3</sup> The Institute of Mother and Child  
Warsaw, Poland

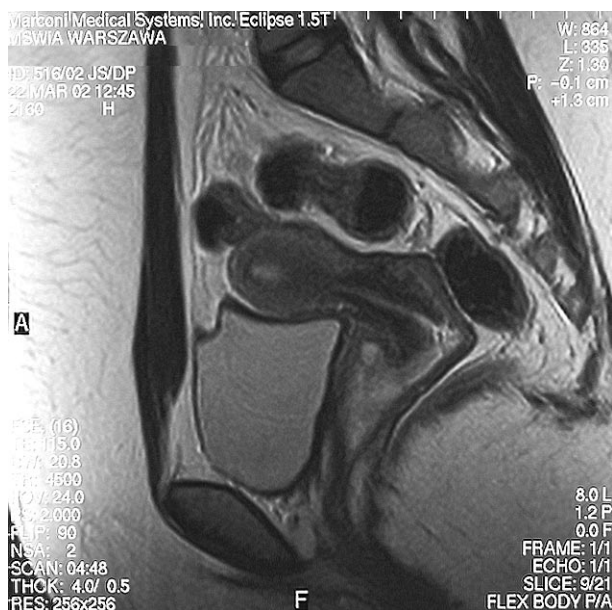

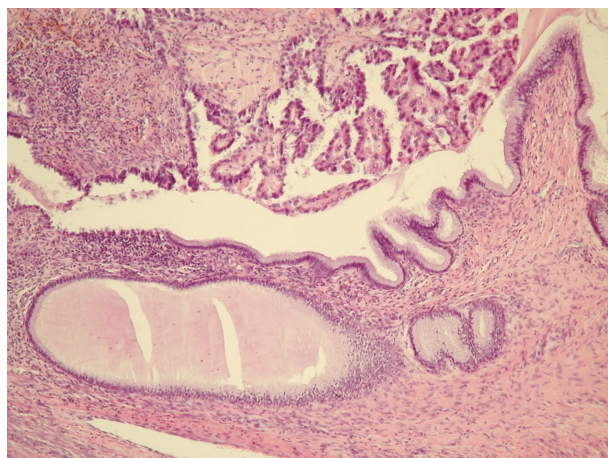
Figure 1

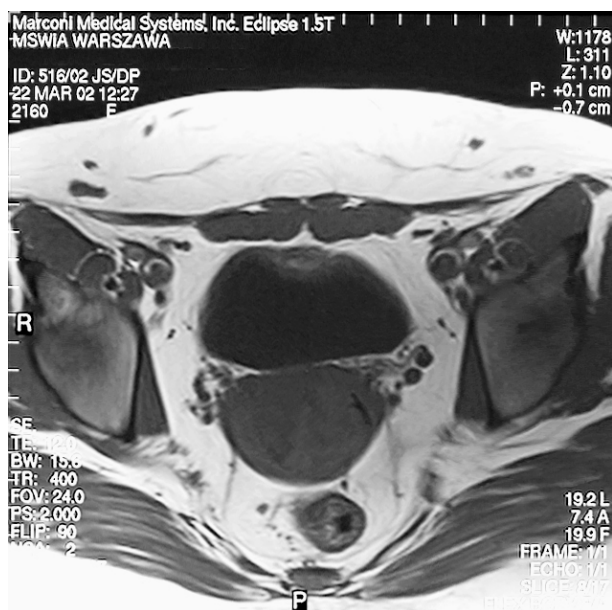

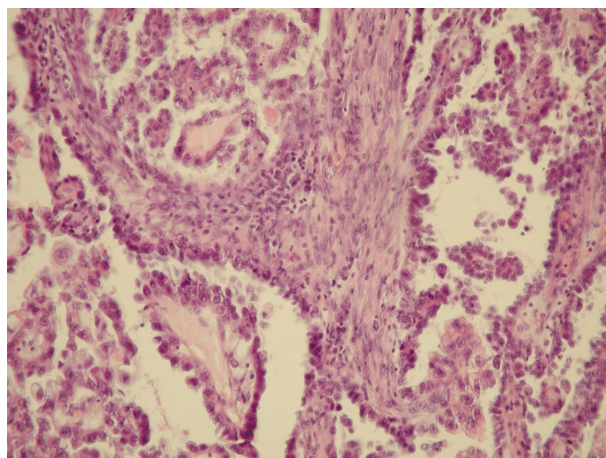
Figure 2

**Figures 1, 2.** NMR imaging: sagittal and axial T1 and T2 - weighted images were obtained and showed the cervical tumor with no parametrial invasion

The uterus with parametrial margins, both adnexas and 21 pelvic lymph nodes was sent for pathologic examination. An exophytic tumor (45 mm x 45 mm x 35 mm) of papillary pattern was found on the vaginal portion of uterine cervix. Macroscopically on cross-section, the tumor was creamy, solid and dense. Microscopic examination confirmed the initial diagnosis of clear cell adenocarcinoma of the uterine cervix (Figure 3). Cystic structures with papillary proliferation (Figure 4) and focally columnar cells were found on histopathological examination. The dark nuclei were located in the base part of epithelial cells. The representative sections were routinely stained by H&E. In 20% of cells a bright colored cytoplasm and in 80% a rose colored cytoplasm was found. The mucus staining in cells was negative. The tumor infiltration did not exceed 1/2 of the cervix diameter. The parametrial tissue and all lymphnodes were negative for carcinoma.



**Figure 3.** H&E x 100 Clear cell carcinoma infiltrating cervical canal



**Figure 4.** H&E x 200 The cystic structures with papillary proliferation

From the 19-th of April to the 17-th of May 2002 adjuvant intracavitary brachytherapy consisting of 3 repeated applications of 7,5 Gy by HDR remote afterloading technique on vaginal vault was applied. The patient remains under close follow-up and has no symptoms of recurrence to date.

## Discussion

Clear cell adenocarcinoma of the uterine cervix and vagina was rare until the 1970s, when a significant increase in incidence in young patients between 8 and 29 years of age has been noticed. The growing number of cases was associated with the teratogenic effect of DES on *in utero* exposed female fetus. DES was widely prescribed to pregnant women as a preventive therapy against abortion in the late 1940s, especially in the USA. Data from the Registry for Research on Hormonal Trans-placental Carcinogenesis in the USA based on 170 cases

of cervical and vaginal carcinoma highly suggested that 87% of cases of vaginal cancer and 68% of cases of cervical cancer of clear cell type were related to the intake of hormonal treatment by mothers during the first and second trimester of pregnancy (during the first 18 weeks in all cases) [3]. The estimated risk of developing a clear cell carcinoma of vagina or cervix was 0.14 to 1.4 in 1000 women exposed *in utero* to DES. The most common symptoms were irregular bleedings and vaginal discharges. Subsequent analysis of the Registry in 1979 based on 384 cases have confirmed the epidemiological data and allowed to draw new conclusions. Overall 5-year survival rate was 78% and was higher in the group of patients aged 19 years and older (83%), as compared to patients 14 years and less (71%). Worse outcome in young patients was probably related to the solid pattern of the tumor more common in this age group [3, 4]. Furthermore, the Registry data has shown better prognosis in patients with DES-induced cancer than in the group with spontaneous clear cell carcinoma (5 year survival 84% versus 69%) [4, 5]. The highest incidence of the clear cell carcinoma was observed in the group of patients born from 1951 to 1953.

Until January 1999, 705 cases of clear cell carcinoma of the uterine cervix and vagina have been registered, mostly in the United States. Exposure to DES was reported for 60 % of cases, in 30% patients the neoplasm was non related to hormonal exposure and in 10% of cases the history was unobtainable or investigation incomplete [5]. Clear cell carcinomas not related to DES account for 2-6 % of adenocarcinomas of the uterine cervix and the 10-year survival rate for the patients with all stages is about 57%, and is similar to other cervical adenocarcinomas [7]. The recommended treatment is surgery with adjuvant radiotherapy. Different pathogenic factors were considered as affecting the development of clear cell carcinoma, mostly hormonal but also genetic.

The data from the Central Netherlands Registry indicated the bimodal age distribution with two distinct peaks: one at young age (a mean age of 26 years) and one at older age (a mean age of 71 year) [6]. In the Netherlands study this bimodal age distribution was still present even if the DES-exposed women were excluded. This observation, not reported previously, supports the hypothesis that risk factors other than DES exposure may play an important role in carcinogenesis [6]. It may suggest that there exists a risk period after menarche and menopause related to hormonal changes or to population with constitutional sensitivity for carcinogenesis [6]. A case report available in literature concerned a 17-year old patient with pathological genotype 46XX/47XX, mental retardation and non-DES-related clear cell carcinoma of the vagina. Successful treatment with chemotherapy (CAP) was applied resulting in complete remission. Pathological genotype and genetic aberration may lie beneath the development of clear cell carcinoma [8]. Etiopathogenesis may be complex and in DES-related cancers, the hormonal factor may act as cocarcinogene

and facilitate, along with others factors, the malignant transformation of the epithelium.

Our demonstrated case is casuistic due to the lack of DES exposure and should be classified as spontaneous, rarely occurring in young women. Radical surgery with adjuvant brachytherapy is the recommended treatment in this type of cancer. Preoperative imaging (USG, NMR) may be useful for precise assessment of the stage of the disease, which is crucial for the choice of the appropriate treatment.

**Piotr Sobiczewski MD, PhD**

Department of Gynaecological Oncology  
The Maria Skłodowska-Curie Memorial Cancer Center  
and Institute of Oncology  
Roentgena 5, 02-781 Warsaw  
e-mail: sobiczewski@coi.waw.pl

## References

1. Crum CP, Nuovo G. The cervix. In: Sternberg SS (ed.). *Diagnostic Surgical Pathology* New York: Raven Press, Vol 2, 1989: 1579-1580
2. Bidziński M, Sobiczewski P. *Adenocarcinoma of the cervix in stage Ib - analysis of the 40 cases*. Abstract book of 9<sup>th</sup> International Meeting of Gynecological Oncology ESGO 9, Knokke, Belgium, 1995, 36.
3. Herbst AL, Robboy SJ, Scully RE. Clear cell adenocarcinoma of the vagina and cervix in girls: analysis of 170 registry case. *Am J Obstet Gynecol* 1974; 19: 713-24.
4. Herbst AL, Cole P, Norusis WR et al. Epidemiologic aspects and factors related to survival in 384 Registry cases of clear cell adenocarcinoma of the vagina and cervix *Am J Obstet Gynecol* 1979; 135: 876-886.
5. Herbst AL. Behaviour of estrogen associated female genital tract cancer and its relation to neoplasia following intrauterine exposure to Diethylstilbestrol (DES) *Gynec Oncol* 2000; 76: 147-56.
6. Hanselaar A, van Loosbroek M, Schuurbiens et al. Clear cell adenocarcinoma of the vagina and cervix. An update of Central Netherland Registry showing twin age incidence peaks. *Cancer* 1997; 79: 2229-36.
7. Kaminski PF, Maier RC. Clear cell adenocarcinoma of the cervix unrelated to Diethylstilbestrol exposure *Obstet Gynecol* 1983; 62: 720-727.
8. Tanaka H, Tabata T, Yanase H et al. Clear cell adenocarcinoma of the vagina in young female, treated by combination chemotherapy (local and systemic chemotherapy) complicated with chromosomal abnormality *Gynecol Oncol* 1994; 55: 259-64.

*Paper received: 16 March 2003*

*Accepted: 10 May 2003*