

Malassezia furfur sepsis in a cancer patient

Elżbieta Ochman, Barbara Podsiadło, Hanna Połowniak-Pracka,
Elżbieta Hagmajer, Piotr Sowiński

We present the case of a patient with cancer of the cardia treated surgically at The Maria Skłodowska-Curie Memorial Cancer Centre and Institute of Oncology in Warsaw. Surgery comprised total gastrectomy, resection of the inferior part of oesophagus, the spleen and neighbouring lymph nodes and removal of the serosa covering the transverse mesocolon and the pancreas. Beginning with postoperative day 3 numerous, consecutive complications were observed, necessitating two re-operations. The patient's emaciation related to both the primary disease, and to surgery, required parenteral nutrition and lipid supplementation. In the course of treatment we observed bacterial infection and Malassezia furfur fungemia. Fungal cultures were performed in the BACTEC 9050 system (Becton-Dickinson). In direct culture preparations of the Bactec Mycosis IC/F medium, we observed clusters of yeast cells, some budding. The fungi failed to grow after 48hrs of incubation in the Sabouraud and in 5% sheep blood agar media. We obtained microscopic colonies resembling the growth of bacteria after as long as 5 days of fungal culture in the Sabouraud medium. Since the yeast cells observed in direct cultures morphologically resembled fungi of the Malassezia genus, at the same time the culture was inoculated on the Sabouraud medium supplemented with sterile olive oil with a small addition of Tween 80. After 48 hrs of incubation, we observed the growth of multiple yeast colonies. They were identified according to the key as Malassezia furfur. Initial treatment consisted of eliminating lipids from parenteral nutrition and the administration of fluconazole.

Posocznica wywołana przez *Malassezia furfur* u chorego z nowotworem

Przedstawiono przypadek chorego z rakiem wpustu, leczonego chirurgicznie w Centrum Onkologii w Warszawie. Zabieg chirurgiczny obejmował całkowite wycięcie żołądka z dolnym odcinkiem przelyku, usunięcie śledziony, regionalnych węzłów chłonnych, usunięcie błony surowiczej, pokrywającej krezkę poprzecznicy i trzustkę. W 3 dobie doszło do licznych, następujących po sobie, komplikacji, w wyniku czego pacjent był dwukrotnie reoperowany. Związane z chorobą zasadniczą wyniszczenie organizmu pacjenta oraz osłabienie zabiegami chirurgicznymi wymagało zastosowania żywienia pozajelitowego i suplementacji tłuszczowej. W wyniku komplikacji pooperacyjnych pojawiły się zakażenia bakteryjne oraz fungemia, wywołana przez Malassezia furfur. Hodowlę grzyba uzyskano w systemie BACTEC 9050 firmy Becton-Dickinson. W preparatach bezpośrednich z hodowli na podłożu Bactec Mycosis IC/F stwierdzono zlepy komórek drożdżopodobnych, z których nieliczne pączkowały. Grzyby nie wyrastały po 48 godzinach inkubacji na podłożach: Sabourauda i agarze z 5% krwi baraniej. Dopiero po 5 dniach hodowli uzyskano wzrost grzybów na podłożu Sabourauda, w postaci mikroskopijnych kolonii przypominających wzrost bakterii. Ponieważ komórki grzybów drożdżopodobnych, widoczne w preparatach bezpośrednich z hodowli, pod względem morfologicznym przypominały grzyby z rodzaju Malassezia, równocześnie wykonano posiew na podłożu Sabourauda, pokryte warstwą sterylnej oliwy z oliwek z niewielkim dodatkiem Tween 80. Po 48 godzinach inkubacji uzyskano wzrost licznych kolonii drożdżaków, które w oparciu o klucz zidentyfikowano jako gatunek Malassezia furfur. Pierwszym elementem leczenia była eliminacja substancji tłuszczowych z żywienia pozajelitowego oraz włączenie flukonazolu.

Key words: *Malassezia furfur*, fungemia, parenteral nutrition

Słowa kluczowe: *Malassezia furfur*, fungemia, żywienie pozajelitowe

Yeasts of the *Malassezia* genus (synonym: *Pityrosporum*) are saprotrophs of the healthy skin in people and animals [1, 2]. They usually inhabit areas in the vicinity of sebaceous glands as they need fatty substances to grow (lipophilic organisms) [1]. The *Malassezia* genus comprises such species as *M. furfur* (*Pityrosporum ovale*, *P. orbiculare*), *M. pachydermatis* and recently isolated: *M. obtusa*, *M. restricta*, *M. slooffiae*, *M. globosa* [3, 4]. These organisms can also cause superficial mycosis and, in some cases, systemic mycosis [5-8]. The best-known species is *M. furfur*. It may cause *pityriasis versicolor* with mildly exfoliating, discoloured or pigmented patches on the skin, folliculitis or seborrhoea [9]. In immunocompromised patients, emaciated adults and infants with low birth weight, who receive parenteral nutrition with lipids [3, 9, 8], *M. furfur* and *M. pachydermatis* [10] can cause fungemia. It is manifested by fever which does not subside after broad-spectrum antibiotics, interstitial pneumonia, thrombocytopenia and heart damage. Sometimes one may observe fungal clots surrounding the catheter tip and/or pericardial excrescence of fungal mass [11]. The source of infection are usually fungi found on the skin which initially colonise the deep vein catheter used for parenteral nutrition and are then transferred to bloodstream [8, 12, 13]. They can also be transferred on the hands of medical staff, and their source may be the skin of pets (cats, dogs) [6]. In this work we present a case of fungemia caused by fungi of the *Malassezia furfur* species – the first such report in Polish medical literature – in a patient receiving parenteral lipid supplementation.

Case Report

A 45-year-old man with cancer of the cardia was qualified for primary surgical treatment at The Maria Skłodowska-Curie Memorial Cancer Centre and Institute of Oncology in Warsaw.

On admission the patient presented with weight loss (about 5 kg over the previous 3 months) and dysphagia – stage II acc. to the WHO scale. Additional tests showed the traits of mild protein-energy malnutrition.

In the preoperative period, two units of blood were collected for autotransfusion, a central line was inserted through the right internal jugular vein and parenteral nutrition (amino-acids, carbohydrates, lipids) was administered for 7 days without any complications. The supply of non-protein calories in the form of carbohydrates and lipids was set at 1600 kcal/d. Lipids were withdrawn 24 hours before surgery.

Surgery consisted of total gastrectomy, resection of the inferior part of oesophagus, the spleen and neighbouring lymph nodes and removal of the serosa covering the transverse mesocolon and of the pancreas. The continuity of alimentary tract was reconstructed with the intestinal interposition of the first loop of the jejunum; in the posterior lower mediastinum the oesophageal stump was anastomosed with the antimesenteric side of the intestine; the distal end of the intestinal interposition was anastomosed with the duodenal stump; the continuity of

jejunum was reconstructed; a nutritional jejunostomy tube, chest drainage, a nasogastric tube in the stomach and a Penrose drain were placed.

The operation was performed by left thoracotomy in the oblique position, with general endotracheal and continuous epidural anaesthesia. At the chest stage of surgery, ventilation was maintained with the exclusion of the left lung. The course of surgery and anaesthesia was uneventful.

After the operation the patient was admitted to the Intensive Care Unit (ICU) in good general condition. During the postoperative period, beginning with the third postoperative day, there occurred numerous, consecutive complications: perforation of the large intestine, peritonitis and an anastomotic leak, followed by dehiscence of the anastomosis of the oesophageal stump with the intestine in the posterior lower mediastinum causing, in turn, mediastinitis, pyothorax, small intestinal fistula, sepsis and multi organ failure (respiratory failure with the Acute Respiratory Distress Syndrome – ARDS, circulatory collapse, kidney and liver failure, disseminated intravascular coagulation – DIC and gastrointestinal bleeding).

During his stay in the ICU the patient was re-operated twice, required mechanical lung ventilation and respiratory assistance for 24 days (on day 7 after endotracheal intubation tracheostomy was performed); for many days, due to the symptoms of circulatory failure, intravenous catecholamines (dopamine, dobutamine, noradrenaline) were administered. Due to coagulation abnormalities the patient required the administration heparin, antithrombin and trascolan, as indicated by laboratory results. He also received numerous transfusions of blood derivatives (packed red blood cells, packed platelets, fresh frozen plasma).

Because the patient had prolonged infection caused by mixed, variable gram-positive and gram-negative flora, continual antibiotic treatment was conducted for several weeks, based on the results of cultures obtained systematically from many sites (bronchoalveolar lavage – BAL, abdominal cavity, pleural cavity, urine, drain swabs and nasopharyngeal cavity).

Systematic change of tracheotomy tubes, central catheters, urethral catheters and drains was performed. The patient also received constant antifungal treatment with fluconazole. Antibiotic treatment and infection monitoring was conducted in close cooperation with the Department of Microbiology of the Institute of Oncology.

On the first day total gastrectomy, nutritional treatment was introduced and continued until the return of normal functions of alimentary tract. The supply of proteins ranged from 1.5 to 2.0 g/kg/d (nitrogen 0.24 to 0.32 g/kg/d), the supply of calories ranged from 35 to 40 kcal/kg/d. Electrolytes, trace elements and vitamins were also administered. Total parenteral nutrition was administered, periodically introducing enteral nutrition with enteral diets through a preoperatively placed jejunostomy tube. However, due to the fistula of the small

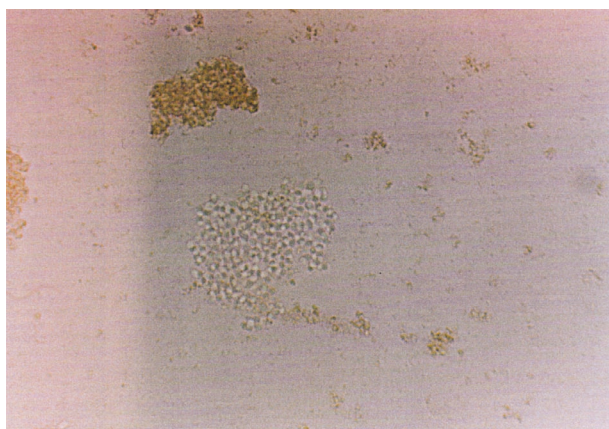


Figure 1. Direct blood culture preparation in Bactec-Mycosis liquid medium

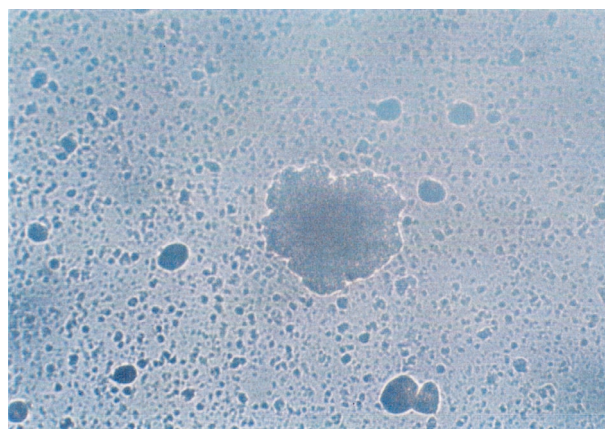


Figure 2. Colonies cultured in the Sabouraud agar after 5 days in 30° C /×30 magnification/

intestine, enteral nutrition was limited to 200 – 750 ml/day.

Lipid emulsions were administered in parenteral nutrition as a source of calories independent of glucose, they also provided the necessary unsaturated fatty acids (Unsaturated fatty acids deficiency causes dermatitis, postpones wound healing, increases platelet aggregation, facilitates thyroid dysfunction, haemolytic anaemia and neutropenia).

The administered lipid emulsions contained a mixture of medium chain triglycerides (MCT) and long chain triglycerides (LCT) in 50%/50% ratio. Compared with traditional emulsions containing only LCT, MCT/LCT mixtures undergo faster and utilisation and elimination. They do not have such a negative impact on the immune system, they undergo faster enzymatic hydrolysis, while the increase in the level of fats and triglycerides in blood serum is less frequent with MCT/LCT emulsions, as compared to LCT-only emulsions.

After approximately 8 weeks of parenteral nutrition, the serum level of triglycerides started to rise, and when it exceeded the upper limit by more than 50% for three consecutive days, the lipid emulsions were withdrawn. After approximately 10 weeks of ICU stay incl. the administration of broad-spectrum antibiotics and parenteral nutrition, *Malassezia furfur* was isolated from the patient's blood. Since, at that time, there were symptoms of liver and kidney failure and the level of triglycerides was still increased over the optimal level, it was decided to exclude lipid emulsions from nutrition. This was the first stage of treatment of the *Malassezia furfur* infection, introduced before the administration of antifungal drugs which cause kidney and liver toxicity. Lipid emulsion withdrawal lasted for 13 days until it was confirmed that no fungi cultures could be isolated from the patient's blood.

Laboratory diagnostics

A positive culture was obtained from blood in the BACTEC 9050 system by Becton-Dickinson on the BACTEC Mycosis IC/F medium. Direct culture pre-

parations revealed large clusters of yeast cells, of which only few budded (Figure 1). No fungal growth was obtained (in the subculture from the original culture) after 48 hours of incubation in the Sabouraud medium (incubation at 30° C) and blood agar (37° C). It was only after 5 days of observation that microscopic colonies resembling bacterial colonies (Figure 2) began to grow in the Sabouraud agar. Since the yeast cells observed in direct culture preparations morphologically resembled fungi of the *Malassezia* genus, at the same time a culture was inoculated on the Sabouraud medium supplemented with a layer of olive oil with a small addition of Tween 80. The olive oil with Tween was autoclaved. It was put on the surface of the agar with a swab and meticulously spread, rubbing the fat into the medium (1% oil can also be added to a chosen medium before its sterilisation). In these cultures (37° C) after 48 hours, the growth of multiple colonies of yeast was observed (Figure 3). They were identified according to the key [4] as *Malassezia furfur*. The attending physician was notified of the detection of lipophilic fungi in blood cultures.

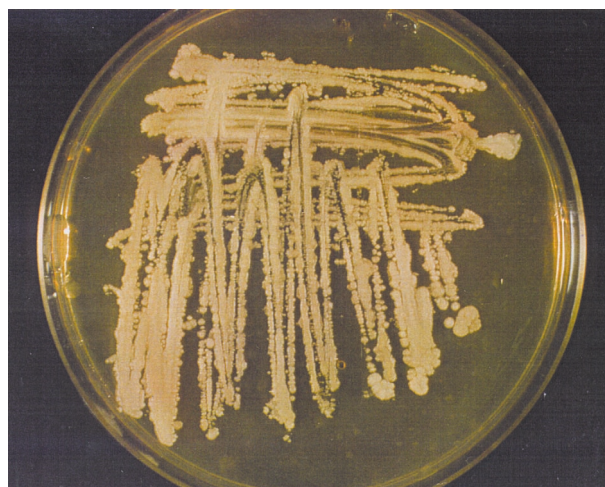

Figure 3. Culture after 48-hour incubation in 37° C in the Sabouraud medium supplemented with olive oil

Fungus characteristics

In the media containing olive oil the fungus grows after 48 h of incubation at 32-37° C as buttery, cream or yellowish colonies (Figure 3). In direct culture preparation we can observe the presence of oval, sometimes elongated cells, with unipolar budding, producing no pseudohyphae (Figure 4). The fungus does not ferment any sugars. *M. furfur* can also be cultured in other media: Mycosel – Becton-Dickinson, Microbiotic agar – Difco, LitmanOxgal agar – Difco with 1% addition of olive oil.

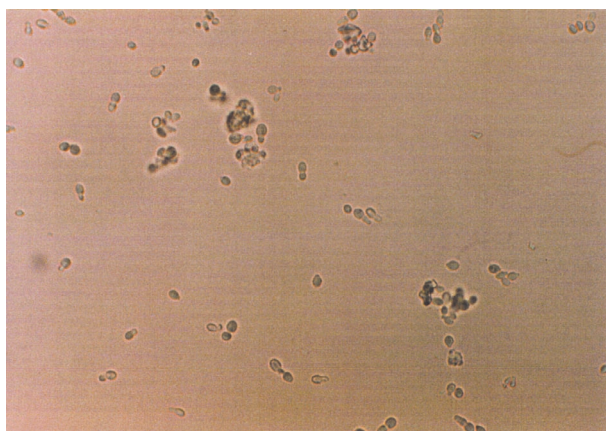


Figure 4. Direct preparation after 48-hour culture in 37° C in the Sabouraud medium supplemented with olive oil (×400 magnification)

Discussion

The presence of primary disease and the usually poor general condition of the patient often make it difficult to detect the etiological factor behind the infection. The patient described here, was emaciated in the course of the primary disease (cancer) and weakened by serious surgical procedures, necessitating the supplementation of parenteral nutrition with lipid substances.

Parenteral administration of lipid supplementation creates good conditions for the growth of *Malassezia furfur* inhabiting the skin. The growing number of the organisms can initially lead to colonisation of the catheter, and then enter blood circulation causing fungemia. The basis for diagnosis is obtaining the growth of fungi in blood cultures obtained from the catheter and/or cultures from catheter tip, after its removal. In peripheral blood these organisms are present in small amounts, which reduces the chances of obtaining positive cultures. In the case under discussion the fungi grew in only one culture. Before obtaining the positive culture, two cultures had been made with negative results. In the blood specimen collected from the catheter one detects the presence of small amounts of lipids, therefore the growth of fungi from such material requires long incubation. In the case under discussion a positive result was obtained after ten days. For culture confirmation and identification of yeast obtained from a liquid medium it is necessary to grow

the fungi in a solid medium. The Sabouraud agar is routinely used for this procedure. This medium does not contain lipid substances, so a lipophilic fungus will either grow in such environment after a long period of incubation or it will not grow at all. Therefore, in cases such as this, where, despite the positive culture result and the occurrence of fungus in direct preparation in liquid medium, it is impossible to confirm the result and isolate the etiological factor in solid medium by the use of routine methods, we must consider fungi with specific substrate requirements (lipophilia) and use a medium supplemented with sterilised olive oil or containing oil with Tween 80. This is especially important in cases when an intravenous catheter is present and lipid substances are being administered. If this is taken under account it will significantly speed up the identification of the fungus and increase the chances for patient survival. It is also important to immediately remove the catheter from the vein and perform cultures from its tip. For epidemiological reasons in immunocompromised patients it is important to pay attention to dermatitis, caused by yeast and other fungi, which must be treated, as it may be a potential source of infection and the cause of systemic mycosis.

Conclusions

1. In case of fever not subsiding after antibiotic treatment or lung trouble of unknown etiology, in emaciated patients receiving parenteral lipid supplementation, it is necessary to consider the possibility of fungemia caused by lipophilic fungi (*M. furfur*, *M. pachydermatis* or other species of this kind).
2. Detection of the occurrence of yeasts in direct preparations of blood cultures and lack of growth in routine media for fungus cultures indicates the necessity to inoculate the cultures onto media supplemented with olive oil.
3. The referral to perform a blood culture or a catheter tip culture should contain information whether the patient receives lipid substances in the course of parenteral nutrition. This will aid the adequate direction of the testing and will substantially speed up isolation of the etiological factor and the introduction of adequate treatment.

Elżbieta Ochman M.Sc.

Department of Microbiology
The Maria Skłodowska-Curie Memorial Cancer Center
and Institute of Oncology
Roentgena 5, 02-781 Warsaw
Poland

References

1. Leeming JP, Notman FH. Improved methods for isolation and enumeration of *Malassezia furfur* from human skin. *J Clin Mikrobiol* 1987; 25: 2017-9.
2. Schmidt A. *Malassezia furfur*: a fungus belonging to the physiological skin flora and its relevance in skin disorders. *Cutis* 1997; 59: 21-4.
3. Aspiroz C, Moreno L, Rezusta A et al. Differentiation of three *Malassezia* species on human normal skin: correspondence with *M.globosa*, *M.sympodialis* and *M.restricta*. *Mycopathologia* 1999; 145: 69-74.
4. Barnett JA, Payne RW, Yarrow D. *Yeasts: characteristics and identification*. Cambridge: University Press; 2000.
5. Azimi PH, Levernier K, Lefrak LM et al. *Malassezia furfur*: a cause of occlusion of percutaneous central venous catheters in infants in the intensive care nursery. *Pediatr Infect Dis J* 1988; 7: 100-3.
6. Chang HJ, Miller HL, Watkins N et al. An epidemic of *Malassezia pachydermatis* in an intensive care nursery associated with colonization of health care workers pet dogs. *N Engl J Med* 1998; 12: 706-11.
7. Denkner WM, Spector SA, Fierer J et al. *Malassezia* fungemia in neonates and adults: complication of hyperalimentation. *Rev Infect Dis* 1987; 9: 743-53.
8. Long JG, Keyserling HL. Catheter – related infection in infants due to an unusual lipophilic yeast – *Malassezia furfur*. *Pediatrics* 1985; 76: 896-900.
9. Gueho E, Boekhout T, Ashbee HR et al. The role of *Malassezia* species in the ecology of human skin and as a pathogenes. *Med Mycol* 1998; 36 (Suppl 1): 220-9.
10. Gueho ER, Simmons R, Pruitt W et al. Ahearn. Association of *Malassezia pachydermatis* with systemic infections of humans. *J Clin Mikrobiol* 1987; 25: 1789-90.
11. Richet HM, Mc Neil MH, Edwards MC et al. Cluster of *Malassezia furfur* pulmonary infection in a neonatal intensive unit. *J Clin Microbiol* 1989; 27: 1197-1200.
12. Marcon MJ, Powell DA. Human infections due to *Malassezia* spp. *Clin Microbiol Rev* 1992; 5:101-19.
13. Surmount I, Gavilanes A, Vandepitte J et al. *Malassezia furfur* fungemia in infants receiving intravenous lipid emulsion; a rarity or just underestimated? *Eur J Pediatr* 1989; 148: 435-8.

Paper received: 4 August 2003

Accepted: 21 October 2003