

## Brain stem tumors in children – therapeutic results in patients of the University Children’s Hospital of Cracow in Poland

Elżbieta Korab-Chrzanowska<sup>1</sup>, Stanisław Kwiatkowski<sup>2</sup>,  
Joanna Bartoszevska<sup>1</sup>

*Aim.* To analyse the treatment results achieved in children treated for brain stem tumours at one institution between the years 1990 and 2004.

*Material.* 20 patients (10 girls, 10 boys) aged 2.8-15.6 years were treated for brain stem tumors at the University Children’s Hospital of Cracow (UCHC) in the years 1990-2004.

The tumour type was defined basing on imaging studies (CT, MRI), and, in the case of 7 patients, additionally basing on histopathological results. In the collected material the predominant tumor type was benign glioma, detected in 17 patients. Malignant gliomas were diagnosed in 3 children.

*Method.* 7 children were treated by radiotherapy only. Surgical procedures and adjuvant radiotherapy were employed in 3 patients. 6 children underwent radiotherapy and chemotherapy. Combined surgical treatment followed by radiotherapy and chemotherapy was employed in 4 patients.

*Results.* Of the 20 patients 6 have died (30%). The surviving group (70%) includes 1 patient with tumor progression (5%), 5 – with stable tumors (25%), and 8 (40%) – with tumor regression. The probability of three-year overall survival for the entire group as calculated by the Kaplan-Meier method was 70% while the probability of three-year progression-free survival was 65%.

*Conclusions.* Diffuse brain stem tumors, mostly those involving the pons, and malignant gliomas have poor prognosis. In the presented material we achieved the best treatment results in patients with exophytic or focal tumors, treated surgically with adjuvant therapy.

### Guzy pnia mózgu u dzieci – wyniki leczenia w materiale Uniwersyteckiego Szpitala Dziecięcego w Krakowie

*Wprowadzenie.* 20 pacjentów (10 dziewczynek i 10 chłopców) w wieku 2,8-15,6 lat z nowotworami pnia mózgu było leczonych w Uniwersyteckim Szpitalu Dziecięcym (USD) w Krakowie w latach 1990-2004.

*Cel pracy.* Ocena wyników leczenia dzieci z nowotworami pnia mózgu w materiale USD.

*Material.* Na podstawie badań obrazowych (KT, NMR), a u 7 pacjentów dodatkowo w oparciu o badanie histopatologiczne, określono typ nowotworu. W materiale własnym przeważały guzy o charakterze gwałtownego: u 17 pacjentów. Gwałtowne złośliwe zdiagnozowano u 3 dzieci.

*Metoda.* Samą radioterapię leczono 7 dzieci. Chirurgię z następową radioterapią zastosowano u 3 pacjentów. Radioterapię z chemioterapią stosowano u 6 dzieci. Skojarzonemu leczeniu operacyjnemu z następową radio- i chemioterapią poddano 4 pacjentów.

*Wyniki.* Z 20 pacjentów leczonych w Uniwersyteckim Szpitalu Dziecięcym w Krakowie w latach 1990-2004 z powodu guzów pnia mózgu, 6 zmarło (30%), a 14 pacjentów żyje (70%), w tym 1 z progresją choroby (5%), 5 ze stabilizacją (25%) oraz 8 z regresją guza (40%). Prawdopodobieństwo przeżycia 3 letniego całkowitego oraz 3 letniego bez progresji choroby oceniono na podstawie krzywych przeżyć Kaplana-Meiera; wyniosło ono dla przeżyć całkowitych 70%, a dla przeżyć bez progresji choroby 65%.

<sup>1</sup> Division of Radiotherapy  
University Children’s Hospital of Cracow  
Cracow, Poland

<sup>2</sup> Neurosurgical Ward, Department of Pediatric Surgery,  
Chair of Pediatric Neurosurgery  
University Children’s Hospital of Cracow, Poland

*Wnioski. Rozlane guzy pnia, głównie mostu oraz złośliwe glejaki charakteryzuje złe rokowanie. W materiale własnym najlepsze wyniki osiągnięto u pacjentów z guzami o charakterze eozofitycznym lub ogniskowym, leczonych operacyjnie z następowym leczeniem uzupełniającym.*

**Key words:** children, brain stem tumors, treatment

**Słowa kluczowe:** dzieci, guzy pnia mózgu, leczenie

## Introduction

More than 70% of tumors situated in the brain stem – in the mesencephalon, the pons and the medulla oblongata – are encountered in patients below 20 years of age [1]. They account for 10 to 20% of brain tumors in children; in the present material this ratio reached 14% (20 patients treated in the years 1990-2004). In the United States some 150-300 cases are detected annually [1, 2]. These tumors are most common in the 7-9 years age group and show no significant difference in their distribution between both sexes. Histologically, the predominant type is glioma with varying degrees of malignancy. Other brain stem tumors include PNET, lymphomas, cavernomas and epidermal cysts [1, 3]. In neurological and neurosurgical practice we use the classification presented by Epstein. It classifies these tumors as diffuse, focal, cystic, exophytic and tumors of the craniovertebral region [4].

Clinical symptoms vary according to tumor type, location and patient age. In exophytic tumors of the fourth ventricle and the tectal lamina, the predominant symptoms include intracranial hypertension associated

with hydrocephalus. In diffuse tumors, especially involving the brain stem, the clinical symptoms develop rapidly and include balance problems, muscular hypotonia, dysmetria and cranial nerve damage. In tumors involving the medulla oblongata and the cervical segment of the medulla, the frequently encountered symptoms include persistent hiccups, recurrent infections of the upper respiratory tract, changed timbre of voice and altered way of speaking. All groups of brain stem tumors are characterized by such initial symptoms as eye movement abnormalities – divergent squint with or without double vision, abnormal accommodation and Parinaud's sign. The management of brain stem tumors includes surgery, radiotherapy and chemotherapy, or a combination of these therapeutic modalities.

## Objective

To sum up and assess the therapeutic results achieved in children with brain stem tumors managed at the University Children's Hospital of Cracow in the years 1990-2004.

**Table I. Patient and disease characteristics**

	Age	Gender	Histopathology	Tumor growth type	Therapeutic modalities	Assessment of response to therapy
A.W	6.1	M	None	diffuse	RT	P, death
K.S	6.0	M	None	diffuse	RT	CR
T.J	12.6	F	None	exophytic	RT	CR
C.G	4.7	M	None	exophytic	RT	PR
S.P	6.1	F	None	focal	RT	P, death
P.P	13.0	F	None	focal	RT	P, death
P.M	15.6	F	None	focal	RT	PR
R.N	14.1	M	a. fibrillare partim bipolare	focal	OP+RT	S
Ż.M	14.6	F	a. fibrillare partim bipolare	focal	OP+RT	S
Z.D	9.5	M	a. pilocyticum	exophytic	OP+RT	S
Ł.D	11.1	M	None	diffuse	CHT+RT	CR
W.D	13.1	F	None	exophytic	CHT+RT	PR
M.E	11.9	F	None	exophytic	CHT+RT	P, death
S.E	13.6	F	None	focal	CHT+RT	PR
M.S	13.0	M	None	focal	CHT+RT	S
F.A	4.3	M	None	focal	CHT+RT	P, death
H.T	4.8	M	a. pilocyticum	exophytic	OP+CHT+RT	S
S.Ł	13.6	M	a. pilocyticum	exophytic	OP+CHT+RT	P, death
B.K	2.8	F	a. fibrillare partim bipolare	exophytic	OP+CHT+RT	PR
R.M	8.1	F	a. fibrillare partim bipolare	exophytic	OP+CHT+RT	P

Legend: CR – complete regression, PR – partial regression, S – stabilization, P – progression

## Material

Between 1990 and 2004, 20 children aged from 2.8 to 15.6 years were treated at the University Children's Hospital of Cracow; the group was equally divided into boys and girls. Prior to treatment, all the children underwent CT scans, and 12 patients were additionally diagnosed using MRI, thus confirming the presence of a tumor in the brain stem. The tumour type was pronounced basing on the imaging studies and, in the case of the 7 surgical patients, additionally basing on histopathology. Table I presents the patient characteristics.

## Method

7 children underwent surgical treatment followed by adjuvant therapy – subsequent radiotherapy in 3 cases and radiotherapy and chemotherapy in 4 cases. Due to inoperable disease, 13 children were treated conservatively – 7 by radiotherapy alone, and 6 by radiotherapy and chemotherapy.

### Conservative treatment

Radiotherapy was employed in 7 children (age at diagnosis: 4.7-15.6 years) – 3 boys and 4 girls. Surgical intervention consisted of implanting a ventriculo-peritoneal valve and was performed in 4 children. Due to tumor location the patients did not qualify for tumor resection. Prior to treatment, all the patients presented with neurological symptoms, which depended on tumor location. Pronounced personality changes, manifested as aggression and anxiety, were observed in one child with a lesion situated in the pons. Deterioration of the clinical and the neurological status in the course of therapy was noted in one child; this phenomenon was associated with massive progression of the disease and the treatment was discontinued.

In the course of treatment, the remaining patients manifested considerable clinical and neurological improvement, including a girl, in whom disease progression occurred 4 months after the completion of therapy.

### Radiotherapy and chemotherapy

The treatment was employed in 6 patients aged between 4.3 and 13.6 years – 3 girls and 3 boys. Surgical procedures (implantation of a ventriculo-peritoneal valve) were performed in 3 children. Due to the detection of astrocytoma cells in the cerebrospinal fluid, one child was subjected to irradiation of the entire central nervous system, with an increased dose applied to the tumor site. Following preliminary chemotherapy according to the protocol established by the Polish Pediatric CNS Tumor Group, 2 children manifested massive tumor growth. Since a surgical intervention was impossible, the patients underwent radiotherapy. During the irradiation therapy, the children had already considerably improved clinically and neurologically, while CT scans showed tumor regression.

### Surgery combined with subsequent adjuvant therapy

Surgical procedures with subsequent radiotherapy were employed in 3 children – 2 boys and a girl – aged 9.5-14.6 years.

### Surgery with radiotherapy and chemotherapy

The group included 4 children aged 2.8-13.6 years (2 boys and 2 girls). In all these children partial tumor resection procedures were performed and followed by chemotherapy and radiotherapy. Two patients managed in the earlier period were treated

according to the VCR+CCNU protocol, one child was on Temodal, and one was managed according to the protocol established by the Polish Pediatric CNS Tumor Group.

## Results

Of the twenty patients treated at the University Children's Hospital of Cracow due to brain stem tumors in the period 1990-2004, 6 died (30%) and 14 survived (70%) – 1 patient with tumor progression (5%), 5 – with stabilized tumors (25%) and 8 (40%) – with tumor regression. In the latter group 5 children demonstrate partial, and 3 – complete tumor regression. Partial tumor resection procedures were performed in 7 children. Radiotherapy was employed in all 20 patients. In addition, chemotherapy was employed in 10 children. Long-term survivals (10 and 14 years) were achieved in 2 patients. These children had exophytic gliomas involving the pons and the pons and medulla oblongata, which were treated by radiotherapy alone, resulting in one total and one partial regression of the tumor, maintained for 6 years and 8 months, respectively. The latter child was subsequently operated on due to a recurrent tumor. At present, 14.5 years after treatment completion, the patient is alive and symptom-free. 3 children achieved total survival ranging from 5 to 9 years. Two of these patients had partial tumor resection, followed by adjuvant irradiation therapy. One patient with a focal glioma of the medulla oblongata is alive, with stabilized disease maintained for 5 years, another child with an exophytic glioma involving the medulla oblongata and pons was operated on after a 5-year stabilization period due to a recurrent tumor; this patient is presently (9.2 years after the initial diagnosis) alive and symptom-free.

Particularly worthy of consideration is a patient with an exophytic tumor of the mesencephalon and pons, in whom – following surgical tumor tissue collection (no neoplastic cells were demonstrated in the material) and implantation of a ventriculo-peritoneal valve – only one cycle of CCNU+VCR chemotherapy was administered. In view of the deteriorating general condition of the child, adjuvant therapy was discontinued and the patient was referred for symptomatic treatment. Over a period of two years, CT demonstrated spontaneous shrinking of the tumor mass and the child improved clinically and neurologically. After that, the disease progressed and irradiation therapy was employed, resulting in a moderate regression of the tumor as demonstrated by imaging techniques, and in view of considerable clinical improvement. After another three years, the disease progressed and the tumor was partially resected (histopathological diagnosis: astrocytoma pilocyticum). At present, 6.8 years after the onset of symptoms, the patient is alive and in a very good general condition, his disease is stabilized, which has been confirmed by imaging studies.

Survival curves for the entire group were generated by the Kaplan-Meier method. (Figures 1, 2). The length of survival was calculated from the data of diagnosis. The

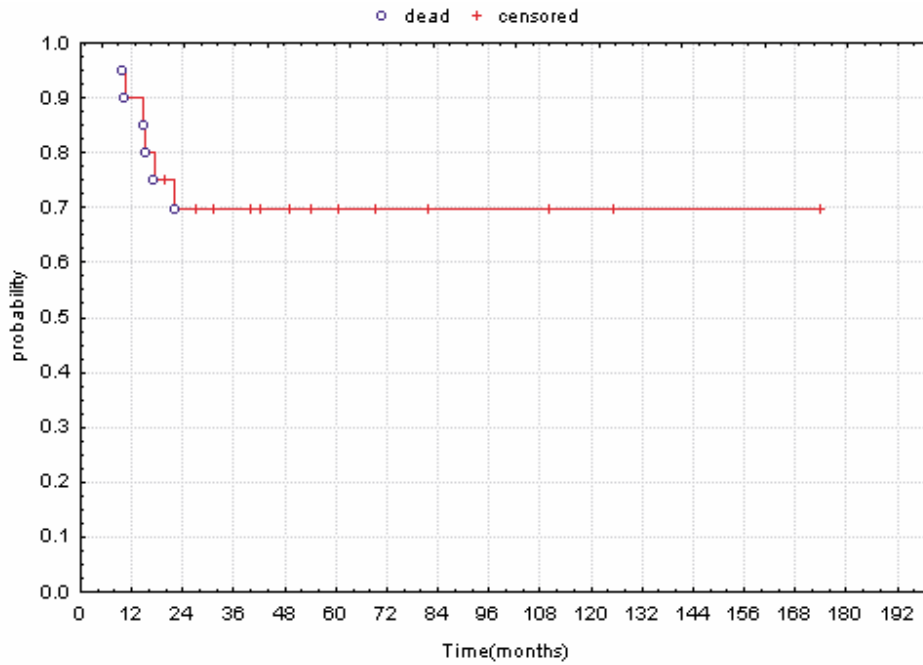
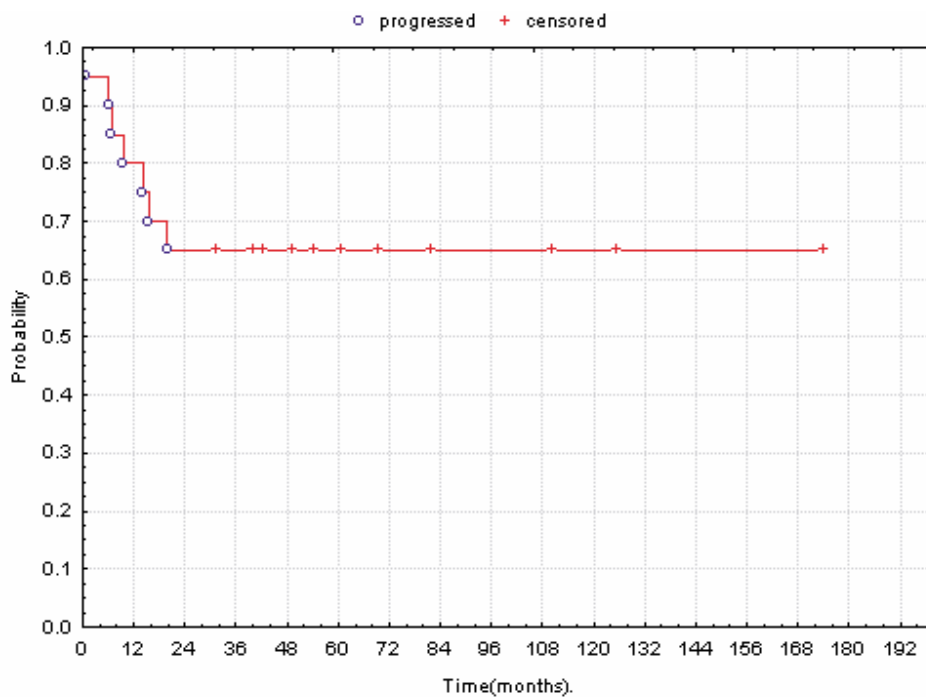


Figure 1. Kaplan-Meier overall survival analysis



Figures 2. Kaplan-Meier progression – free survival analysis

Table II. Mean total and event-free survivals in particular therapeutic groups

Number of patients	Therapeutic modalities	PFS (years)	OS (years)
13	Conservative treatment: RT and RT+CHT	3.8	3.9
7	Surgery with adjuvant treatment: OP+RT and OP+CHT+RT	4.5	4.7

Legend: PFS – progression free survival, OS – overall survival

survival length in particular therapeutic groups is demonstrated in Table II.

**Discussion**

Brain stem tumors pose a serious therapeutic problem. In spite of the development of neurosurgical techniques, often a radical or even a partial procedure is impossible to perform in the case of tumors situated in the pons or in the case of the so-called diffuse brain stem gliomas. Five-

year survival rates in this group oscillate between 10 and 30% [1]. In our material there were 4 patients with tumors located in the pons, 5 with tumors in the mesencephalon, and 6 – in the medulla oblongata. In the case of 2 children, the tumor infiltrated the pons and the medulla oblongata, in 3 – the pons and the mesencephalon.

In view of the composition of the patient group, which included children mostly with advantageous location of the tumor, our results (85% children with advantageous location) are similar to those presented in literature. As follows from numerous reports published in medical periodicals, which of necessity are scarce in view of the relatively low incidence of the disease, to date, in randomized multicenter clinical trials based on large groups of patients no effective therapeutic modality has been identified which would ensure a high percentage of event-free survival. Surgical management continues to play a leading role only in patients with exophytic tumours. Radiotherapy is also a therapeutic standard, especially for diffuse tumors. Unfortunately, investigations on the use of hyperfractionated, accelerated and hyperfractionated accelerated radiation therapy have not contributed to an improvement in the outcomes [5, 6]. Therapeutic results have also failed to improve – as may be seen from the group of 28 children subjected to brachytherapy with I-125 implants in whom the dose of 82.9 Gy was employed [7]. In adult patients with brain stem tumors, investigations concentrate on stereotactic radiotherapy [8].

The use of chemotherapy in managing brain stem tumors in children is the subject of numerous clinical trials; unfortunately, at present only phase I or II. Thus, the Children's Cancer Group (CCG) has been testing Toptecan as a radiosensitizer administered in combination with conventional radiotherapy. In the phase I clinical trial, the 1-year survival rate in 17 children was 53% [9]. Phase II results of the same study carried out by CCG were published in 2002; the trial included 63 children randomized into two groups. Group 1 received three cycles of chemotherapy (carboplatin, etoposide and vincristin), while Group 2 was administered three cycles of cisplatin, etoposide, cyclophosphamide and vincristin. In both groups, chemotherapy was employed prior to hyperfractionated radiation therapy. In Group 1, 10±5% children responded to chemotherapy. After radiotherapy, the percentage of responders increased to 27%±9%. In Group 2, a response to chemotherapy was achieved in 19%±8%. After radiotherapy, however, the percentage increased to 23%±9%. The 1-year event-free survival rate for all patients equaled 17%±5%, while the 2-year survival rate was 6%±3% [10]. Also in clinical trials performed by French investigators on 38 children and published in 2002, two cycles of carboplatin administered prior to irradiation and followed by carboplatin employed simultaneously with conventional radiotherapy failed to improve survival rates [11].

In our material, the largest group (17 patients) consisted of children with brain stem tumors with the

type of growth that is associated with a more favorable prognosis – exophytic or focal. Three children had the so-called diffuse brain stem glioma. When comparing the survivals as calculated from the onset of therapy in particular therapeutic groups, one notes that the longest survivals were achieved in patients with exophytic or focal tumors, who were treated surgically and subjected to adjuvant radio- or chemo- and radiotherapy. However, the analyzed groups were small and not uniform in character, and thus did not facilitate an objective assessment of the material.

What is striking in our 14 survivors is their good general and neurological state. All the children resumed schooling. Three patients presently attend primary schools (two of them are taught individually at home), while five continue their secondary level education, including two patients taught in the individual system. Four patients have completed secondary level education; one boy is a university student. Due to disease progression, one patient is unable to continue education. In the group of patients which we have been following up, three years after radiotherapy completion, 60% of school-children have started to experience problems with memorizing text. However, with an increased effort on the part of the patients, teachers and parents, their school performance continues to be good, and allows to complete secondary school and even commence university education. Serious complications of the therapy include endocrine abnormalities. In the majority of cases such disturbances include deficits of thyroid hormones, sex hormones and the growth hormone, which require substitution therapy. In the present material, the authors have not observed hearing loss, which has been reported by other investigators [12]. As follows from the publications on the subject, long-term survival rates are achieved in children with cystic and exophytic tumors, in case of which partial or subtotal tumorectomies are possible and can be followed by adjuvant therapy [2]. In these cases the long-term survival rates are above 50%. Our results are comparable with data reported by various authors, however, our group of patients is small and non-homogenous.

## Conclusions

1. Brain stem tumors constitute a heterogeneous group of neoplasms characterized by a variable degree of biological malignancy.
2. Data obtained in MRI studies and from the clinical presentation have allowed to establish a classification of these tumors and to develop a management protocol.
3. In the vast majority of our patients (17), brain stem tumors are focal and exophytic in character. In such patients, long-term survivals are achieved.
4. Diffuse brain stem tumors, mostly involving the pons (80%), as well as malignant gliomas are associated with poor prognosis (3 patients in our material)
5. In our material, the best results have been achieved in

patients, in whom tumor resections were possible, (even if the procedure was partial) and then were followed by adjuvant therapy.

6. The probability of three-year overall survival for our patients was 70%, and progression-free survival was 65%.

**Elżbieta Korab-Chrzanowska MD, PhD**

1. Division of Radiotherapy  
University Children's Hospital of Cracow  
Wielicka 265, 30-663 Kraków, Poland  
e-mail:ekorchrz@mp.pl

## References

1. Sailer S, Carrie Ch, Frappaz D. Central Nervous Tumors in Children. In: Gunderson L, Tepper J (eds.) *Clinical Radiation Oncology*. Churchill Livingstone 2000; 1052-3.
2. Jallo G, Biser-Rohrbaugh A, Freed D. Brainstem gliomas. *Childs Nerv Syst* 2004; 20: 143-53.
3. Nowosławska E, Polis L, Zakrzewski K. Guzy pnia mózgu u dzieci w materiale oddziału neurochirurgii Centrum Zdrowia Matki Polki w Łodzi. [Brain stem tumors in patients of neurosurgical ward, Center of Polish Mother's Health, Lodz]. *Neur Neurochir Pol* 1996; 30 Supl 4: 98-104.
4. Epstein F, McCleary L. Intrinsic brain-stem tumors of childhood: surgical indications. *J Neurosurg* 1986; 64: 11-5.
5. Skowrońska-Gardas A. Hyperfractionated radiotherapy for brain stem tumors in children. *Radiotherapy & Oncology* 1994; 33: 259-61.
6. Fallai C, Olmi P. Hyperfractionated and accelerated radiation therapy in central nervous tumors (malignant gliomas, pediatric tumors and brain metastases). *Radiotherapy & Oncology* 1997; 43: 235-46.
7. Chuba PJ, Zamarano L, Hamre M et al. Permanent I-125 brain stem implants in children. *Childs Nerv Syst* 1998; 14: 570-7.
8. Schulz-Ertner D, Debus J, Lohr F et al. Fractionated stereotactic conformal radiation therapy of brain stem gliomas: outcome and prognostic factors. *Radiotherapy & Oncology* 2000; 57: 215-23.
9. Sanghavi SN, Needle MN, Krailo MD et al. A phase I study of topotecan as a radiosensitizer for brainstem glioma of childhood: first report of the Children's Cancer Group-0952. *Neuro-Oncology* 2003; 5: 8-13.
10. Jennings MT, Sposto R, Boyett JM et al. Preradiation chemotherapy in primary high-risk brainstem tumors: phase II study CCG-9941 of the Children's Cancer Group. *J Clin Oncol* 2002; 20: 3431-7.
11. Doz F, Neuenschwander S, Bouffet E et al. Carboplatin before and during radiation therapy for the treatment of malignant brain stem tumours: a study by the Societe Francaise d'Oncologie Pediatrique. *Eur J Cancer* 2002; 38: 815-9.
12. Skowrońska-Gardas A, Pędziwiatr K, Chojnacka M. Evaluation of quality of life in long-term survivors of paediatric brain stem tumors, treated with radiotherapy. *Radiotherapy & Oncology* 2004; 70: 269-73.

Paper received: 17 March 2005

Accepted: 25 May 2005