

Metastatic tumors of pancreas — whether and when surgical intervention is gainful for diseased people. Retrospective analysis of data from three surgery centers

Ireneusz Pierzankowski¹, Mariusz Bednarczyk¹, Adam Dmitruk¹, Piotr Hevelke¹, Tomasz Maj¹, Piotr Saramak¹, Piotr Surowski¹, Marek Szpakowski¹, Leszek Zajac¹, Łukasz Zyskowski¹, Jakub Pałucki², Andrzej Krajewski³, Marek Wroński³, Maciej Słodkowski³, Eryk Chrapowicki⁴, Andrzej Cichocki⁴, Maria Zwierko⁵, Tomasz Olesiński¹

Introduction. Metastatic tumors in the pancreas constitute a small (2–5%), but steadily growing percentage of all neoplasms of this organ. The aim of the study was to analyze the surgical treatment of metastases in the pancreas, in particular its effectiveness and the risk of surgical complications.

Material and methods. The retrospective analysis was performed on 21 patients treated surgically in three surgical centers. This group included 16 women (76%) and 5 men (24%). The median age at the time of diagnosis of the underlying disease was 55.5 years (41–71). We analyzed the location of secondary lesions, their size, number, type and radicality of surgical intervention, histopathological diagnosis of the disease, as well as the occurrence of postoperative complications.

Results. The starting point for metastatic lesions in 16 patients (76%) was renal cell carcinoma (RCC), in other cases — skin melanoma, eyeball melanoma, adenocarcinoma of the rectum, non-small-cell bronchi carcinoma. R0 radical surgery was performed in 15 patients (74%) and perioperative mortality was 5% (1 patient died). The median total survival time was 151 months (10–342), with 168 months for RCC (25–344) and 62 months for the remaining cancers (10–241).

Conclusions. The main factor that determines the patient's future fate is the type of primary neoplasm and surgical treatment of metastatic tumors in the pancreas is the best solution for selected RCC cases.

NOWOTWORY J Oncol 2018; 68, 5–6: 240–244

Key words: pancreas, metastasis, surgery, renal cell carcinoma

Introduction

The incidence of pancreatic cancer is statistically 4.8 per 100 thousand inhabitants per year [1]. The most frequently diagnosed malignant cancer is adenocarcinoma, and less frequently neuroendocrine neoplasms. Lesions of metastatic

nature constitute 2% to 5% of all tumors in this organ. They are mainly a manifestation of the propagation of malignant neoplasms: kidney (RCC — renal cell carcinoma), lungs, endocrine glands, colorectal cancer, melanoma and sarcomas. Almost all of these cancers have a tendency to spread

¹Surgery Department of Oncological Gastroenterology Clinic, Maria Skłodowska-Curie Institute — Oncology Center, Warszawa, Poland

²Radiology Department, Maria Skłodowska-Curie Institute — Oncology Center, Warszawa, Poland

³Department and Clinic of General, Gastroenterological and Oncological Surgery, Central Clinical Hospital, Medical University of Warsaw, Poland

⁴Oncology Department, Oncology Clinic, Maria Skłodowska-Curie Institute — Oncology Center, Warszawa, Poland

⁵Cancer Epidemiology and Prevention Department, Maria Skłodowska-Curie Institute — Oncology Center, Warszawa, Poland

through the bloodstream. However, they differ in biology, and thus in prognosis. Thus, the decision on the form of therapy is important in so far as it affects the possibility of cure, the patient's expected survival and quality of life (taking into account the risk of early complications of this treatment in particular).

The aim of the study is to analyze the surgical treatment of metastases in the pancreas, in particular taking into account its effectiveness and the risk of surgical complications.

Material and methods

Retrospective analysis was performed on medical records of 21 patients with metastatic tumors in the pancreas, who were surgically treated in three surgical centers. There were 16 women (76%) and 5 men (24%) in this group. The median age at the time of diagnosis of the underlying disease was 55.5 years (41–71). The diagnosis of lesions in the pancreas and the assessment of the possibility of their removal were determined on the basis of imaging (computed tomography, transcutaneous ultrasound examination) and endoscopic examination (EUS), as well as positron emission tomography (PET-CT). In five cases a biopsy of lesions was performed, including one intraoperative biopsy, during surgery performed due to other indications. The analysis specified the location of secondary lesions, their size, number and type of surgical intervention, as well as the occurrence of postoperative complications. The removed preparations were subjected to histopathological examination, which confirmed the diagnosis and legitimacy of radical surgical treatment. The analysis of the documentation also took into account: sex and age of patients, type and location of primary cancer, time that passed until the appearance of secondary lesions, including pancreatic lesions (Tab. I). Total survival was defined as the time from the diagnosis of the disease until the last observation (February 2018), using the Kaplan-Meier estimator. The survival time from the diagnosis of metastatic lesions in the pancreas was also evaluated in a similar way.

Results

In the evaluated group of 21 patients in 16 (76%) the starting point for metastatic lesions was RCC. In other cases

Table I. The study group

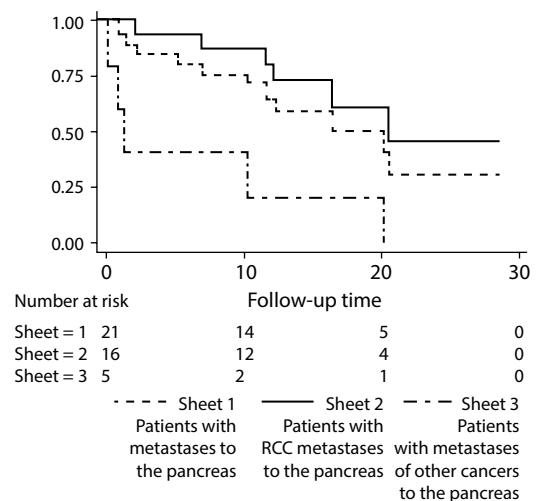
Parameters of the study group	
Women	16 (76%)
Men	5 (24%)
Median of age	55.5 (41–71)
RCC metastases	16 (76%)
Metastases of other cancers	5 (24%)

Table II. Distribution of metastatic lesions to the pancreas by time interval (in months)

Months	Lesions
synchronous	2 (9.5%)
0–12	3 (14%)
12–60	5 (24%)
60–120	5 (24%)
120–240	4 (19%)
> 240	2 (9.5%)

these were: skin melanoma, eyeball melanoma, adenocarcinoma of the rectum, non-small-cell bronchi carcinoma. In one person metastatic lesions of RCC to the pancreas were accompanied by the presence of synchronous neuroendocrine pancreatic tumor. The median time after which distant metastases appeared was 60 months (0–279), and for relapse in the pancreas it was 70 months (0–279) — this is presented in Table II. In two patients metastatic lesions were first localized in other organs (mammary gland, nasopharynx). In the other two — pancreatic metastatic lesions appeared again one year after their first occurrence in this organ. This led in both cases to a new surgery on the pancreas. In one patient, apart from a lesion in the head of the pancreas, the indications for surgery was massive, recurrent bleeding to the gastrointestinal tract. It was caused by a metastatic tumor infiltrating the duodenal wall.

The total survival time in the analyzed group of patients was defined as the period between the diagnosis of cancer and death or the end of observation (February 2018) (Fig. 1). The median total survival time was 151 months (10–342), with 168 months for RCC (25–344) and 62 months for the remaining cancers (10–241). The evaluation also included



P = 0.004 (or the curve comparison log-rank test)

Figure 1. Survival curves for the analyzed group of patients with metastases to the pancreas

total survival from the diagnosis of relapse in the pancreas. For the whole group the median total survival time was 52 months (2–178), with 54.5 months for RCC (3–178) and 10 months for the remaining cancers (2–52).

The size of metastatic changes in the largest dimension was within the range of 15–75 mm. The extent and location of lesions in 10 cases (47.6%) were the cause of pancreatectomy, in 8 cases (38%) — pancreateoduodenectomy, in 2 cases (9.5%) — clinical resection of pancreatic parenchyma, in other 2 cases (9.5%) — local tumor excision, and in 1 case (4.7%) — pancreatectomy. Detailed results of treatment and postoperative complications are presented in Table III.

Discussion

The analysis of the study material and literature data suggest that secondary lesions in the pancreas are generally diagnosed accidentally in imaging performed as part of oncological surveillance [2]. At this stage, due to the potential threat and dynamics of the disease, the most important problem is differential diagnostics, which allows to identify cases of primary pancreatic adenocarcinoma.

In order to diagnose and obtain a comprehensive picture of the disease, it is very important to use auxiliary tests (their invasiveness and time pressure resulting from the biology of pancreatic cancer should be considered). For this reason, the most important in differential diagnostics are: properly collected history and physical examination, imaging and

determination of the level of cancer markers (CA 19.9, CEA, SCC, chromogranin A) and the evaluation of their dynamics. The basic examination in the diagnosis of pancreatic tumors is computed tomography. In its imaging, hypo- or hyperactive lesions, their number, regularity, pancreatic duct dilatation or lack of it, appearance of bile ducts, central necrosis area, presence of metastatic lesions in other locations or the presence of primary lesions are important. (Fig. 2, 3, 4). The above diagnostic measures in most cases allow us to get closer to the diagnosis and to exclude or confirm the presence of metastatic lesions in other organs. In further differentiation it may be useful to make EUS, PET or octreotide scan or PET with gallium. After ruling out primary pancreatic adenocarcinoma at the first stage, these tests may be helpful in establishing a management strategy [2, 3]. Final verification can be obtained after evaluation of the material collected during needle biopsy under ultrasound or during EUS examination (histopathological material allowing differentiation on the basis of immunohistochemical staining).

The literature suggests, which is also reflected in the presented group of patients, that patients with pancreatic RCC metastases have better prognosis than other patients [3–7]. In the group of these patients the best prognosis is for those who are in good general condition (ECOG 0 or 1), have single or few metastases, which appeared not earlier than in 2 years after the disease diagnosis. Other beneficial prognostic factors [3] are: low or indirect malignancy grade in Fuhrman classification, radical excision of neoplastic lesions and lack of disease progression after systemic treatment. Interestingly, isolated pancreatic metastases in RCC have a prognosis better than similar lesions in other locations and may indicate an indolent course of the disease [4, 8]. Nevertheless, it should be noted that in our own material long-term survival was also observed in patients with adenocarcinoma of the rectum and melanoma of the eyeball (8 and 5 years respectively). However, the size of the study group does not allow to draw general conclusions.

Table III. Outcome of surgical treatment*

Radicality	
R0	15 (74%)
R1	5 (21%)
R2	1 (5%)
Complications	
DGE**	7 (30%)
pancreatic fistula	3 (13%)
other	1 (5%)
The severity of complications***	
A	9 (39%)
B	1 (5%)
C	1 (5%)
Mortality*****	
perioperative	1 (5%)
early	1 (5%)
distant	9 (43%)

* a total of 23 surgeries due to pancreatic metastases were performed in 21 patients

** delayed gastric emptying (DGE)

*** according to *International Study Group of Pancreatic Surgery (ISGPS)*

**** perioperative: up to 1 month after the surgery, early: 2-6 months after the surgery, late: more than 6 months after the surgery

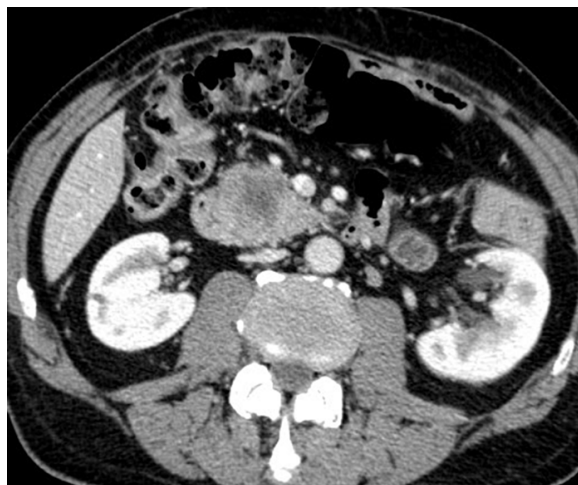


Figure 2. Hypovascular tumor of head of the pancreas — a typical image of adenocarcinoma

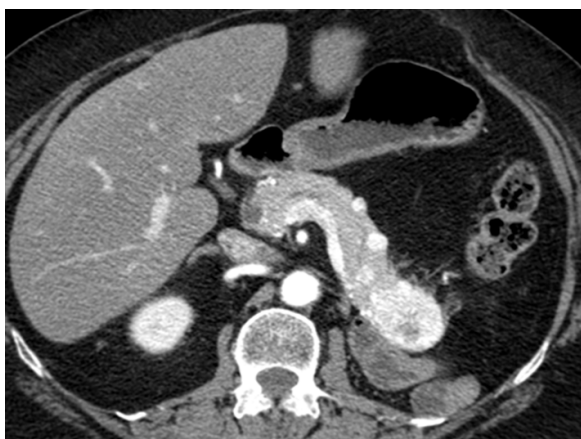

Figure 3. Hypervascular lesions in the pancreas — metastases of clear-cell carcinoma of the kidney

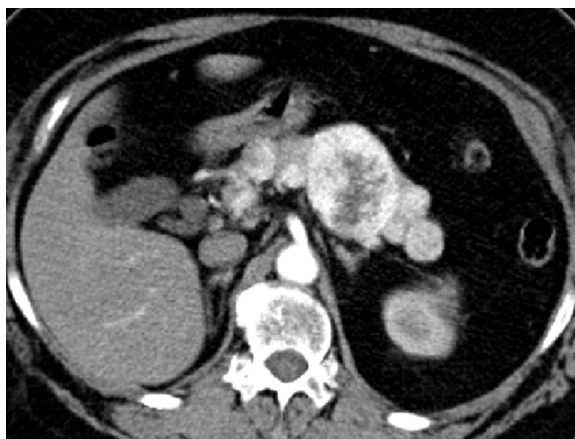

Figure 4. Hypervascular lesions in the pancreas — neuroendocrine cancer (multifocal)

(Radiological picture of clear-cell carcinoma metastases in the pancreas and pancreatic neoplasm (multifocal) is indistinguishable)

On the other hand, the analysis of the Italian material [7] shows that for patients with metastatic tumors of bronchial cancer, sarcomas and (in most cases) melanoma the prognosis is poor. Patients with secondary lesions with a starting point in the breast and large intestine have slightly better chances. It seems that apart from RCC, patients with metastases of neuroendocrine tumors from other locations have the best prognosis. The reason for this situation is probably the fact that the spread of these cancers is very rarely limited, both in terms of the number of metastases and their location, and the greatest benefits of the therapy are enjoyed by patients with beneficial biological characteristics of the tumor and with good response to systemic treatment [7–11]. Relatively good prognosis is also observed in patients with multi-organ resections or successive surgical treatment of metastatic lesions occurring over time, both in the pancreas and in other organs [6]. This fact was also observed in this paper authors' own material.

Researchers from the University of Leipzig have retrospectively analyzed 18 patients with resectional pancreatic metastases of different primary locations, who were surgically treated in the period of 1994–2012. The majority ($n = 10$, 55.5%) were RCC metastases. Moreover, in two cases secondary lesions in the course of melanoma were operated on, in one case each — in the treatment of sarcoma, colorectal cancer, gallbladder cancer, GIST, neuroendocrine cancer and non-small-cell lung cancer. At the same time, 11 patients from this group had different than pancreatic metastases localization with possibility of excision. For this reason, multiple organ resections were performed.

The analysis carried out in this paper does not answer the question whether surgical treatment is clearly better than modern chemotherapy. The main reason for this is the lack of a control group. Based on literature reports, it should be noted that the effectiveness of modern chemotherapy does not differ from that of surgical treatment [12, 13]. On

the other hand, it is worth emphasizing that in centers specializing in pancreatic surgery, perioperative mortality does not exceed 2.5–5%. Radical surgery, in particular of RCC metastasis (especially when it has occurred during the course of the disease), gives patients the chance to cure or survive for a long time without relapse and the feeling of the disease, and avoid the health and economic consequences of many months of palliative chemotherapy [14–20].

One should also not forget about other methods, especially valuable in cases of metastatic lesions being non-operable or non-resectable. Radiofrequency thermoablation, stereotactic radiotherapy, gamma knife or CyberKnife may be an effective alternative to surgical treatment in patients with clear contraindications to the procedure. They may also form part of hybrid therapy, e.g. in the case of resectional metastasis to the pancreas and non-resectional metastasis to the central nervous system [3, 20].

Conclusions

1. The main factor that determines the fate of a patient with metastases to the pancreas is the type of primary cancer.
2. Surgical treatment of metastatic tumors in the pancreas is the best solution for selected RCC cases.
3. Oncological surveillance should take into account the possibility of RCC metastatic lesions which are very distant in time from the initial surgical treatment.

Conflict of interest: none declared

Ireneusz Pierzankowski, MD

*Maria Skłodowska-Curie Institute — Oncology Center
Surgical Department, Clinic of Oncological Gastroenterology
ul. Roentgena 5
02-781 Warszawa, Poland
e-mail: i.pierzankowski@gmail.com*

References

1. Krajowy Rejestr Nowotworów (National Register of Cancers), <http://onkologia.org.pl/nowotwory-trzustki/>
2. Hong-yuan S, Xue-song Z, Fei M. Metastases to the pancreas: computed tomography imaging spectrum and clinical features. A retrospective study of 18 patients with 36 metastases. *Medicine (Baltimore)* 2015; 94: e913.
3. Escudier B, Porta C, Schmidinger M et al. Renal cell carcinoma: ESMO clinical practice guidelines. *Ann Oncol* 2016; 27 (suppl 5): v58–v68.
4. Yuasa T, Inoshita N, Saiura A et al. Clinical outcome of patients with pancreatic metastases from renal cell cancer. *BMC Cancer* 2015; 15: 46.
5. Galia M, Albano D, Picone D et al. Imaging features of pancreatic metastases: A comparison with pancreatic ductal adenocarcinoma. *Clin Imaging* 2018; 51: 76–82.
6. Wiltberger G, Schmelzle M, Hau H-M et al. Extended resection in pancreatic metastases: feasibility, frequency, and long-term outcome: a retrospective analysis. *BMC Surg* 2015; 15: 126.
7. Sperti C, Moletta L, Patanè G. Metastatic tumors to the pancreas. The role of surgery. *World J Gastrointest Oncol* 2014; 6: 381–392.
8. Grassi P, Doucet L, Giglione P et al. Clinical impact of pancreatic metastases from renal cell carcinoma: A multicenter retrospective analysis. *PLoS One* 2016; 11 (4): e0151662.
9. Sperti C, Merigliano S, Moletta L. Metastatic pancreatic tumors: what is the optimal treatment?. *Minerva Chir* 2015; 70: 131–9.
10. Sperti C, Pozza G, Brazzale AR et al. Metastatic tumors to pancreas: a systematic review and meta-analysis. *Minerva Chir* 2016; 71: 337–44.
11. Jakubowski CD, Vertosich EA, Untch BR et al. Complete metastasectomy for renal cell carcinoma: Comparison of five solid organ sites. *J Surg Oncol* 2016; 114: 375–9.
12. Chrom O, Stec R, Bodnar L et al. Prognostic significance of pancreatic metastases from renal cell carcinoma in patients treated with tyrosine kinase Inhibitors. *Anticancer Res.* 2018; 38: 359–365.
13. Santoni M, Conti A, Partelli S et al. Surgical resection does not improve survival in patients with renal metastases to the pancreas in the era of tyrosine kinase inhibitors. *Ann Surg Oncol* 2015; 22: 2094–100.
14. Benhaim R, Oussoultzoglou E, Saeedi Y et al. Pancreatic metastasis from clear cell renal cell carcinoma: outcome of an aggressive approach. *Urology* 2015; 85: 135–40.
15. Kuśnierz K, Mrowiec S, Lampe P. Results of surgical management of renal cell carcinoma metastatic to the pancreas. *Contemp Oncol (Pozn)* 2015; 19: 54–9.
16. Yagi T, Hashimoto D, Taki K, et al. Surgery for metastatic tumors of the pancreas. *Surg Case Rep* 2017; 3: 31.
17. Tanis PJ, van der Gaag NA, Busch OR et al. Systematic review of pancreatic surgery for metastatic renal cell carcinoma. *Br J Surg* 2009; 96 (6): 579–92.
18. Kalra S, Atkinson BJ, Matrana MR et al. Prognosis of patients with metastatic renal cell carcinoma and pancreatic metastases. *BJU Int* 2016; 117: 761–5.
19. Reddy S, Edil BH, Cameron JL et al. Pancreatic resection of isolated metastases from nonpancreatic primary cancers. *Ann Surg Oncol* 2008; 15: 3199–206.
20. O'Sullivan S, Cagney DN. The emerging role of stereotactic radiotherapy in gastrointestinal malignancies: a review of the literature and analysis from the Irish perspective. *Ir J Med Sci* 2018; 1755–8.