

Shinichiro Okauchi¹, Koji Kawai², Kunihiro Miyazaki³, Hideyasu Yamada⁴, Hiroaki Satoh¹

¹Division of Respiratory Medicine, Mito Medical Center, University of Tsukuba, Mito-city, Japan

²Department of Urology, Faculty of Medicine, University of Tsukuba, Tsukuba-city, Japan

³Division of Respiratory Medicine, Ryugasaki Saiseikai Hospital, Ryugasaki-city, Japan

⁴Division of Respiratory Medicine, Hitachinaka Medical Center, University of Tsukuba, Hitachinaka-city, Japan

Regression of renal cyst in a NSCLC patient treated with crizotinib

Dear Editor,

Crizotinib is one of the therapeutic agents for patients with ALK fusion gene mutated non-small cell lung cancer [1–5]. With crizotinib therapy, patients who develop renal cysts have been reported [1–5]. It is well-known that there were patients whose renal cyst had shrunk after discontinuation of crizotinib or change to alectinib [1–3]. Recently we experienced a patient whose renal cyst shrank despite continued treatment with crizotinib which achieved a good therapeutic effect. We would like to share our experience.

A 38-year-old man referred to our hospital due to abnormal opacity in chest radiograph in mass

screening. Since mediastinal lymph node lesions were confirmed during the operation, left pneumonectomy with nodal dissection was performed. The final pathological diagnosis was adenocarcinoma and pathological tumor stage was proved to be T1bN2M0. Fluorescence *in situ* hybridization of the resected specimen revealed a translocation of ALK. On CT scan taken 27 months after the pneumonectomy, a nodule of the left adrenal gland was found, and the patient started to receive crizotinib. On CT scan taken 5 months after the initiation of crizotinib, a cyst was found in the right kidney (Figure 1A). The patient was explained the results of the consultation with the urologist, but he preferred to continue this treatment. Crizotinib therapy was

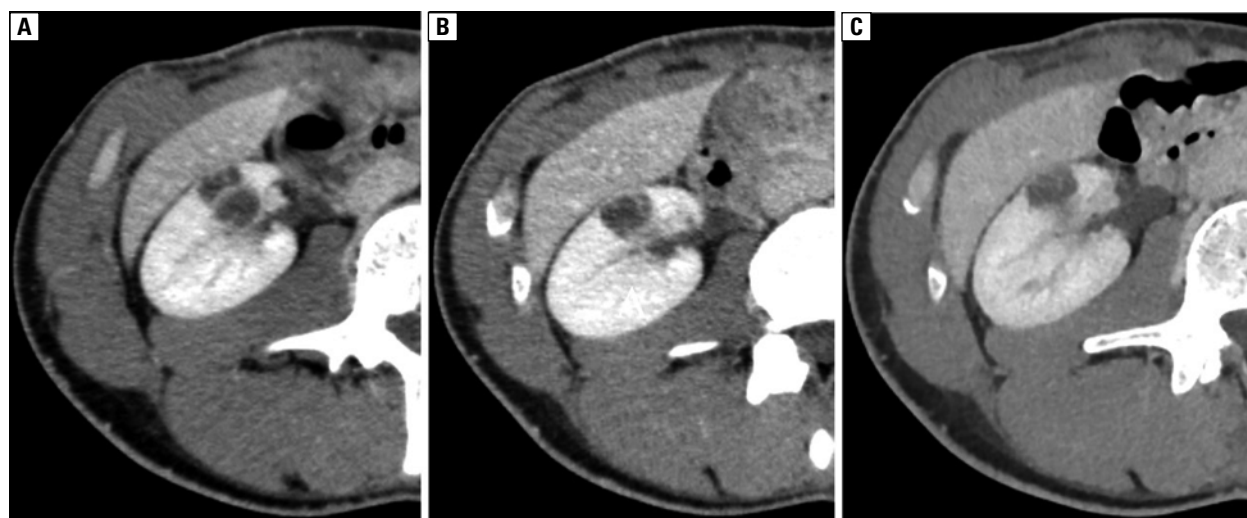


Figure 1. CT taken: A. 5 months; B. 8 months; C. and 17 months after initiation of crizotinib therapy

Address for correspondence: Hiroaki Satoh, Division of Respiratory Medicine, Mito Medical Center, University of Tsukuba, Miya-machi 3-2-7, Mito-city, Ibaraki, 310-0015, Japan; e-mail: hirosato0809@yahoo.co.jp

DOI: 10.5603/ARM.2019.0031

Received: 15.05.2019

Copyright © 2019 PTChP

ISSN 2451–4934

continued and the patient was carefully followed up. CT scan performed 8 months and 17 months after initiation of crizotinib therapy confirmed shrinkage of the cyst. There was no enlargement in cysts on CT performed one year after the shrinkage had been confirmed (Figures 1B, 1C).

Spontaneous regression and shrinkage of the renal cyst without discontinuation of crizotinib occurred [4, 5]. We experienced a patient whose renal cysts shrank despite continued treatment with crizotinib. Rare and careful follow-up is necessary, however, if the effect of crizotinib is sustained, the continuation of the drug may be one of the treatment options.

Conflict of interest and funding

This research did not receive any specific grant from funding agencies in the public, commercial, or not-for-profit sectors.

The authors declare no conflict of interest.

References:

1. Yasuma T, Kobayashi T, D'Alessandro-Gabazza CN, et al. Renal injury during long-term crizotinib therapy. *Int J Mol Sci.* 2018; 19(10), doi: [10.3390/ijms19102902](https://doi.org/10.3390/ijms19102902), indexed in Pubmed: [30257437](https://pubmed.ncbi.nlm.nih.gov/30257437/).
2. Okubo K, Sato A, Nakamoto K, et al. Bosniak category III renal cysts caused by crizotinib in an anaplastic lymphoma kinase gene-rearranged non-small cell lung cancer patient. *Urology.* 2018; 121: e3–e4, doi: [10.1016/j.urology.2018.08.008](https://doi.org/10.1016/j.urology.2018.08.008), indexed in Pubmed: [30142403](https://pubmed.ncbi.nlm.nih.gov/30142403/).
3. Taima K, Tanaka H, Tanaka Y, et al. Regression of crizotinib-associated complex cystic lesions after switching to alectinib. *Intern Med.* 2017; 56(17): 2321–2324, doi: [10.2169/internalmedicine.8445-16](https://doi.org/10.2169/internalmedicine.8445-16), indexed in Pubmed: [28794366](https://pubmed.ncbi.nlm.nih.gov/28794366/).
4. Cameron LB, Jiang DHS, Moodie K, et al. Crizotinib Associated Renal Cysts [CARCs]: incidence and patterns of evolution. *Cancer Imaging.* 2017; 17(1): 7, doi: [10.1186/s40644-017-0109-5](https://doi.org/10.1186/s40644-017-0109-5), indexed in Pubmed: [28209203](https://pubmed.ncbi.nlm.nih.gov/28209203/).
5. Klemptner SJ, Aubin G, Dash A, et al. Spontaneous regression of crizotinib-associated complex renal cysts during continuous crizotinib treatment. *Oncologist.* 2014; 19(9): 1008–1010, doi: [10.1634/theoncologist.2014-0216](https://doi.org/10.1634/theoncologist.2014-0216), indexed in Pubmed: [25096999](https://pubmed.ncbi.nlm.nih.gov/25096999/).