

Mariusz S. Woźniak, Joachim Buchwald, Izabela Stockdale, Zbigniew Doniec

Department of Pneumology, Institute of Tuberculosis and Lung Diseases, Rabka-Zdrój, Poland

## Tracheobronchopathia osteochondroplastica — a 61-year-old female with middle lobe syndrome

The authors declare no financial disclosure

### Abstract

The authors present a case of a 61-year-old female patient suffering from *tracheobronchopathia osteochondroplastica* (TBO). Etiology of this unit is uncertain. TBO is characterised by presence of multiple nodules of various size, situated in the submucosa of the trachea and major bronchi. The course is usually benign, until lesion obstructs the bronchial lumen. In the presented case, occluded middle lobe bronchi resulted in peripheral atelectasis of the lung.

**Key words:** tracheobronchopathia osteochondroplastica, bronchi diseases, middle lobe syndrome, atelectasis, airway obstruction  
**Adv. Respir. Med. 2017; 85: 158–160**

### Case report

A 61-year-old female patient was admitted to the Department of Thoracic Surgery, with opacity visible in the right hilar region on chest X-ray.

About a month prior to admission, this previously healthy patient started to suffer from progressive fatigue, non-productive cough and subfebrile body temperature. Due to the symptoms, she visited the family doctor, who ordered a chest X-ray, which revealed changes in the middle lobe. A day before the admission, the patient began to bring up brown tinted sputum. Symptoms such as weight loss, dyspnoea, or chest pain were not present.

The patient had never been treated by a pulmonologist. Previously she had been diagnosed with spinal degenerative disease and also underwent a wedge resection of the right ovary due to an ovarian cyst 30 years earlier. She had no history of smoking, chronic pharmacotherapy or allergy; she was an office worker, without any environmental exposure to harmful factors, with no significant family history.

On physical examination: conscious, cardiovascularly and respiratorily stable, verbally

responsive. Heart rate 83 bpm, arterial blood pressure 145/90 mm Hg, body temperature 37.1°C, respiratory rate 15 breaths/min, SatO<sub>2</sub> — 93%. On auscultation diminished respiratory sounds, crackles and rhonchi over the middle lobe were found. Basic laboratory tests results were within normal range. The X-ray on admission revealed blurring of the right border of the heart, increased bronchial pattern of the right lung and slightly elevated right hemidiaphragm. Spirometric parameters were as follows: FVC (forced vital capacity) — 3.03 L (103% predicted value, lower limit of normal — 2.22 L), FEV<sub>1</sub> (forced expiratory volume in the one second) — 2.39 L (96.6% predicted value, lower limit of normal — 1.85 L), FEV<sub>1</sub>%FVC — 78.8%.

A CT scan with intravenous contrast injection was performed, showing extensive atelectasis of the middle lobe with no visible cause (Fig. 1).

Numerous irregular and calcified nodules on the front and side walls of the trachea, without substantial narrowing of its lumen, were also described (Fig. 2).

A bronchofiberoptic examination was performed, revealing numerous, small, hard lumps on

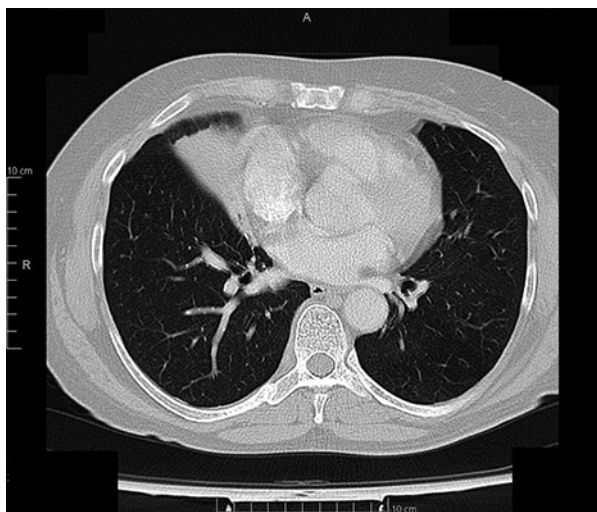
**Address for correspondence:** Mariusz S. Woźniak, Department of Pneumology, Institute of Tuberculosis and Lung Diseases, Rabka-Zdrój, Poland, e-mail: [mwozniak@igrabka.edu.pl](mailto:mwozniak@igrabka.edu.pl)

DOI: 10.5603/ARM.2017.0027

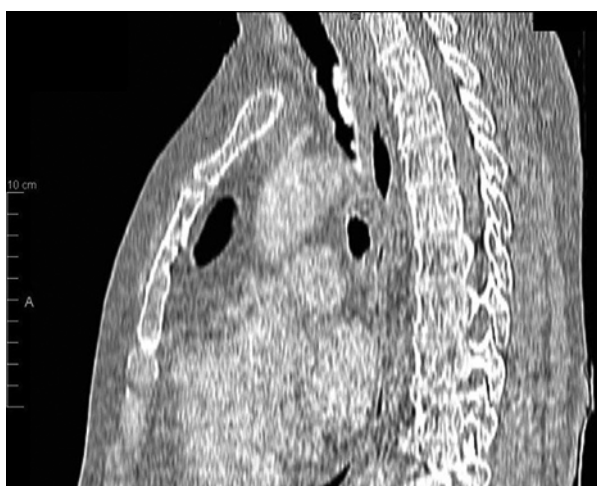Received: 25.10.2016

Copyright © 2017 PTChP

ISSN 2451–4934



**Figure 1.** A CT image of massive middle lobe atelectasis

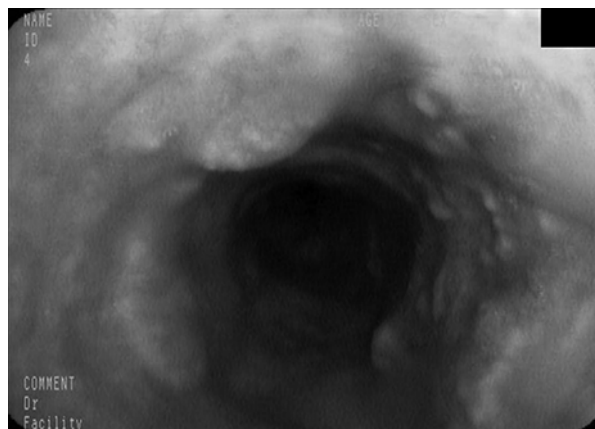


**Figure 2.** CT reconstruction in sagittal plane shows multiple protruding nodules in trachea

the front and side walls of the trachea along the entire length and on the main bronchi as on Figure 3.

The signs of chronic inflammation extended throughout the airways. The opening of the middle lobe bronchus was closed by massive scarring with tiny needle-like lumen, with a small amount of pus exuding through it.

A few sections were taken, aiming to restore patency of the bronchus, but because of the hardness of the lesions it was only possible to get small specimens. Attempts to collect samples of nodules in the trachea were unsuccessful. Bronchial secretion was also collected for bacteriological testing. The changes observed were typical of *tracheobronchopathia osteochondroplastica*. The microscopic evaluation of bronchial content found above 25 neutrophils per field of view. Cultures showed growth of *Pseudomonas aeruginosa*, *Proteus mira-*



**Figure 3.** Bronchoscopy reveals multiple nodules in trachea

*bilis* and *Morganella morganii*. They were negative for fungi and *Mycobacterium tuberculosis*.

The histopathological examination of samples collected from the narrowing of the bronchus was described as follows: a fragment of the bronchial mucosa with fibrosing stroma, with moderately abundant, chronic inflammatory infiltration and foci of squamous metaplasia on the surface.

A decision was made to resect the atelectatic middle lobe. In the presented case, there were no difficulties with intubation, described sometimes in the literature. During the procedure, a fairly large loss of blood occurred — approximately 1 litre. Directly after the surgery, the patient's haemoglobin level was 7.4 g/dL, which spontaneously rose in the following days. Therefore, taking into consideration a general good clinical condition of the patient, PRBCs (packed red blood cells) transfusion was abandoned.

The histopathological examination of the removed, cirrhotic middle lobe revealed numerous small foci of ossification in the cartilage, covered with epithelial squamous metaplasia. In some larger lumps, hematopoietic lines cells were found. Evidence of chronic inflammation was present throughout the specimen.

After a recovery period, the patient was discharged in good general condition. After a year, she reported for a check-up. Her previous symptoms completely disappeared. The HRCT demonstrated proper expansion of the remaining lung parenchyma. The patient is still followed-up by the Department of Thoracic Surgery.

## Discussion

*Tracheobronchopathia osteochondroplastica* (TBO) is a rare condition characterised by the presence of osseocartilaginous nodules in the mucosa of the large bronchi and trachea. The

prevalence is estimated at 1: 2000 of performed bronchoscopies, both in male and female patients [1, 2]. The course of the disease is usually mild, with no symptoms, although in some cases cough, haemoptysis, shortness of breath and recurrent respiratory infections may occur [3]. Lesions located in the upper part of the trachea can sometimes hinder intubation [4] or cause damage to an endotracheal tube [5], whereas changes situated at the opening of the bronchi can lead to atelectasis. The prognosis of patients with TBO is usually favourable, most cases shows very little evolution over a period of years. However, reports reveal that a few patients died of complications of TBO, especially due to severe respiratory infections [1].

The first descriptions of TBO are dated from the second half of the nineteenth century (Rokitansky [1855], Luschka [1856] and Wilks [1857]) [6]. Since then, approximately 400 cases have been described worldwide [7].

The cause of the condition is still unknown. It is believed that it may be associated with chronic inflammation in the airways, e.g. long-lasting infections, injury, silicosis, amyloidosis, allergic bronchopulmonary aspergillosis, asthma or ozaena [8]. Existing theories assume that the initial changes are chondromas, which subsequently ossify; alternatively, ossification of the connective tissue of bronchial mucosa occurs. Lesion development is connected with the bone morphogenetic protein-2 (BMP-2) and transforming growth factor B1 (TGF-B1) [8, 9].

In bronchofiberoptic examination, the tracheal mucosa is typically covered with fine, whitish nodules, protruding into the lumen, giving the image of ‘cobblestone road’ [4].

According to the Japanese data, the most common location of lesions are the trachea and major bronchi (52%), then exclusively the trachea (42%) and finally, solely the large bronchi (6%) [10]. In a few cases, the subglottic larynx was occupied [11].

The posterior, membranous wall of the trachea is always free from the lesions. The nodules are covered with respiratory epithelium, sometimes with foci of squamous metaplasia [12].

At present there is no specific therapy for TBO. Treatment is symptomatic; antitussives and antibiotics (in case of recurrent infections) are used. Surgical removal, cryogenic or radiotherapy, or stent implantation should be performed only in cases of the airway narrowing by the lesions [1].

In the presented case, prolonged obstruction of the bronchus led to atelectasis of the middle lobe, and as a result — to its cirrhosis with chronic inflammation throughout the bronchial tree.

But there is no certainty whether the structure, which occluded the opening of the bronchus, was caused by TBO. The cases of bronchi occlusion by large lesions were reported [6, 13]. However, in those cases ossifying cartilage has been observed, whereas in our patient’s samples the fibrotic lesions, typical of scar tissue, were noted.

Yet, a long-time, asymptomatic course, the presence of squamous metaplasia within the lesion and a full recovery after the removal of the cirrhotic lobe, followed by no recurrence three years after the surgery, seem to confirm *tracheobronchopathia osteochondroplastica* as a primary cause.

### Conflict of interest

The authors declare no conflict of interest.

### References:

- Luo S, Wu L, Zhou J, et al. Tracheobronchopathia osteochondroplastica: two cases and a review of the literature. *Int J Clin Exp Pathol.* 2015; 8(7): 8585–8590, indexed in Pubmed: [26339438](#).
- Zhu Y, Wu N, Huang HD, et al. A clinical study of tracheobronchopathia osteochondroplastica: findings from a large Chinese cohort. *PLoS One.* 2014; 9(7): e102068, doi: [10.1371/journal.pone.0102068](#), indexed in Pubmed: [25013916](#).
- Jabbardarjani HR, Radpey B, Kharabian S, et al. Tracheobronchopathia osteochondroplastica: presentation of ten cases and review of the literature. *Lung.* 2008; 186(5): 293–297, doi: [10.1007/s00408-008-9088-4](#), indexed in Pubmed: [18463923](#).
- Piesiak P, Porębska I, Jankowska R. Tracheobronchopathia osteochondroplastica — case report. *Adv Clin Exp Med.* 2005; 6: 1327–1330.
- Nikandish R, Fallahi MJ, Ziaian B, et al. Repeated Tracheostomy Tube Cuff Rupture Due to Tracheobronchopathia Osteochondroplastica: A Case Report. *Iran J Otorhinolaryngol.* 2015; 27(82): 387–390, indexed in Pubmed: [26568943](#).
- Doshi H, Thankachen R, Philip MA, et al. Tracheobronchopathia osteochondroplastica presenting as an isolated nodule in the right upper lobe bronchus with upper lobe collapse. *J Thorac Cardiovasc Surg.* 2005; 130(3): 901–902, doi: [10.1016/j.jtcvs.2005.01.020](#), indexed in Pubmed: [16153955](#).
- Meyer CN, Døssing M, Broholm H. Tracheobronchopathia osteochondroplastica. *Respir Med.* 1997; 91(8): 499–502, indexed in Pubmed: [9338055](#).
- Michaelides SA, Bablekos GD, Ionas G, et al. Right Upper Lobe Shadow and Tracheobronchopathia Osteochondroplastica Confined to Right Main Bronchus: A Case Report and Literature Review. *Case Rep Med.* 2015; 2015: 368485, doi: [10.1155/2015/368485](#), indexed in Pubmed: [26681946](#).
- Prince JS, Duhamel DR, Levin DL, et al. Nonneoplastic lesions of the tracheobronchial wall: radiologic findings with bronchoscopic correlation. *Radiographics.* 2002; 22 Spec No: S215–S230, doi: [10.1148/radiographics.22.suppl\\_1.g02oc02s215](#), indexed in Pubmed: [12376612](#).
- Laine M, Elfihi S, Kettani F, et al. Tracheobronchopathia osteochondroplastica associated with skin cancer: a case report and review of the literature. *BMC Res Notes.* 2014; 7: 637, doi: [10.1186/1756-0500-7-637](#), indexed in Pubmed: [25212226](#).
- Warner MA, Chestnut DH, Thompson G, et al. Tracheobronchopathia osteochondroplastica and difficult intubation: case report and perioperative recommendations for anesthesiologists. *J Clin Anesth.* 2013; 25(8): 659–661, doi: [10.1016/j.jclinane.2013.05.010](#), indexed in Pubmed: [23988800](#).
- Swamy TLN, Hasan A. Tracheopathia osteoplastica presenting with haemoptysis in a young male. *Indian J Chest Dis Allied Sci.* 2010; 52(2): 119–121, indexed in Pubmed: [20578407](#).
- Shigematsu Y, Sugio K, Yasuda M, et al. Tracheobronchopathia osteochondroplastica occurring in a subsegmental bronchus and causing obstructive pneumonia. *Ann Thorac Surg.* 2005; 80(5): 1936–1938, doi: [10.1016/j.athoracsur.2004.06.101](#), indexed in Pubmed: [16242495](#).