

Ioannis Tomos, Andriana I. Papaioannou, Aikaterini Vlami, Vasiliki Apollonatos, Effrosyni D. Manali, Spyros A. Papiris

2nd Pulmonary Department, "Attikon" University Hospital, Athens Medical School, National and Kapodistrian University of Athens, Greece

Unilateral hypertransparency on chest radiograph: the congenital Poland Syndrome

The authors declare no financial disclosure

Abstract

Unilateral hypertransparent hemithorax requires a particular diagnostic approach as it can be the result of diverse pulmonary diseases, including pneumothorax, large pulmonary embolus, unilateral large bullae, mucous plug, airway obstruction and contralateral pleural effusion. Congenital syndromes with chest wall abnormalities, are rare, but often underdiagnosed causes. Poland Syndrome consists of such a rare, congenital anomaly and is characterized by the absence of the pectoralis major muscle and upper limb ipsilateral abnormalities.

We present a case of a patient with acute exacerbation of chronic obstructive pulmonary disease (COPD) and a unilateral hypertransparency on chest radiology, attributed to the underlying Poland Syndrome.

Key words: chest wall, anatomy, congenital lesions

Adv. Respir. Med. 2016; 84: 342–343

A 65-year old male, current smoker (60 pack-years) with medical history significant for chronic obstructive pulmonary disease (COPD) was admitted to our department complaining of shortness of breath, cough and increased purulent sputum production. Physical examination revealed wheezing and prolonged forced expiratory time, proposing the diagnosis of acute exacerbation of COPD. Additionally, aplasia of the pectoralis major muscle and ipsilateral symbrachydactyly were also observed. Chest X-ray showed right hyperlucent hemithorax (Fig. 1). Chest computed tomography confirmed the asymmetry of the chest with absence of the pectoralis muscles and costal cartilage of ribs 3 through 5 on the right hemithorax (Figs 2–4), suggesting the diagnosis of Poland Syndrome, a rare congenital malformation.

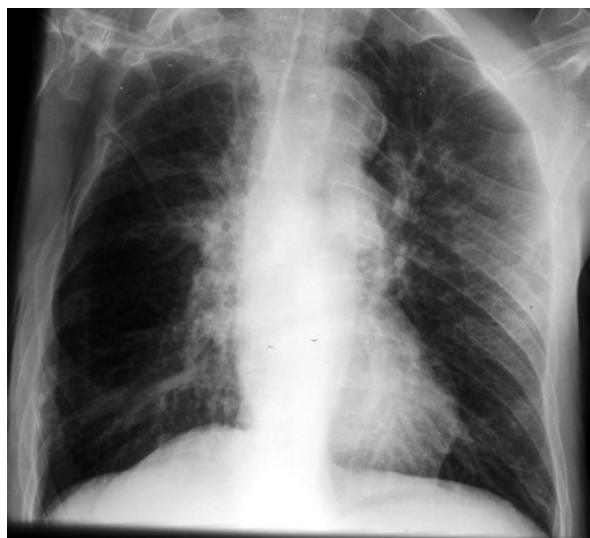

Figure 1. Chest X-ray showed right hyperlucent hemithorax

Address for correspondence: Ioannis Tomos, MD, 2nd Pulmonary Medicine Department, "Attikon" University Hospital, 1 Rimini Street, 12462, Haidari, Greece.

Tel: ++302105831184, Fax: ++302105831184, Mobile; ++306942707287, E-mail address: etomos@hotmail.com

DOI: 10.5603/ARM.2016.0045

Received: 16.09.2016

Copyright © 2016 PTChP

ISSN 2451–4934

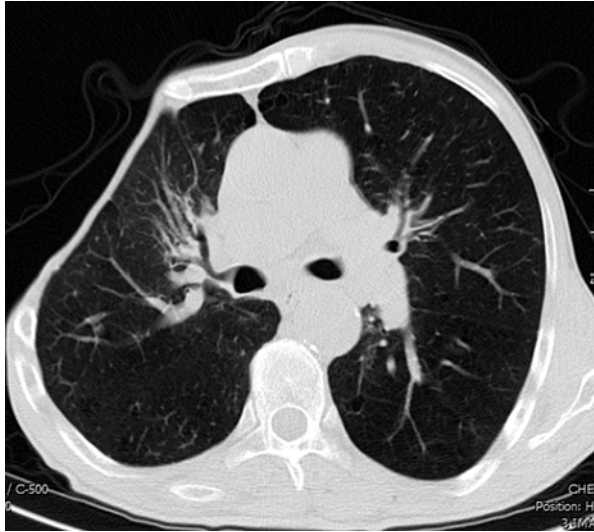


Figure 2. Chest computed tomography confirmed the asymmetry of the chest with absence of the pectoralis muscles and costal cartilage of ribs 3 through 5 on the right hemithorax

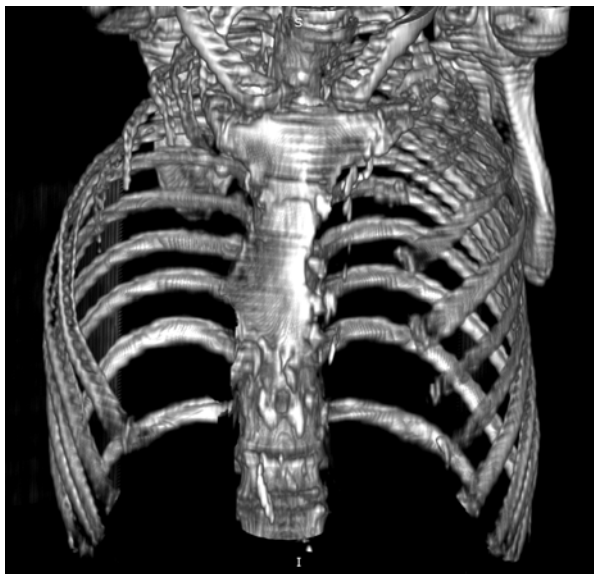

Figure 3. Bony window in 3D reconstruction

Poland Syndrome was first described in 1841 by Sir Alfred Poland, an English surgeon. Its incidence is estimated between 1:35,000 and 1:50,000 [1]. It consists of a rare, congenital anomaly associated with absence of the pectoralis major muscle [1] and upper limb ipsilat-

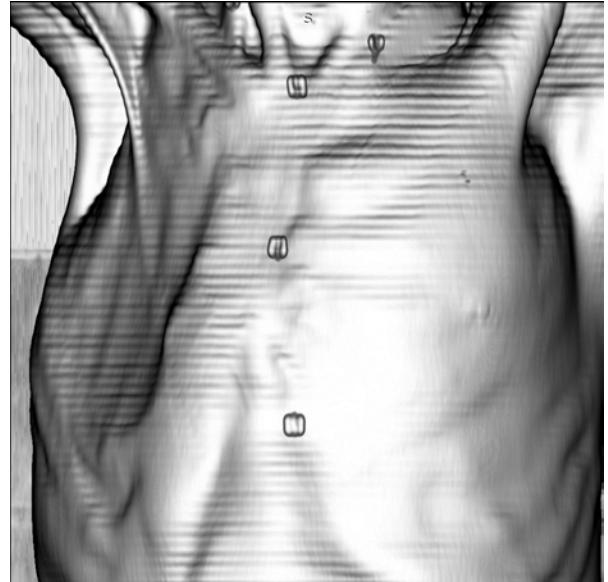

Figure 4. Chest wall 3D reconstruction

eral abnormalities such as syndactyly [2, 3]. Ipsilateral amastia and less commonly, like our case, thoracic rib abnormalities with absence of costal cartilage of the ribs have been also described [1]. Despite the fact that the aetiology of the syndrome has not been fully understood, a vascular developmental abnormality due to hypoplasia of the embryonic subclavian artery and the consequent defective blood supply have been proposed as the cause of the clinical manifestations of Poland Syndrome [1]. Single-stage reconstruction of the chest wall combined with transposing the latissimus dorsi muscle has been reported as effective treatment [3, 4].

Conflict of interest

The authors declare no conflict of interest.

References:

1. Samuels TH, Haider MA, Kirkbride P. Poland's syndrome: a mammographic presentation. *AJR Am J Roentgenol* 1996; 166: 347–348.
2. Parker DL, Mitchell PR, Holmes GL. Poland-Möbius syndrome. *J Med Genet* 1981; 18: 317–20.
3. Yiyit N, Işıtmangil T, Öksüz S. Clinical analysis of 113 patients with Poland syndrome. *Ann Thorac Surg* 2015; 99: 999–1004.
4. Urschel HC Jr. Poland syndrome. *Semin Thorac Cardiovasc Surg* 2009 Spring; 21: 89–94.