

Mateusz Marek Polaczek^{1,2}, Jacek Zych¹, Lucyna Opoka³, Beata Maksymiuk⁴,
Kazimierz Roszkowski-Sliż³

¹3rd Department of Lung Diseases, National Tuberculosis and Lung Diseases Research Institute, Warsaw, Poland

²Department of Descriptive and Clinical Anatomy, Medical University of Warsaw, Warsaw, Poland

³Radiology Department, National Tuberculosis and Lung Diseases Research Institute, Warsaw, Poland

⁴Pathology Department, National Tuberculosis and Lung Diseases Research Institute, Warsaw, Poland

Organizing pneumonia appearing in B-cell chronic leukemia malignancy progression — a case report

The authors declare no financial disclosure

Abstract

Patients with chronic lymphocytic leukemia or non-Hodgkin's lymphoma are at risk of infectious diseases of respiratory system because of immunodeficiency. Occurrence of organizing pneumonia in leukemic patients is most commonly correlated with bone marrow transplant or treatment with antimetabolic agents. There have been only four reported cases of organizing pneumonia related solitarily to leukemia or lymphoma. We present a case of 65-year old gentleman, diagnosed 8 months earlier with B-cell chronic lymphocytic leukemia with no previous hematologic treatment, who presented symptoms of persistent pneumonia with no significant reaction to antibiotics. Chest computed tomography scans showed well-localized consolidation with ground glass opacities and some air bronchogram, suggesting infectious disease. All results of microbiological examinations were negative. Due to radiological progression of parenchymal consolidation despite two intravenous courses of antibiotics open lung biopsy was performed. The histologic examination of lung specimen revealed structures typical for organizing pneumonia pattern. There was no evidence for leukemic involvement in lung tissue, as no sign for infectious factors from histological staining was observed. In the inferior mediastinal lymph node sample progression of chronic lymphatic leukemia to mixed cell lymphoma was diagnosed. Patient was commenced on prednisone 60 mg/daily with fast improvement. We believe that this is the first case of organizing pneumonia as a reaction to the conversion of B-cell chronic lymphocytic leukemia progression to more malignant stage.

Key words: interstitial lung disease, chronic lymphocytic leukemia, leukemia pulmonary complications

Pneumonol Alergol Pol 2015; 83: 307–311

Introduction

Organizing pneumonia (OP) is a relatively rare interstitial pneumonia with well-established histologic features: organization within alveoli and alveolar ducts with or without organization within bronchioles (polypoid bronchiolitis obliterans); the majority of cases center on small airways [1, 2]. Most cases of OP remain idiopathic – cryptogenic organizing pneumonia (COP). There is though a long list of potential causes associated with the occurrence of organizing pneumonia

pattern — infections, aspiration pneumonia, drug reactions, fume and toxic exposure, collagen vascular disease, extrinsic allergic alveolitis, eosinophilic lung disease, inflammatory bowel disease, reparative reaction around processes like abscesses, granulomatosis with polyangiitis, neoplasms and others [1].

B-cell chronic lymphocytic leukemia/small cell lymphatic lymphoma (B-CLL/SLL) is the most common leukemia in Europe and North America. It is characterized by pathologic accumulation of long living small lymphocytes (with expression of

Address for correspondence: Mateusz M. Polaczek, 3rd Department of Lung Diseases, National Tuberculosis and Lung Diseases Research Institute, ul. Plocka 26, 01–138 Warszawa, Poland, tel. +48 22 431 22 18, fax +48 22 431 21 08, e-mail: polaczek@me.com

DOI: 10.5603/PiAPa.2015.0042

Received: 4.07.2014

Copyright © 2015 PTChP

ISSN 0867–7077

CD19, CD20, CD5 and CD23) in the blood stream, bone marrow and lymphatic organs. The differentiation between leukemia and lymphoma is based upon primary involvement of bone marrow in all leukemia cases [3].

Patients present with so called group-B-symptoms (i.e. fever, sweats, weight loss and chronic fatigue). This chronic disease is commonly associated with secondary immunodeficiency and autoimmune disorders causing opportunistic infections, hematologic disorders due to marrow dysfunction and autoimmune reactions [3]. In many cases lymphadenopathy and leukemic infiltrations of extra-lymphatic organs as skin or lungs can be found. Pulmonary involvement in the course of leukemia is observed in many patients. The complications caused primarily by immunodeficiency and hematologic disorders can be also induced by treatment, especially cytostatic drugs, bone marrow transplant or radiation [4].

We present a 65-year old man diagnosed with B-CLL eight months earlier with no history of hematologic treatment. Symptoms suggesting prolonged respiratory system infection, turned out to be OP symptoms. At the same time progression of underlying disease was proven. To our knowledge no case report of OP an indicator of chronic lymphatic leukemia/lymphoma's transformation does exist.

Case presentation

65-year old man was referred to our Institute because of long lasting pneumonia with no improvement despite antibiotic treatment. His symptoms lasted for a month: fever above 39 degrees Celsius, mainly spiking in the afternoon, chronic fatigue and bad tolerance of daily activities, dyspnea at rest, productive cough with purulent sputum. He denied hemoptysis and weight loss. Because of the symptoms he was administered twice with course of oral amoxicillin/clavulanic acid, then with clarithromycin and, afterwards, intra muscular injections of cefuroxime for three days before being admitted to our department. Chest X-ray showed consolidation in the lower right zone, mediastinum and hila shadows were significantly widened (Fig. 1).

He had history of B-cell chronic lymphocytic leukemia diagnosed with bone marrow biopsy 8 months earlier for which he did not get any kind of treatment till date. He smoked 10 cigarettes daily for thirty years.

He was admitted in moderate condition, with dyspnea, exhausting cough and weakness; blood

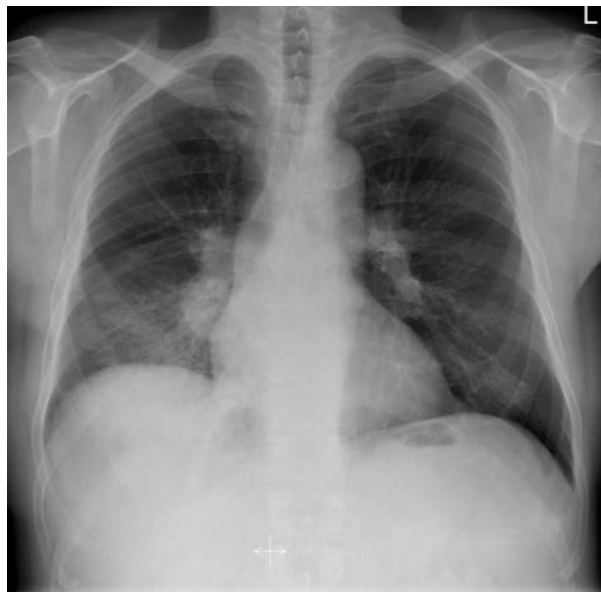

Figure 1. Chest X-ray. Opacities in the right lower zone and widened right hilum and mediastinum

pressure was 145/71 mm Hg and heart rate 78 per minute, blood oxygen saturation 90%, with no cyanosis. On percussion stony dull sound was revealed in right lower zone, on auscultation loud crackles and rhonchi on the right side were present. Neck and axillary lymphadenopathy was noted. The total white cell count was $50.45 \times 10^9/L$, with over 80% population of lymphocytes. C-reactive protein (CRP) elevated 189 mg/L, D-dimer 3416 mcg/L. Arterialized blood gas analysis showed hypoxemia with alkalosis, pO_2 61.7 mm Hg, $PaCO_2$ 32.2 mm Hg, pH 7.52. A chest computed tomography (CT) scan showed significant lymphadenopathy of mediastinal (up to 22 mm) and bilateral hilar nodes (to 34 mm), more expressed on the right side and patchy parenchymal consolidations with ground glass opacities in right inferior basal segments (Fig. 2). There was strong radiological suggestion of infectious etiology, bacterial, atypical bacteria in the first place. Some pleural effusion was visualized via chest wall ultrasound in the right pleural space. A diagnosis of pneumonia was sustained and he was treated empirically with intravenous ceftazidime and ciprofloxacin.

In next days sputum, blood and broncho-alveolar lavage fluid cultures and molecular testing turn out negative for bacteria and acid fast bacilli, molecular testing for *P. jiroveci*, serology for *Ch. pneumoniae*, *L. pneumophila*, *M. pneumoniae* and cytomegalovirus (CMV). (Note that bronchoscopy was delayed until 5th day of treatment due to hypoxemia.) There was

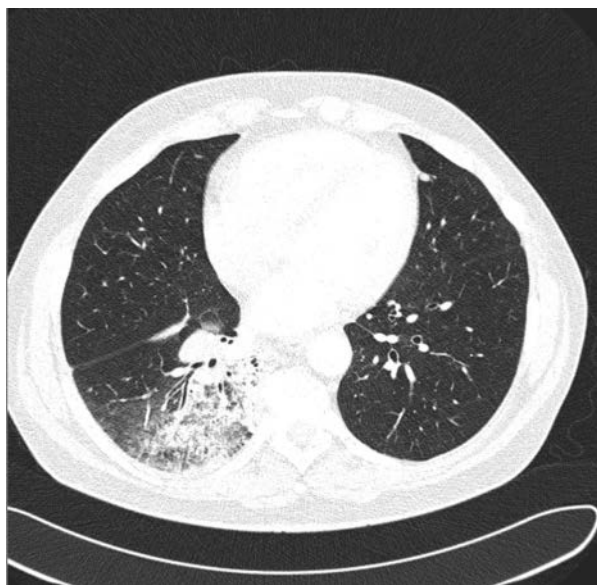

Figure 2. Lung HRCT. Parenchymal consolidations with ground glass opacities in right inferior lobe with a sign of air bronchogram

no response after eight days of treatment; on chest X-ray progression of shadowing in lower right zone was revealed. Decision to perform open lung biopsy via thoracotomy was made. A wedge resection of posterior basal segment of right lower lobe was performed, the lung was in state of hepaticization; also samples of subcarinal lymph nodes were resected. The patient's recovery was good.

Histological examination demonstrated infiltration of pathologic B-cells with CD20 expression and high Ki-67 index within the group 7 lymph node. The pathology specialist suggested CLL/SLL malignancy progression to diffuse mixed cell lymphoma. The lung specimen revealed organizing pneumonia with fibroblast plugs in bronchioles and alveoli, with fibrinous effusion in the air spaces; acute fibrinous and organizing pneumonia was diagnosed (Fig. 3). Lung tissue cultures and staining for infectious factors (bacterial, CMV and *P. jiroveci*) were negative. Also there was no evidence of leukemic infiltrates or lymphoma in the lung specimen.

Patient was referred to a hematologist. Decision to treat the progression of CLL/SLL was postponed. No contradiction for corticosteroid therapy was granted.

Four weeks after surgery patient's condition had slightly improved: fever occurred rarely, dyspnea only at exertion; on auscultation loud wheezes and some crackles were heard, blood gas analysis was normal. We performed spirometry and whole-body plethysmography: it showed moderate airflow obstruction with no volume re-

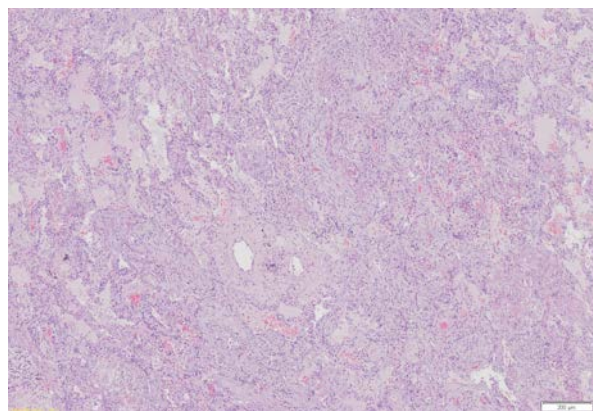


Figure 3. Hematoxylin and eosin staining; 200 ×. Acute fibrinous and organizing pneumonia with proteinaceous exudation in parenchyma, mild chronic inflammatory cell infiltrate and irregular elongated shapes of fibroblast plugs

striction, diffusing capacity for carbon monoxide (DLCO) was at low limit of normal, reversibility testing was not performed. Chest X-ray showed some regression of parenchymal consolidations. Nonetheless we decided to proceed with the treatment, believing that the primary cause of OP was still lasting, so symptoms aggravation could appear. He was commenced with prednisone 60 mg daily (0.75 mg/kg) for the first four weeks. In 2–3 days significant improvement was noted. The dose was thereafter reduced. In 9 months of clinical observation complete normalization of pulmonary function testing and radiological scans was observed, only slight lymphadenopathy persisted. No signs of OP relapse were found.

Discussion

As shown by Bodey et al. infection is the most common pulmonary complication in patients with acute leukemia and should be always the major consideration [5]. Broad spectrum of potential pathogens is possible: bacterial, viral and fungal; what is worth mentioning many nonpathogens (opportunistic microorganisms) are present in lung cultures from leukemic patients. Limited cases of leukemic infiltrates, pulmonary hemorrhage and pulmonary edema were also observed [5]. This can be extrapolated to chronic lymphatic leukemia patients. In presented case primary physician suspected infection and early treatment with empiric antibiotics was pursued correctly.

Lack or subtle clinical symptoms and signs and nonspecific manifestation make the diagnosis of infectious complications in leukemia patients difficult and often postpone it in time [4]. Many

leukemic patients with positive sputum or bronchial lavage cultures have no clinical symptoms of respiratory system infection [5]. If not manifesting as a full-blown pneumonia, radiological evaluation remains crucial in terms of further diagnostic and treatment plan. Radiologic findings in leukemia patients can be described as consolidations, interstitial infiltrates and nodular lesions. It eases the diagnosis especially when compared with patient's symptoms and treatment history. A widely available diagnostic method of great importance is bronchoscopy with broncho-alveolar lavage used for standard cultures and molecular diagnostics; an important point when using bronchoscopy is to perform it early [4]. Our patient presented typical symptoms of pneumonia, with no reaction to broad-spectrum beta-lactams and macrolide. The radiological findings seemed to confirm this diagnosis. We explain the long lasting lack of improvement in patient's clinical state in the following days of intravenous antibiotics by immunodeficiency, believing that bacterial pneumonia fits the symptoms, the radiological observations and medical history. We performed bronchoscopy to obtain material for cultures as soon as respiratory failure was no longer a threat; earlier both patient's sputum and blood, were searched for atypical bacteria and opportunistic infection signs.

There are multiple case reports presenting development of OP in patients with diagnosed leukemia or lymphoma, treated with interferon, cytosine arabinoside, rituximab or rituximab with CHOP (cyclophosphamide, adriamycin, vincristine and prednisone), as well as bleomycin, doxorubicin and chlorambucil [6–8]. But there are four reports of OP related directly to hematologic malignancies, the sequence of the diagnosis differ from case to case [9–12]. The most characteristic pattern was organizing pneumonia that was directly related to leukemic infiltrates or primary lymphoma of the lung [9–11]. Only in the case of smouldering adult T-cell leukemia lung biopsy excluded infiltration of lung tissue with leukemic cells [12]. As suggested many years ago there can be a shared underlying cause for both — lymphoma and OP; some genetic and autoimmune disorders seem to predispose to the development of lymphoid malignant neoplasms. In contrast this mechanism is the main target when treating OP with corticosteroids. It might explain the coexistence of those two rare diseases [9]. In leukemia patients there is higher level of cytokines and soluble interleukin 2 receptors (sIL-2R) in BAL fluid, which proves that lympho-

cytes are in an activated stage. OP is considered to be non-specific inflammatory reaction in lung parenchyma to various stimuli [12]. If so, excessive activation of immune system and abnormal lymphocyte-like cells in leukemia/lymphoma can explain the development of OP [12].

It was already mentioned that many leukemic patients develop infection. This as well is a common cause of organizing pneumonia pattern in histologic examination [1]. This is why all kinds of infectious factors need to be excluded before connecting the dots between leukemia and OP. In our case broad diagnostics was performed to rule out infection: all cultures were negative, no serologic prove of atypical infection was obtained and all the histologic staining for infectious factors were negative.

In one of mentioned cases, OP preceded the diagnosis of primary lung lymphoma by six months. The authors fairly consider if the diagnosis of OP was not in fact the organizing pneumonia pattern present on the peripheral parts of already existing lymphoma infiltration, missed by wrong sampling of lung tissue during biopsy. Alternatively OP in the primary lung lymphoma might work as a paraneoplastic syndrome ahead of time to the development of lymphoma [11]. It is not possible to exclude the possibility that in our case the material we obtained was too superficial to expose the infiltrations of leukemic cells, which is always the risk when sampling only part of the lesion. What stands against this possibility is the fact that patient was already diagnosed with CLL, the neoplastic lesion should be more diffuse, and so the possibility of localized and well-margined leukemic infiltration in this case, with no evidence in 8 cm-wedge-resection lung specimen, is slight. Furthermore we believe that the progression of CLL/SLL to mixed type lymphoma could create this state of immune imbalance that could cause the occurrence of OP. In our case OP could be considered as paraneoplastic syndrome of the progression of CLL/SLL into more malignant type.

In conclusion, the most likely cause of OP in presented case was the progression of chronic lymphocytic leukemia; all the other common and well-established causes were excluded. Occurrence of COP in leukemic patient is possible though. What needs to be emphasized is the odd radiological presentation of this OP case.

Conflict of interest

The authors declare no conflict of interest.

References:

1. American Thoracic Society/European Respiratory Society International Multidisciplinary Consensus Classification of the Idiopathic Interstitial Pneumonias. *Am J Respir Crit Care Med* 2002; 165: 277–304.
2. An Official American Thoracic Society/European Respiratory Society Statement: Update of the International Multidisciplinary Classification of the Idiopathic Interstitial Pneumonias. *Am J Respir Crit Care Med* 2013; 188: 733–748.
3. Robak T, Blonski JZ, Kasznicki M. *Podstawy hematologii*. Dmowska A, Robak T (ed.). Czelej, Lublin 2008; 289–304.
4. Kontoyiannis DP. Rational approach to pulmonary infiltrates in leukemia and transplantation. *Best Pract Res Clin Haematol* 2013; 26: 301–306.
5. Bodey GP, Powell RD, Hersh EM, Yeterian A, Freireich EJ. Pulmonary complications of acute leukemia. *Cancer* 1966; 19: 781–793.
6. Biehn SE, Kirk D, Rivera MP, Martinez AE, Khandani AH, Orłowski RZ. Bronchiolitis obliterans with organizing pneumonia after rituximab therapy for non-Hodgkin's lymphoma. *Hematol Oncol* 2006; 24: 234–237.
7. Macartney C, Burke E, Elborn S et al. Bronchiolitis obliterans organizing pneumonia in a patient with non-Hodgkin's lymphoma following R-CHOP and pegylated filgrastim. *Leukemia Lymphoma* 2005; 46: 1523–1526.
8. Patel M, Ezzat W, Pauw KL, Lowsky R. Bronchiolitis obliterans organizing pneumonia in a patient with chronic myelogenous leukemia developing after initiation of interferon and cytosine arabinoside. *Eur J Haematol* 2001; 67: 318–321.
9. Romero S, Martin C, Massuti B, Aranda I, Hernandez L. Malignant lymphoma in a patient with relapsing bronchiolitis obliterans organizing pneumonia. *Chest* 1992; 102: 1895–1897.
10. Paul V, Lipshitz J, Bergman M. B-Cell Lymphoma in association with organizing pneumonia. *Chest* 2014; 145: 310A.
11. Safadi R, Berkman N, Haviv YS, Ben-Yehuda A, Amir G, Napatsek Y. Primary non-Hodgkin's lymphoma of the lung presenting as bronchiolitis obliterans organizing pneumonia. *Leukemia Lymphoma* 1997; 28: 209–213.
12. Matsuo K, Tada S, Kataoka M et al. Bronchiolitis obliterans organizing pneumonia (BOOP) in a case of smouldering adult T-cell leukaemia. *Respirology* 2000; 5: 81–85.