

Antonello Nicolini¹, Gianluca Ferraioli², Renata Senarega³

¹Respiratory Diseases Unit, General Hospital of Sestri Levante, Italy

²Emergency Department, ASL4° Chiavarese, Italy

³Department of Radiology, General Hospital of Sestri Levante, Italy

Severe *Legionella pneumophila* pneumonia and non-invasive ventilation: presentation of two cases and brief review of the literature

The authors declare no financial disclosure.

Abstract

Legionella pneumophila is an agent also well known to be frequently responsible for severe community acquired pneumonia. Recent studies regarding severe community-acquired pneumonia have shown that *Legionella pneumophila* is the second most common cause of admission to ICU, not far behind pneumococcal pneumonia. The mortality of severe *Legionella pneumonia* is high (30%).

We report two cases of severe respiratory failure due to *Legionella pneumophila* type 1 treated with non-invasive ventilation in the Respiratory Intermediate Care Unit of a Department of Respiratory Medicine with good outcomes.

Severe community-acquired pneumonia is the most common cause of ARDS, and it is the primary reason for Intensive Care Unit admission with invasive mechanical ventilation. Delay in ICU admission is probably associated with a poorer outcome. The use of non-invasive ventilation in severe community acquired pneumonia is controversial. However, after recent pandemics, the number of studies reporting good rates of success for NIV has increased.

Both our patients were managed in a respiratory intermediate care unit, avoiding invasive ventilation and invasive monitoring, which lowered costs yet was equally effective in providing a good outcome when compared to intubation in the Intensive Care Unit.

Key words: severe community-acquired pneumonia, severe respiratory failure, *Legionella pneumophila*, non-invasive ventilation, non-invasive monitoring

Pneumonol. Alergol. Pol. 2013; 81: 399–403

Introduction

A significant increase in the incidence of *Legionella pneumophila* diseases has been documented in recent years. The increased incidence is global; for example, Germany has seen a significant increase in community-acquired pneumonia (CAP) due to this organism [1]. Legionnaires' disease is a significant health problem in many countries, largely because *Legionella pneumophila* pneumonia is a frequent culprit in CAP as well as hospital-acquired pneumonia (HAP) [2]. Smoking, chronic obstructive lung disease, diabetes, chronic

corticosteroid therapy and immuno-compromised status are known risk factors for Legionnaires' disease [3]. Outcomes were studied in a group of 65 patients with severe complications due to *Legionella pneumophila* pneumonia. Six patients died (9.2%): four died from septic shock and multi-organ dysfunction syndrome (MODS); the other two died from interstitial pulmonary fibrosis. Other severe complications were noted: acute respiratory distress syndrome (three cases), renal failure (two cases), disseminated intravascular coagulation (two cases), septic shock/MODS (two cases), and interstitial pneumonia/pulmonary fibrosis (two cases) [4].

Address for correspondence: Antonello Nicolini, Respiratory Diseases Unit, General Hospital, via Terzi 43, 16039 Sestri Levante, Italy, e-mail:antonello.nicolini@fastwebnet.it

Praca wpłynęła do Redakcji: 22.09.2012
Copyright © 2013 PTChP
ISSN 0867-7077

Moreover, *Legionella pneumophila* was found co-infecting two cases of H1N1 virus pneumonia leading to severe respiratory failure and refractory hypoxemia [5]. *Legionella pneumophila* is an agent also well known to be frequently responsible for severe community acquired pneumonia (SCAP) and immune-mediated extrapulmonary involvement [6]. Because of this, many patients are admitted to intensive care unit (ICU), and mechanical ventilation is often required [7]. The use of non-invasive ventilation (NIV) to treat severe CAP, principally in Intensive Care Units, has increased recently [6]. We report two cases of severe respiratory failure due to *Legionella pneumophila* type 1 treated with non-invasive ventilation in the Respiratory Intermediate Care Unit of a Department of Respiratory Medicine with good outcomes.

Case report

Case 1

A 76-year-old man with smoking and COPD history treated with salmeterol and fluticasone twice per day was admitted to the Emergency Department for severe pneumonia and respiratory failure (oxygen saturation in room air 77%). He had yellow-green sputum production, fever, mild dyspnoea and a 39° fever. Chest X-ray showed dense multilobar consolidations (Fig. 1A). Oxygen therapy at 40% flow was administered immediately. Upon arrival at the Department of Respiratory Medicine the following vital signs were obtained: respiratory rate 30 breaths/min, and pulse 120 beats/min. Inspiratory crackles were heard in the middle and basal zones of both lungs. Arterial blood gas (ABG) analysis revealed paO_2 51.7 mm Hg, PaCO_2 29.8 mm Hg, pH 7.53, HCO_3^- 26.7, and $\text{paO}_2/\text{FIO}_2$ with FIO_2 40% was 129. SAPS II was 23. He was diagnosed with severe respiratory failure and started non-invasive ventilation using a Respironics V60 dedicated NIV platform ventilator and full face mask with the following settings: IPAP 14 cm H_2O , EPAP 10 cm H_2O , FIO_2 30%. After 1 hour ABG was repeated: paO_2 59.1, paCO_2 31.7, pH 7.482, $\text{paO}_2/\text{FIO}_2$ with FIO_2 30% 197 and respiratory rate 26 m^{-1} . The patient continued non-invasive ventilation and avoided intubation [8]. Specific urinary-test for *Legionella pneumophila* type 1 was positive. Specific urinary-test for *Streptococcus pneumoniae* was negative. For this reason Clarithromycin 500 mg twice a day IV and levofloxacin 1000 mg IV once a day were started. Laboratory examination on admission revealed: red blood cells, 3,900,000; haemoglobin, 12.60 g/dl, haematocrit, 37.5%; leukocytes 13970 (neutrophils

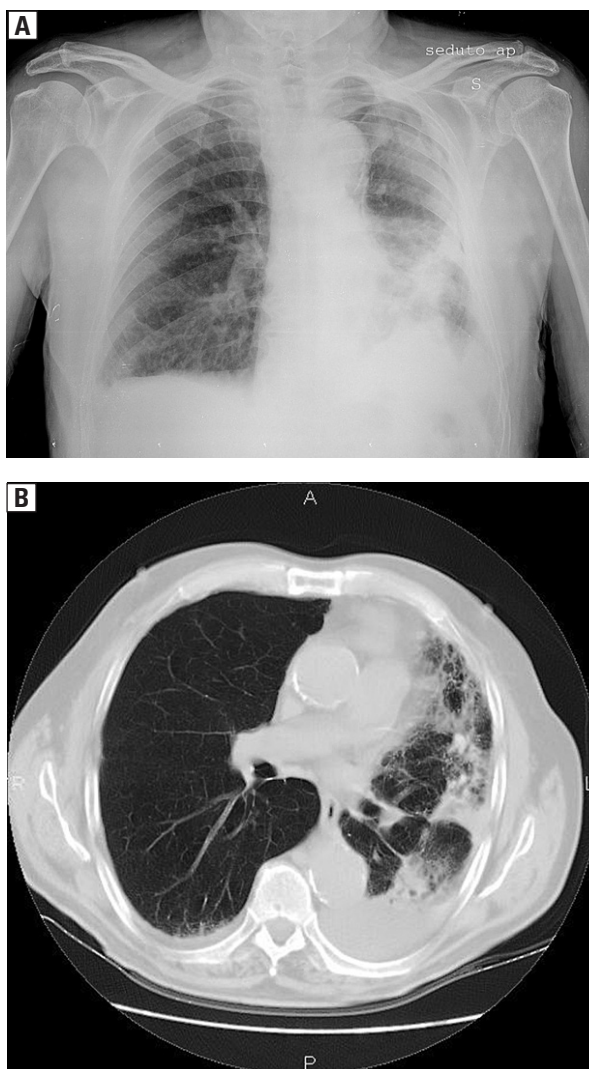


Figure 1 A, B. Chest X-ray and chest computed tomography: patchy multilobar consolidations involving left lung with basal pleural effusion and small right basal pleural effusion

94.3%, lymphocytes 3.60%), glucose 138 mg/dl, AST 22 U/L, ALT 17 U/L, GGT 73 U/L, sodium 144 mEq/l, potassium 3.05 mEq/l, chloride 103 mEq/l, calcium 8.15 mg/dl, LDH 407 U/L and C-reactive protein 48.22 mg/dl. Chest computed tomography showed multifocal consolidations involving the left lung with small pleural effusion and ground glass opacities associated small pleural effusion on the lower right zone (Fig. 1B). Echocardiography showed no pericardial effusion. The patient continued non invasive ventilation for thirteen days (progressively reducing the NIV time of treatment) and was discharged after twenty-five days. Respiratory parameters and blood gas analysis are shown in Table 1.

The functional measurements performed the day before the discharge showed moderate obstructive lung function impairment (FVC 74.5%

Table 1. Respiratory parameters and blood gas analysis

| | 0 h Start NIV | 1 h | 12 h | 24 h | Day 3 | Day 7 | Day 10 | Day 13 withdraw |
|--------------------|------------------|------|------|------|-------|-------|--------|--------------------|
| RR | 30 | 27 | 24 | 25 | 22 | 20 | 20 | 18 |
| IPAP | 14 | 16 | 16 | 14 | 10 | 10 | 8 | |
| EPAP | 10 | 12 | 12 | 10 | 7 | 6 | 4 | |
| FIO ₂ % | 40 | 30 | 30 | 40 | 35 | 35 | 28 | 21 |
| PaO ₂ | 29.8 | 59.1 | 59.0 | 80.7 | 72.1 | 75.9 | 65.1 | 61.7 |
| PaCO ₂ | 51.7 | 38.2 | 36.1 | 35.7 | 39.4 | 36.2 | 32.3 | 35.2 |
| Ph | 7.53 | 7.48 | 7.47 | 7.51 | 7.43 | 7.45 | 7.47 | 7.46 |
| HCO ₃ | 26.7 | 25.6 | 25.5 | 28.9 | 25.9 | 24.3 | 24.8 | 24.6 |
| P/F | 129 | 197 | 197 | 201 | 206 | 216 | 233 | 294 |

RR — respiratory rate; IPAP — inspiratory positive airway pressure; EPAP — expiratory positive airway pressure; FIO₂% — fraction of inspired oxygen in a gas mixture; PaO₂ — arterial oxygen pressure; PaCO₂ — arterial carbon dioxide pressure; P/F — PaO₂/FIO₂ ratio; NIV — non-invasive ventilation

FEV₁ 56.7% TI (Tiffeneau index) 66.9 TLC 127.9%, RV 138.8%). At 90th day follow-up and six month follow-up the patient continued bronchodilator therapy and had a good general condition of health.

Case 2

A 83-year-old woman, suffering from pre-existing diabetes and systemic hypertension, was admitted to the Respiratory Department with a diagnosis of bilateral pneumonia with respiratory failure. She had wet cough, fever (38.5°), and dyspnoea. She was in respiratory failure (paO₂/FIO₂ ratio 253). Radiological findings of bilateral opacities involving lower lung zones were observed (Fig. 2A). At admission vital signs were as follows: respiratory rate 24 breaths/min, pulse 108 beats/min, and blood pressure 130/80 mm Hg. Inspiratory crackles were detected at the middle and basal left zones and at the basal right zone. Arterial blood gas analysis (ABG) demonstrated: paO₂ 100.2 with FIO₂ 40% paCO₂ 33.8, pH 7.48, HCO₃ 26.2, paO₂/FIO₂ ratio 250. The patient was non-invasively monitored and continued oxygen therapy at 40% flow. The patient was started immediately on antibiotic therapy: levofloxacin IV 1000 mg/24 h. plus ceftriaxone 2 g/24 h. Twelve hours later the clinical picture had worsened: she developed tachypnoea (respiratory rate 32 breaths/min), tachycardia (pulse 124 beats/min), hypotension (blood pressure 85/50 mm Hg) and severe respiratory failure (paO₂ 69.5 at oxygen flow 50% paCO₂ 30.5, pH 7.53 HCO₃ 21.6, PaO₂/FIO₂ ratio 116). Infusions of glucocorticosteroids (hydrocortisone 500 mg IV per day) as well as intravenous colloids 1000 ml and dopamine at dosage 400 mg/24 h were quickly started and continued for 48 hours.

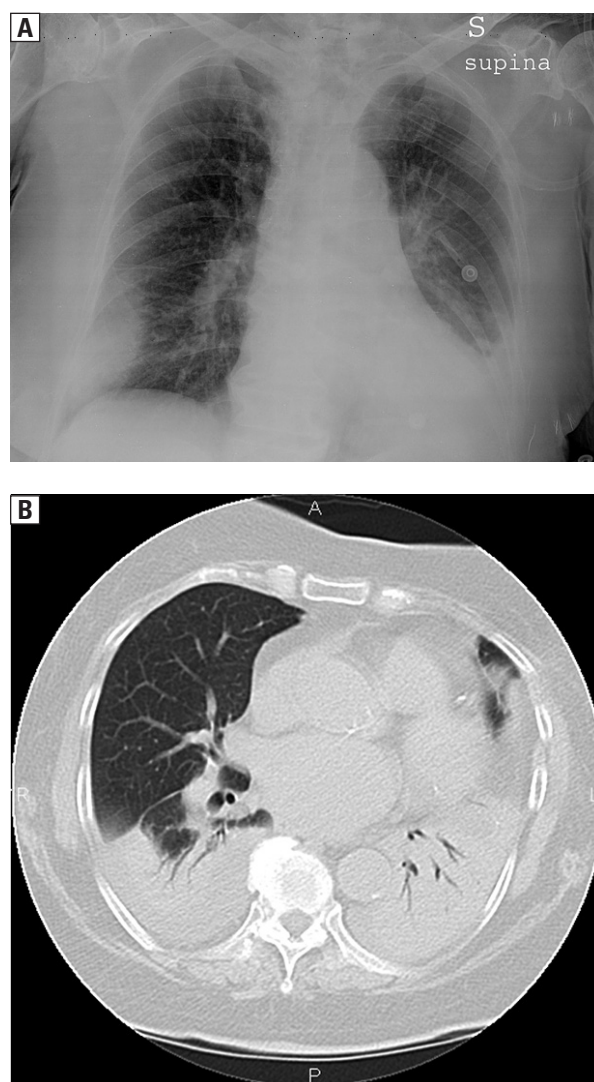


Figure 2 A, B. Chest X-ray and chest computed tomography: bilateral consolidations with alveolar bronchogram involving lower lobes associated with small bilateral pleural effusions

Table 2. Respiratory parameters and blood gas analysis

| | 0 h Start NIV | 1 h | 12 h | 24 h | Day 3 | Day 7 | Day 12 withdraw |
|--------------------|------------------|------|------|------|-------|-------|--------------------|
| RR | 30 | 28 | 27 | 27 | 24 | 22 | 22 |
| IPAP | 16 | 16 | 16 | 16 | 12 | 10 | |
| EPAP | 10 | 10 | 10 | 8 | 8 | 5 | |
| FIO ₂ % | 50 | 40 | 40 | 40 | 31 | 30 | 25 |
| PaO ₂ | 69.5 | 75.9 | 77.8 | 80.3 | 70.8 | 74.1 | 68.9 |
| PaCO ₂ | 30.5 | 37.5 | 34.8 | 36.4 | 38.5 | 36.6 | 37.6 |
| Ph | 7.53 | 7.49 | 7.45 | 7.47 | 7.44 | 7.44 | 7.44 |
| HCO ₃ | 21.6 | 22.4 | 22.6 | 25.3 | 26.2 | 26.2 | 25.2 |
| P/F | 116 | 190 | 195 | 201 | 228 | 247 | 287 |

RR — respiratory rate; IPAP — inspiratory positive airway pressure; EPAP — expiratory positive airway pressure; FIO₂% — fraction of inspired oxygen in a gas mixture; PaO₂ — arterial oxygen pressure; PaCO₂ — arterial carbon dioxide pressure; P/F — PaO₂/FIO₂ ratio NIV — non-invasive ventilation

Clarithromycin 500 mg twice a day IV was added. The patient began non-invasive ventilation with a full face mask using a Respironics V 60 dedicated NIV platform ventilator with the following settings: IPAP 16 cmH₂O EPAP 10 cmH₂O FIO₂ 40%. ABG control after 1 hour showed: paO₂ 75.9 at oxygen flow 40% paCO₂ 37.5 pH 7.49 HCO₃ 22.4 PaO₂/FIO₂ ratio (P/F) 190. The patient continued non invasive ventilation and avoided intubation [8]. Specific urinary-test for *Legionella pneumophila* type 1 was positive. Specific urinary-tests for *Streptococcus pneumoniae* and IgM antibodies against *Mycoplasma pneumoniae* were negative. Laboratory tests on admission were as follows: red blood cells 3,850,000, haemoglobin 11.6 g/dL, haematocrit 35.2%, leukocytes 17.760 (neutrophils 95.0% lymphocytes 3.2%), glucose 298 mg/dl, creatinine 0.88 mg/dL, urea 51 mg/dL, AST 33 U/L, ALT 19 U/L, GGT 41, sodium 137 mEq/L, potassium 3.00 mEq/L, chloride 103 mEq/L, calcium 9.52 mg/dL, LDH 441 U/L, and C reactive protein 54.90 mg/dL. Chest computed tomography showed bilateral patchy opacities of lower lobes associated with bilateral pleural effusions and ground glass opacities involving the upper left lobe (Fig. 2B). Respiratory parameters and blood gas analysis are shown in Table 2. The patient continued non-invasive ventilation for twelve days and was discharged after twenty-four days. At 90th day follow-up and six month follow-up the patient was alive and presented a good general condition of health. The two patients have given consent for the publication of material relating to them.

Discussion

During the last 35 years *Legionella pneumophila* has become widely recognized as a common cause of (CAP) [9]; it is the causal agent of 5% to 12% of

sporadic community-acquired pneumonia cases although rates are changing with the use of new diagnostic methods [10]. Recent studies regarding severe community-acquired pneumonia have shown that *Legionella pneumophila* is the second most common cause of admission to ICU, not far behind pneumococcal pneumonia [6, 9]. The mortality of severe *Legionella pneumonia* is high (30%).

Poor outcomes are correlated with pre-existing comorbidities (e.g. cardiac diseases, diabetes, acute renal failure). Septic shock, chest X-ray extension, severity of respiratory failure (paO₂/FIO₂ ratio < 130, paO₂ < 60 mm Hg, respiratory rate > 30 breaths), and hyponatremia (sodium ≤ 136 mEq/L) are indicators of poor prognosis [9,10]. The term “severe CAP” (SCAP) was created to identify the group of patients presenting clinical characteristics described above [11, 12]. *Streptococcus pneumoniae* and *Legionella pneumophila* are also the most common causative organisms both in immuno-compromised patients and in non-immuno-compromised patients [11, 13]. *Legionella pneumophila* SCAP is linked to several risk factors such as chronic steroid use, humid weather, male sex, smoking, diabetes mellitus, cancer, end-stage renal disease, and HIV infection [11]. SCAP is the most common cause of ARDS [11]; it is the primary reason for Intensive Care Unit (ICU) admission [11] with invasive mechanical ventilation. Delay in ICU admission is probably associated with a poorer outcome [14].

The use of corticosteroids in SCAP is controversial. It does not improve clinical outcomes, and it prolongs hospitalization [15]. In our case we used corticosteroids as a rescue therapy to prevent septic shock for a short period. Antibiotic therapy is the cornerstone of the treatment, especially in severe Le-

gionella pneumonia. As previously demonstrated, combined therapy improves survival in critically ill patients with severe pneumonia. Combined treatment with quinolones is the best option for severe legionella pneumonia, and it is better than monotherapy [16]. Laboratory and experimental data suggest that both fluoroquinolones and newer macrolides are superior to erythromycin, and recent studies suggest that levofloxacin should be considered the drug of choice for the treatment of mild to moderate Legionella pneumonia. Traditional combinations do not always work. Rifampin was a very active drug against Legionella, but the organism is showing increased resistance [16]. Therefore, we used a combined treatment with levofloxacin and clarithromycin, a combination uncommonly used [16]. This combination therapy proved effective in our two cases.

The use of non-invasive ventilation (NIV) in SCAP is controversial. The risks of NIV failure in these patients are not yet clear [17]; however, after recent pandemics, the number of studies reporting good rates of success for NIV has increased [18]. The use of NIV in *Legionella pneumophila* was described in only one case managed in a medical ICU; it avoided invasive mechanical ventilation and had a good outcome [19]. The two cases presented here had SAPS II lower than 34 and PaO₂/FIO₂ after 1 hour greater than 175, which are predictors of NIV success [8, 20]. Both patients were managed in the respiratory intermediate care unit [21], avoiding invasive ventilation and invasive monitoring, using less expensive but equally effective strategies. In severe pneumonia the continuous monitoring of the patients' status is crucial for optimal outcome. We underline that the PaO₂/FIO₂ ratio improved rapidly and continuously. We stress that no other organ failure complicated the hospital course of our two patients.

Monitoring other organ systems is of paramount importance. We are aware of the limitations of this report. More specific parameters are needed to identify CAP severity and its outcome. Studies are required to identify predictors of success or failure of non-invasive ventilation, which would allow safe management of SCAP outside the ICU.

Conflict of interest

The authors declare no conflict of interest.

Acknowledgements

The author would like to thank Dr. Cornelius Barlascini for reviewing the manuscript.

Conflict of interest

The Authors declare no conflict of interest.

References:

- Carratala' J., Garcia-Vidal C. An update on Legionella. *Curr. Opin. Infect. Dis.* 2010; 23: 152–157.
- Diederer B.M. Legionella spp and Legionnaires' disease. *J. Infect.* 2008; 56: 1–12.
- Biegel F, Jurgens M., Filik L. et al. Severe legionella pneumophila pneumonia following Infiximab therapy in a patient with Crohn's disease. *Inflamm. Bowel. Dis.* 15: 1240–1244.
- Takayanagi N., Ishiguro T., Matsushita A. et al. Severe complications and their outcomes in 65 patients with Legionella pneumonia. *Nihon. Kokyuki. Gakkai. Zasshi.* 2009; 47: 58–68.
- Iannuzzi M., De Robertis E., Piazza O., Rispoli F., Servillo G., Tufano R. Respiratory failure presenting in H1N1 influenza with Legionnaires disease; two case reports. *J. Med. Case. Rep.* 2011; 5: 520.
- De Pascale G., Bello G., Tumbarello M., Antonelli M. Severe pneumonia in intensive care: cause, diagnosis, treatment, and management: a review of the literature. *Curr. Opin. Pulm. Med.* 2012; 18: 213–221.
- Falco V., Fernandez de Sevilla T., Alegre J., Ferrer A., Martinez Vazquez J.M. Legionella pneumophila: a cause of severe community-acquired pneumonia. *Chest* 1991; 100: 1007–1011.
- Antonelli M., Conti G., Esquinas A. et al. A multiple-center survey on the use in clinical practice of non invasive ventilation as a first-line intervention for acute respiratory distress syndrome. *Crit. Care Med.* 2007; 35: 18–25.
- El-Ebiary M., Sarmiento X., Torres A. et al. Prognostic factors of severe Legionella Pneumonia requiring admission to ICU. *Am. J. Resp. Crit. Care Med.* 1997; 156: 1467–1472.
- Benito J.R., Montejo J.M., Cancelo L. et al. Neumonia comunitaria por Legionella pneumophila serogrupo 1. Estudio de 97 casos. *Enferm. Infec. Microbiol. Clin.* 2003; 21: 394–400.
- Restrepo M.I., Anzueto A. Severe community-acquired pneumonia. *Infect. Dis. Clin. N. Am.* 2009; 23: 503–520.
- Brown S.M., Dean N.C. Defining severe pneumonia. *Clin. Chest Med.* 2011; 32: 469–479.
- De Sousa I.J., Dominguez A., Manzur A. et al. Community-acquired pneumonia in immunocompromised older patients: incidence, causative organisms and outcome. *Clin. Microbiol. Infect.* 2013; 19: 187–192.
- Restrepo M.I., Mortensen E., Rello J., Brody J., Anzueto A. Late admission to the ICU in patients with community-acquired pneumonia is associated with higher mortality. *Chest* 2010; 137: 552–557.
- Polverino E., Cilloniz C., Dambrava P., Gabarrus A., Ferrer M., Agusti C. Systemic corticosteroids for community acquired pneumonia: reasons for use and lack of benefit on outcome. *Respirol.* 2013; 18: 263–271.
- Rello J., Gattarello S., Souto J. et al. Community-acquired Legionella pneumonia in the intensive care unit: impact on survival of combined antibiotic therapy. *Med. Intensiva* 2012; dx.doi.org/10.1016/J.Medin.2012.05.10.
- Carrillo A., Gonzales-Diaz G., Ferrer M. et al. Non-invasive ventilation in community-acquired pneumonia and severe respiratory failure. *Intens. Care Med.* 2012; 38: 458–466.
- Winck J.C., Goncalves M. H1N1 infection and acute respiratory failure: can we give non-invasive ventilation a chance? *Rev. Port. Pneumol.* 2010; 16: 907–911.
- Eryuksel E., Karakurt S., Celikel T. Non-invasive positive pressure ventilation for a severe legionella pneumonia case. *Tuberkul. Toraks. Derg.* 2009; 57: 348–351.
- Conti G., Costa R. Noninvasive ventilation in patients with hypoxic, non hypercapnic acute respiratory failure. *Clin. Pulm. Med.* 2011; 18: 83–87.
- Corrado A., Roussos C., Ambrosino N. et al. Respiratory intermediate care units: a European survey. *Eur. Resp. J.* 2002; 20: 1343–1350.