

**Michael Anderson<sup>1</sup>, Tomasz J. Kuźniar<sup>2</sup>**<sup>1</sup>Department of Medicine NorthShore University HealthSystem, Evanston, IL, USA

Chair: J. Khandekar, MD, PhD

<sup>2</sup>Division of Pulmonary and Critical Care Medicine, NorthShore University HealthSystem, Evanston, IL, USA

Chair: D. W. Ray, MD, PhD

## Pulmonary nocardiosis in a patient with chronic obstructive pulmonary disease — case report and literature review

### Nokardioza płucna u pacjenta z przewlekłą obturacyjną chorobą płuc — opis przypadku i przegląd literatury

No financial disclosure was reported by the author.

#### Abstract

Nocardiosis is an infrequent but potentially serious pulmonary infection that typically affects patients with immune suppression or structural lung disease. We report a case of a 70-year-old patient with chronic obstructive pulmonary disease (COPD) treated with inhaled steroids, theophylline, short-acting beta-agonists and anticholinergics, and long-term oxygen therapy, who presented with non-resolving pneumonia. Following a diagnosis of nocardiosis, made based on sputum culture, the patient was treated with trimethoprim/sulphamethoxazole and then, due to treatment side effects, with minocycline. We review the literature data on nocardiosis in COPD patients.

**Key words:** COPD, nocardiosis, pneumonia**Pneumonol. Alergol. Pol. 2012; 80, 6: 565–569**

#### Streszczenie

Nokardioza jest rzadkim, lecz potencjalnie ciężkim zakażeniem płuca, zwykle występującym u chorych z niedoborami odporności lub z zaburzeniami struktury płuc. Przedstawiamy opis przypadku 70-letniej chorej z przewlekłą obturacyjną chorobą płuc (POChP) leczoną przewlekłe kortykosterydami wziewnymi, teofiliną, krótko działającymi beta-mimetykami i antycholinergicami oraz tlenoterapią domową, która zgłosiła się z powodu opornego na leczenie zapalenia płuc. Rozpoznanie nokardiozy postawiono na podstawie posiewu płwociny, a następnie chorą leczono trimetoprimem/sulfametoksazolem i ze względu na pojawienie się działań niepożądanych, minocykliną. Przedstawiamy dane literaturowe dotyczące występowania nokardiozy u chorych na POChP.

**Słowa kluczowe:** POChP, nokardioza, zapalenie płuc**Pneumonol. Alergol. Pol. 2012; 80, 6: 565–569**

#### Introduction

Nocardiosis is an acute, subacute, or chronic bacterial infection that is typically acquired through inhalation and usually presents with pulmonary, central nervous system (CNS), and cutaneous manifestations [1, 2]. In the lung, *Nocardia* may

cause pulmonary nodules, infiltrates, cavitation, or pleural effusion [2]. Nocardiosis is more likely to affect people who are immunosuppressed or have underlying lung disease. We report a case of nocardiosis in a patient with chronic obstructive pulmonary disease (COPD), who presented with a non-resolving pneumonia.

**Corresponding author:** Tomasz J. Kuźniar, MD, PhD; Pulmonary and Sleep Medicine Consultant, Department of Internal Medicine, 4<sup>th</sup> Clinical Military Hospital ul. Weigla 5, 53–114 Wrocław, tel.: (71) 766 03 65, fax: (71) 766 05 99, e-mail: tk@medycyna-snu.plPraca wpłynęła do Redakcji: 21.11.2011 r.  
Copyright © 2012 Via Medica  
ISSN 0867–7077

### Case report

A 70-year-old female with severe COPD (stage IV according to GOLD based on the FEV<sub>1</sub> of 39% of predicted and chronic respiratory failure, on long-term home oxygen therapy for three years) and peripheral vascular disease, manifested by intermittent claudication, presented to the hospital with shortness of breath and chest tightness. The patient was discharged from the hospital earlier in the day after being hospitalized for 4 days for a COPD exacerbation. She had been treated with supplemental oxygen, albuterol-ipratropium nebulizers, methylprednisolone, and levofloxacin. Her symptoms improved but recurred after she had arrived home. On admission, she denied fever, chills, sweating, palpitations, cough, and nausea; other organ systems were reviewed and negative.

The patient had not had any other medical problems or any prior surgeries. She was an ex-smoker of 32 pack-years, quit smoking 25 years ago, and denied alcohol and illicit drug use. She had been retired for 20 years after working as a waitress and a manager of an ice cream shop. Over the prior 6 months she had only had one admission for COPD exacerbation. Environmental hazards included a recent month-long exposure to dust while preparing for a garage sale. At the time of admission the patient was taking a prednisone taper (current dose of 60 mg), levofloxacin 500 mg daily, fluticasone inhaler 44 mcg 2 puffs twice a day, theophylline 300 mg every eight hours, montelukast 10 mg every day, albuterol inhaler 2 puffs every 6 hours as needed, albuterol-ipratropium inhaler 2 puffs every 6 hours as needed, aspirin 81 mg every day, and cilostazol 100 mg tab twice a day.

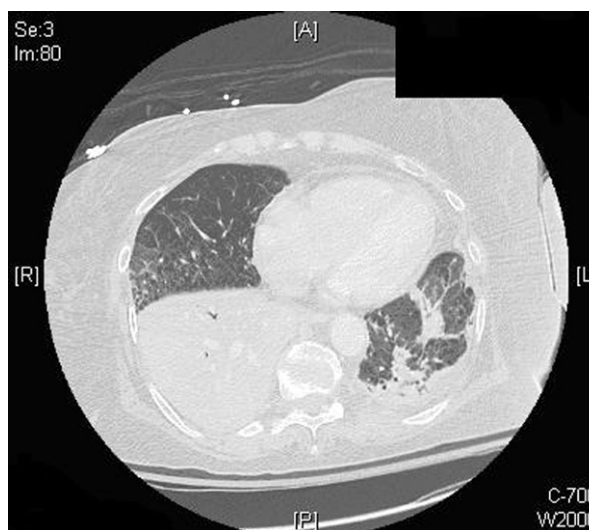On physical examination she was tachycardic and her other vital signs were normal, she was normoxemic (92%) while receiving supplemental O<sub>2</sub> at 5 L/min, and had coarse breath sounds and wheezing. Laboratory exams were normal with the exception of elevated serum bicarbonate of 31 mM/L. EKG showed sinus tachycardia, and the chest X-ray demonstrated a right lower zone infiltrate.

For presumed COPD exacerbation, the patient received supplemental oxygen and albuterol-ipratropium nebulizer every 4 hours while awake. Prednisone dose was maintained at 60 mg daily and she continued to take levofloxacin (for a total of 7 days), fluticasone, theophylline, and montelukast. She was started on enoxaparin 40 mg subcutaneously every day for prophylaxis for deep vein thrombosis.

Five days after admission, the patient experienced a sudden onset of fever of 38.7°C, associa-

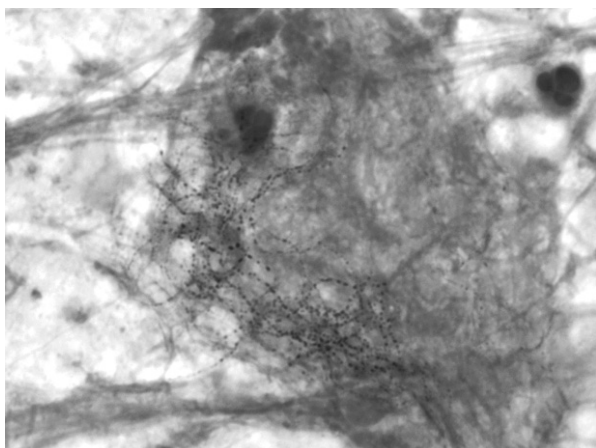
ted with tachycardia to 123/min, and worsened hypoxemia requiring O<sub>2</sub> supplementation at 50%. Physical exam at that time showed bibasilar crackles. Her WBC increased to  $17 \times 10^3/\text{mm}^3$  with neutrophilic predominance (82%) and arterial blood gas showed a pH of 7.37, pO<sub>2</sub> 74 mm Hg, and pCO<sub>2</sub> 60 mm Hg. Chest X-ray showed progression of bibasilar infiltrates with possible pleural effusion. Chest CT showed a dense right lower lobe consolidation and a less prominent left lower lobe infiltrate (Fig. 1). Sputum Gram stain and culture were obtained, and vancomycin with piperacillin-tazobactam were started for a suspected healthcare-associated pneumonia.

Sputum gram stain showed gram-positive branching rods, suspicious for *Nocardia* species (Fig. 2), which was later confirmed in culture as *N. asteroides*. Antibiotics were switched to trimethoprim-sulphamethoxazole IV 5 mg/kg every 8 hours. The patient was discharged with a diagnosis of pulmonary nocardiosis and took trimethoprim/sulphamethoxazole 800/160 mg 2 tabs 3 times a day with the plan to continue this therapy for 3 months. The patient improved clinically, but she developed urticaria on the chest, abdomen, back, and extremities after about 1 month of therapy. At this point, her therapy was switched to minocycline 100 mg twice a day for an additional two months. No follow-up CT chest was performed, but a chest X-ray 4 months later showed resolution of right lower lobe pneumonia. She continued to use home oxygen therapy.



**Figure 1.** Computed tomography of the chest, showing a dense right lower lobe infiltrate and a less prominent left lower lobe infiltrate

**Rycina 1.** Tomografia komputerowa klatki piersiowej — zagęszczenia miąższowe w płatach dolnych prawym i lewym



**Figure 2.** Gram stain of sputum, showing filamentous, Gram-positive branching rods, typical for *Nocardia*

**Rycina 2.** Barwienie płwocyny metodą Grama — Gram-dodatnie rozgałęzione strzępki, typowe dla *Nocardia*

## Discussion

*Nocardia spp.* are ubiquitous bacteria that are present in the soil, but also in long-standing dust, sand, and stagnant water. Pulmonary nocardiosis is rare; in the US, the estimated annual incidence is 500 to 1000 cases [3]. It can take forms of acute, subacute, or chronic infection that is acquired by inhalation, and has a high likelihood for exacerbations and remissions [2]. Clinically, patients present with cough (77%), fever (74%), sputum (65%), dyspnoea (65%), chest pain (39%), and less frequently with haemoptysis and abdominal pain [2]. Radiographic findings are variable and non-specific and have included a small nodule, bilateral infiltrates, cavitation, upper lobe disease, pleural effusions, and bony erosions. There is a propensity to have neurological involvement as up to 25% of nocardiosis cases involve the CNS, manifesting as altered mental status, headache, and/or neck stiffness.

*Nocardia* infections rarely affect an immunocompetent host with no pulmonary pathology; they are more likely to present in patients who are immunocompromised, have structural lung disease, especially chronic obstructive pulmonary disease (COPD), or have a history of surgery or trauma [4]. Other risk factors include corticosteroid use, underlying malignancy, transplantation, autoimmune disease, acute immunodeficiency syndrome, and intravenous drug abuse. In a large series of cases, specific risk factors were present in 94% of patients with nocardiosis, with the most common being corticosteroid use and immunosuppressive treatment [2]. Therefore, in any patient with pneu-

monia who is not improving on standard antibiotics, *Nocardia* should be considered, especially if the above risk factors are present [5, 6].

In patients with COPD, bacterial colonization of the lower airways alters ciliary motility and causes epithelial damage, which facilitates the presence of *Nocardia*; underlying structural lung disease and long-term immunosuppressive effects of corticosteroids are additional risk factors in this patient population [4]. In our literature review, we have identified 14 reports and 75 patients with a dual diagnosis of COPD and nocardiosis (Tab. 1). In the studies that reported corticosteroid therapy (including our case report), 36 of 57 patients (63.2%) were on steroid therapy for 21 days to 5 years prior to the diagnosis of nocardiosis. Most cases reported predisposing factors in addition to COPD and steroid therapy, which included bronchiectasis, pulmonary fibrosis, pneumoconiosis, silicosis, aspergillosis, human immunodeficiency virus (HIV) infection, and malignancy.

Diagnosis of nocardiosis is most frequently based on sputum cultures. If the patient cannot expectorate, then a bronchoscopy can be performed to collect a respiratory sample. Sputum cultures are positive in approximately 90% of cases; diagnostic yield can be as high as 100% for bronchoalveolar lavage and/or transbronchial lung biopsy [7]. In immunosuppressed patients, a positive sputum culture is more likely to indicate disease rather than colonization, so these patients must be treated [8]. *Nocardia* grows slowly (5–21 days) on a variety of aerobic media and is partially acid-fast.

Treatment usually involves a sulphonamide-containing regimen such as trimethoprim-sulphamethoxazole (TMP-SMX); as sulpha allergies are fairly common, effective alternatives include minocycline, amoxicillin-clavulanate, carbapenems, amikacin, cefuroxime, and ceftriaxone. Inhaled antibiotics (aminoglycosides) have proven to be effective for pulmonary nocardiosis without the risk of systemic toxicity [9]. In addition to sulpha allergies, alternatives may be chosen due to increasing resistance to TMP-SMX; testing for drug sensitivities is therefore strongly recommended. Duration of therapy may vary from 3 to 12 months based on the patient's clinical response.

Mortality of pulmonary nocardiosis has been as high as 38.7% in one report, which has been consistent with other studies [2]. This high mortality likely reflects the frail condition of the patients it affects, the difficulty in establishing the diagnosis, and incomplete response to treatment. In disseminated disease, the mortality rate may reach

**Table 1. Literature review of reports of COPD and nocardiosis; FEV<sub>1</sub> — forced exhaled volume in one second; \*NR — not reported, w/— with****Tabela 1. Przegląd literatury dotyczącej występowania nocardiozy u chorych na POChP; FEV<sub>1</sub> — nasiloną objętość wydechowa 1-jednosekundowa; \*NR — brak danych; w/— ze współistnieniem**

Authors	Number of patients	Severity of COPD (FEV <sub>1</sub> in L or as % predicted)	Oral steroid dose (in mg of prednisone)	Duration of steroid therapy	Inhaled steroids (yes/no)	Other predisposing factors	Reference
Aide et al. (2008)	1	41.2%	Only in acute exacerbation	None	Y (4 years)	Bronchiectasis	[3]
Hui et al. (2003)	10	NR	5 mg–50 mg range	Months-years	NR	2 w/Bronchopulmonary Aspergillosis 1 w/Bronchiectasis 1 w/Bronchiectasis & Neutropenia 1 w/Pulmonary Fibrosis 1 w/Pulmonary Fibrosis & Lung Cancer 1 w/metastatic colon cancer 1 w/Lymphoma	[10]
Lederman et al. (2004)	1	NR	PO & IV for acute exacerbation	NR	NR	Breast Cancer	[4]
Mari et al. (2001)	6	0.56–1.12 L	Average 13 mg/d w/range 7.5–25 mg in 4 patients	2–5 yrs	NR	Pneumoconiosis in 1 patient	[11]
Maraki et al. (2009)	2	NR	NR	NR	NR	1 pt w/renal transplant/ /immunosuppressant 1 pt on steroids for rheumatoid arthritis	[12]
Martinez-Tomas et al. (2007)	7	NR	4 total on steroids (1 on 30 mg daily for 21 days & 2 on taper for 21 days & 1 mo, respectively)	Refer to prev cell	Y	1 pt w/silicosis	[2]
Menendez et al. (1997)	3	NR	1 pt on 30 mg	21 days	NR	1 w/Bronchiectasis	[7]
Minero et al. (2009)	8	NR	5 pts w/median of 20 mg	Median of 2 months	NR	1 w/Astrocytoma 1 w/Invasive Aspergillosis 1 w/Rheumatoid arthritis 1 w/Ankylosing Spondylitis	[13]
Munoz et al. (2007)	19	NR	9 pts on steroid therapy	NR	NR	1 w/lupus and diabetes 1 w/HIV 2 w/lymphoma 1 w/HIV & solid neoplasm 1 w/solid neoplasm 2 w/rheumatoid arthritis	[14]
Pelaez et al. (2009)	1	0.53 L	12.5 mg	20 months	NR	None	[15]
Tuo et al. (2008)	9	NR	NR	NR	NR	1 w/Pneumoconiosis	[16]

64%, with the rate in the presence of CNS involvement being 100% [2]. Therefore, patients who develop pulmonary nocardiosis should be assessed for disseminated nocardiosis with blood cultures and brain imaging, either head CT or brain MRI. Cerebro-spinal fluid analysis should be performed if meningitis is suspected and there is no mass effect seen with brain imaging. Other diagnostic methods that may be required are biopsy of skin lesions and aspiration of abscesses.

### Conflict of interest

The authors report no conflict of interest.

### Piśmiennictwo

1. Hidri N., Farina C., Szponar B. et al. Nocardia and human nocardiosis. *Pneumonol. Alergol. Pol.* 2001; 69: 677–686.
2. Martinez Tomas R., Menendez Villanueva R., Reyes Calzada S. et al. Pulmonary nocardiosis: risk factors and outcomes. *Respirology* 2007; 12: 394–400.
3. Aide M.A., Lourenco S.S., Marchiori E., Zanetti G., Mondino P.J. Pulmonary nocardiosis in a patient with chronic obstructive pulmonary disease. *Am J Respir Crit Care Med* 2004; 170: 1000–1002.

- tive pulmonary disease and bronchiectasis. *J. Bras. Pneumol.* 2008; 34: 985–988.
4. Lederman E.R., Crum N.F. A case series and focused review of nocardiosis: clinical and microbiologic aspects. *Medicine.* 2004; 83: 300–313.
  5. Menendez R., Perpina M., Torres A. Evaluation of nonresolving and progressive pneumonia. *Semin. Respir. Inf.* 2003; 18: 103–111.
  6. Fein A.M., Feinsilver S., Niederman M.S. Slow resolving pneumonia in the elderly. Niederman M.S., Raven Press, New York 1991: 293.
  7. Menendez R., Cordero P.J., Santos M., Gobernado M., Marco V. Pulmonary infection with *Nocardia* species: a report of 10 cases and review. *Eur. Respir. J.* 1997; 10: 1542–1546.
  8. Filice G.A. Nocardiosis. Niederman M.S., Sarosi G.A., Glassroth J., Lippincott Williams and Wilkins, Philadelphia 2001: 457–466.
  9. O'Riordan T.G. Inhaled antimicrobial therapy: from cystic fibrosis to the flu. *Respir. Care.* 2000; 45: 836–845.
  10. Hui C.H., Au V.W., Rowland K., Slavotinek J.P., Gordon D.L. Pulmonary nocardiosis re-visited: experience of 35 patients at diagnosis. *Respir. Med.* 2003; 97: 709–717.
  11. Mari B., Monton C., Mariscal D., Lujan M., Sala M., Domingo C. Pulmonary nocardiosis: clinical experience in ten cases. *Respiration* 2001; 68: 382–388.
  12. Maraki S., Scoulica E., Nioti E., Tselentis Y. Nocardial infection in Crete, Greece: review of fifteen cases from 2003 to 2007. *Scand. J. Inf. Dis.* 2009; 41: 122–127.
  13. Minero M.V., Marin M., Cercenado E., Rabadan P.M., Bouza E., Munoz P. Nocardiosis at the turn of the century. *Medicine* 2009; 88: 250–261.
  14. Munoz J., Mirelis B., Aragon L.M. et al. Clinical and microbiological features of nocardiosis 1997–2003. *J. Med. Microbiol.* 2007; 56: 545–550.
  15. Pelaez A.I., Garcia-Suarez M.del M., Manteca A. et al. A fatal case of *Nocardia* otitidis caviarum pulmonary infection and brain abscess: taxonomic characterization by molecular techniques. *Ann. Clin. Microbiol. Antimicrobials.* 2009; 8: 11.
  16. Tuo M.H., Tsai Y.H., Tseng H.K., Wang W.S., Liu C.P., Lee C.M. Clinical experiences of pulmonary and bloodstream nocardiosis in two tertiary care hospitals in northern Taiwan, 2000–2004. *J. Microbiol. Immunol. Infection.* 2008; 41: 130–136.