

Piotr Grzelak¹, Łukasz Augsburg¹, Agata Majos¹, Ludomir Stefańczyk¹, Paweł Górski²,
Wojciech Piotrowski², Adam Antczak²

¹Department of Radiology and Diagnostic Imaging, Medical University of Lodz, Poland
Head: Prof. L. Stefańczyk, MD, PhD

²Department of Pulmonology Medical University of Lodz, Poland
Head: Prof. P. Górski, MD, PhD

Diagnostic potential of contrast-enhanced ultrasound (CEUS) in the assessment of spleen and liver granulomas in the course of sarcoidosis

Potencjał diagnostyczny ultrasonografii wzmocnionej kontrastem w ocenie guzków wątroby i śledziony w przebiegu sarkoidozy

The Authors declare no financial disclosure.

Abstract

Introduction: The aim of this study was to analyze the diagnostic potential of contrast enhanced ultrasound (CEUS) for the recognition of focal lesions of the spleen and liver in patients suffering from sarcoidosis.

Material and methods: We analyzed the outcome of diagnostic imaging in a group of 21 patients treated for pulmonary sarcoidosis, searching for the systemic infiltration of the liver and/or spleen. All the participants are patients with inactive disease, who are monitored every 6 months at the Pulmonology Clinic. Apart from the check-up high-resolution computed tomography (HR-CT) — every 2 years, patients underwent an initial ultrasound examination (US) and if there was a suspicion of systemic infiltration, abdominal CT and/or magnetic resonance imaging (MRI) and CEUS were performed.

Results: In 18 patients suffering from pulmonary sarcoidosis diagnostic imaging revealed no systemic infiltration. In three patients, the use of CEUS exposed the presence of lesions in the parenchymal organs. In all cases, the images from CEUS were consistent with those from CT/MRI.

Conclusions: CEUS has the potential to become a reliable and safe screening tool for systemic infiltration in patients with sarcoidosis. It may also be an important method of monitoring the effects of therapy.

Key words: sarcoidosis, contrast enhanced ultrasound, CEUS, hepatosplenic sarcoidosis, extrapulmonary sarcoidosis

Pneumonol. Alergol. Pol. 2013; 81: 424–428

Streszczenie

Wstęp: Celem pracy była analiza potencjału diagnostycznego ultrasonografii wzmocnionej kontrastem (CEUS) w wykrywaniu zmian ogniskowych w wątrobie i śledzionie u pacjentów cierpiących z powodu sarkoidozy.

Materiał i metody: Przeanalizowano wyniki badań obrazowych w grupie 21 pacjentów leczonych z powodu postaci płucnej sarkoidozy, poszukując cech zajęcia wątroby i śledziony. Wszyscy uczestnicy to pacjenci w stadium nieaktywnej choroby, którzy są monitorowani co 6 miesięcy w Klinice Pulmonologii i Alergologii. Oprócz wykonywanego co 2 lata HRCT (*high-resolution computed tomography*) pacjentów poddano wstępnemu badaniu ultrasonograficznemu brzucha i jeżeli istniało podejrzenie sarkoidozy systemowej, zlecano tomografię komputerową jamy brzusznej i/lub rezonans magnetyczny oraz CEUS.

Corresponding address: Łukasz Augsburg, MD, PhD, Department of Radiology and Diagnostic Imaging University Teaching Hospital No. 1, ul. Kopcińskiego 22, 90–159 Łódź, tel. +48 42 678 67 34, e-mail: lucas.augsburg@wp.pl

Praca wpłynęła do Redakcji: 27.08.2012 r.

Copyright © 2013 PTChP

ISSN 0867–7077

Wyniki: U 18 pacjentów z postacią płucną sarkoidozy wyniki badań obrazowych nie wykazały zajęcia narządów mięszzowych. U 3 pacjentów użycie CEUS pozwoliło na wykrycie zmian w wątrobie i śledzionie, co potwierdziły badania TK i/lub RM.

Wnioski: CEUS ma potencjał, aby stać się bezpiecznym i niezawodnym narzędziem przesiewowym w poszukiwaniu zmian systemowych u pacjentów z sarkoidozą. Może być również skuteczną metodą monitorowania efektów terapii.

Słowa kluczowe: sarkoidoza, sarkoidoza śledziony i wątroby, CEUS, ultrasonografia wzmocniona kontrastem

Pneumonol. Alergol. Pol. 2013; 81: 424–428

Introduction

Sarcoidosis is a multisystemic granulomatous disease of unknown etiology that predominantly affects the lungs and intrathoracic lymph nodes, rarely (about 10%) the infiltration of spleen and liver, can be observed. The early detection of organ lesions in course of sarcoidosis is crucial, as it changes the classification of the disease and treatment strategy, thus influencing the long-term results of therapy. Unfortunately, the infiltration of abdominal organs is usually asymptomatic — delaying diagnosis [1].

HRCT is currently the standard diagnostic tool for monitoring patients with pulmonary sarcoidosis. In cases of organ involvement localized subdiaphragmatically, CT/MRI of the abdomen and different ultrasound techniques (presentation B, Color and Power Doppler US etc.) are performed. MRI is already well established in this algorithm as a safe, accurate and reliable method, but its wide use is limited. Therefore there is a need to find new, sufficiently sensitive and noninvasive methods to screen for systemic sarcoidosis. Contrast-enhanced ultrasonography (CEUS) for that matter reduces the risk of complications associated with the use of iodine contrast and does not produce harmful radiation. Consequently, the implementation of contrast-enhanced ultrasound opens new perspectives for the detection of abdominal lesions in sarcoidosis.

The purpose of this study was to analyze the diagnostic potential of CEUS for the recognition of focal lesions of the spleen and liver, in patients suffering from sarcoidosis.

Material and methods

Study group consisted of 21 patients suffering from chronic pulmonary sarcoidosis. The subjects included 13 women and 8 men, with the mean age 38 years (range 28–47 years, SD 5.5). If there was a suspicion of systemic infiltration (elevated liver enzymes, fever, abdominal pain,

lymphadenopathy, liver/spleen enlargement or heterogeneity on initial US) patient was referred to the Radiology Department, where the following diagnostic pathway was introduced:

1. Standard US examination (B presentation, US-Color Doppler, US-Power Doppler).
2. Abdominal CT and/or MRI (CT only — 10; MRI only — 8; CT and MRI — 3).
3. CEUS.

Patients were monitored at the Pulmonology Department every 6 months, where these procedures were performed on an outpatient basis. If the diagnostic imaging outcome was positive the patient was subjected to a biopsy (only in case of liver lesions). The risks, benefits, and possible complications were explained to the patient prior to the procedures. Informed consent was obtained before commencement of data collection.

Dynamic MRI was conducted using Siemens-Avanto scanner (Siemens, Erlangen, Germany) with the contrast protocol – ProHance (Bracco Int. Milan, Italy). CT scan was performed using GE-Light-Speed 64 scanner (GE Healthcare, Buc, France) with 4-phase contrast protocol — Iomeron 400 (Bracco Int. Milan, Italy). Ultrasound examination was performed using GE Vivid 7 (GE Healthcare, Buc, France) system with a convex transducer (type 3.5C). The study protocol included B-mode presentation and contrast-enhanced ultrasound. Acquisition using B-mode presentation included the morphological assessment of the spleen and liver - we used the factory settings dedicated to the assessment of parenchymal organs. CEUS with SonoVue Diagnostics (Bracco Int. Milan, Italy) at a dose of 2.4 ml/study, administered by intravenous bolus was the last part of the acquisition. This was performed using a protocol with a low mechanical index (MI 0.1) and the default settings dedicated to contrast studies. Data from each study was recorded in a digital form and saved as several time loops to allow analysis on an external EchoPack PACS workstation (GE Healthcare, Buc, France). By

strengthening the intensity curves (TIC), local perfusion was evaluated in defined areas (ROI). All the biopsies were conducted under the ultrasound guidance, using a standard biopsy kit. This enabled precise planning and control in real time during the procedure. The equipment, which we used, was manufactured by Bard Magnum (Bard Biopsy Systems, Tempe, USA). The biopsy needle diameter was 16G. In each case 15mm long tissue samples were collected.

The study protocol assumed, that the maximum diagnostic pathway will be no longer than 7 days. The analysis of US, CT, MRI and CEUS data, was performed independently. The same, experienced ultrasonographers, who were unaware of patient's clinical background, performed all ultrasound examinations.

Results

In 18 patients suffering from pulmonary sarcoidosis diagnostic imaging revealed no systemic infiltration. In 3 patients, the use of CEUS and CT or/and MRI exposed the presence of lesions in the parenchymal organs: in case 1 — numerous lesions of the spleen (Figs 1, 2), in case 2 and 3 — few lesions of the liver (Figs 3, 4). In all 21 cases, the images from CEUS and CT/MRI were consistent. The cytological results for the patients with liver infiltration (case 2 and 3) who underwent core needle biopsy revealed the presence of non-caseating granulomas, which confirmed the diagnosis of systemic sarcoidosis. Biopsy was not performed in case 1 (spleen lesions) due to a high risk of bleeding. Data are summarized in Table 1.

Discussion

Early detection of lesions in patients suffering from sarcoidosis affects the treatment strategy and improves prognosis. Respiratory involvement frequently presents as cough and dyspnoea whereas liver and spleen infiltration may be asymptomatic. Manifestations such as abdominal pain, portal hypertension, pancytopenia, spleen capsule rupture are observed in only 2–5% cases of hepatosplenic sarcoidosis [2].

On CT and MRI, small nodules in the liver and spleen are often invisible – this is the reason why despite the development of imaging techniques, a liver biopsy is still the diagnostic gold standard. In cases of a seemingly normal liver image on CT and MRI, a biopsy revealed the presence of nodules in

40–70% of cases [3, 4]. Similar dissonance can be observed at autopsy, where the extra-pulmonary form is recognized more often than is diagnosed based on the current routinely used, imaging methods. The biopsy is still regarded as the reference method for the diagnostic imaging. For the liver this procedure is considered to be safe, with occasional complications. This is different when it comes to a biopsy of the spleen, which is a procedure burdened with considerable risk of bleeding and therefore not recommended. Spleen sarcoidosis, although not uncommon, is also difficult to confirm solely in diagnostic imaging [5].

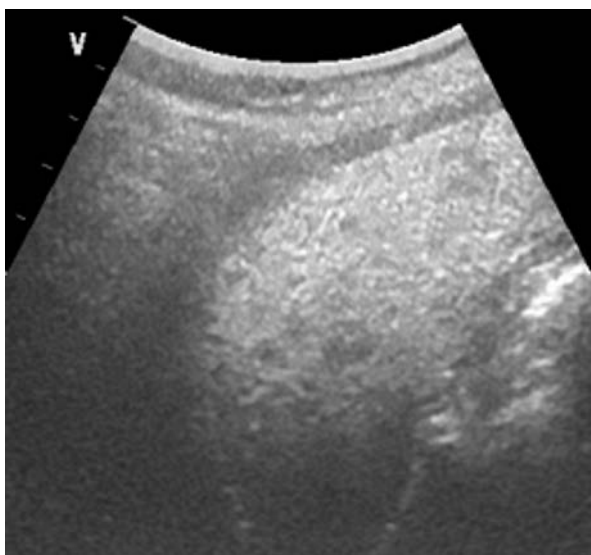


Figure 1. Case 1. 41 year old woman, CEUS images. After administration of contrast the numerous, small, well-limited nodules in the spleen are visible

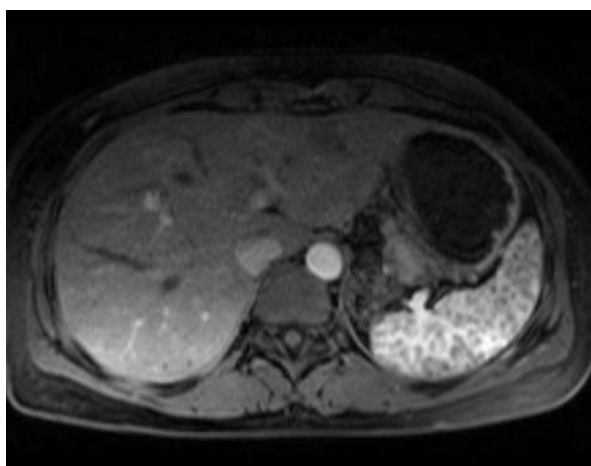


Figure 2. Case 1. 41 year old woman, MRI images. After administration of contrast the numerous, small, well-limited nodules in the spleen are visible

Due to the invasive nature of the biopsy and the risk of significant complications, we are looking for different diagnostic tools that are less invasive and have fewer contraindications. CT and MRI are good diagnostic methods, but in some cases they are contraindicated (CT — contrast allergy, MRI — claustrophobia, pacemakers, metallic foreign bodies). The use of a contrast agent to visualize focal lesions in parenchymal organs is an imaging diagnostic standard in CT and MRI [6]. The administration of a contrast agent is burdened with, sometimes

severe complications related to the contrast medium, which eliminates them from diagnostic screening and limits their use in systemic sarcoidosis monitoring. The great advantage

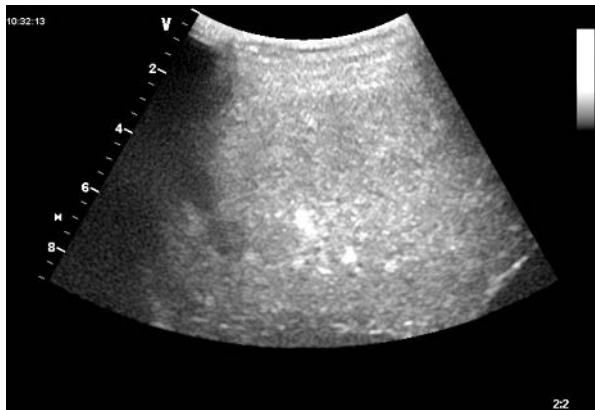


Figure 3. Case 2 — 46 year old man. CE-US images. After administration of contrast the two small, well demarcated nodules in the segment VIII are visible

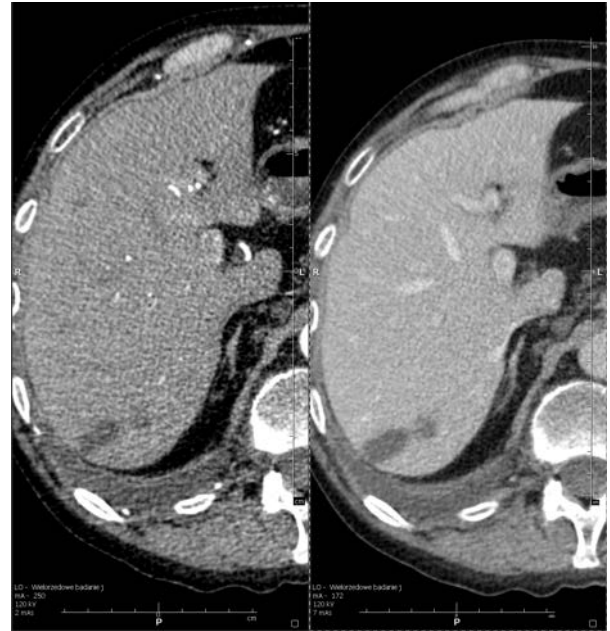


Figure 4. Case 2 — 46 year old man. CT images after administration of contrast. On the left side — the arterial phase, on the right side — the venous phase. The two small, well demarcated nodules in the segment VIII are visible in both phases

Table 1. Results

N°	Sex/ Age	Clinical data	Methods	Outcome
1	♀/41	Sarcoidosis for 10 years, initial US (B-mode) — normal liver image; enlarged, heterogenous spleen, no focal lesions	MRI CEUS	Enlarged spleen with numerous, small, low-signal nodules, diam. 10–12 mm. Liver was homogenous and not enlarged (Fig. 2) Numerous hypoechoic lesions in the spleen, diam. 10 mm (Fig. 1). Liver was homogenous and not enlarged
2	♂/46	Sarcoidosis for 12 years, initial US (B-mode) — normal spleen image; enlarged liver, no focal lesions. Liver infiltration was suspected on the basis of check-up HRCT	CT CEUS	Enlarged liver with 5 hypodense nodules diam. 5–18 mm in the right liver lobe, unenhanced after contrast administration (Fig. 4). Spleen was homogenous and not enlarged Liver — 4 hypoechoic nodules diam. 7–19 mm in the right lobe (Fig. 3). Spleen was homogenous and not enlarged
3	♀/28	Sarcoidosis for 3 years, initial US (B-mode) — normal spleen image; enlarged and heterogeneous with increased echogenicity liver without focal lesions	BA CT CEUS	<i>Presence of non-caseating granulomas</i> Enlarged liver with numerous hypodense, unenhancing lesions diam. 7–18 mm within both liver lobes. Normal spleen image Numerous hypoechoic lesions in the liver diam. 8–17 mm within both liver lobes. Normal spleen image
4-21	♀♂/28– –47	Sarcoidosis for 0–10 years. Initial US (B-mode) — in 11 cases, increased and/or heterogeneous liver, last 7 cases normal image of the spleen and liver	BA CEUS RM CT	<i>Presence of non cas-eating granulomas</i> Normal image of the spleen and liver Homogeneous image of the spleen and liver Homogeneous image of the spleen and liver

MRI — magnetic resonance imaging, CT — computed tomography, CEUS — contrast-enhanced ultrasound, BA — biopsy

of contrast media used in ultrasonography, is their safety, which has been confirmed by clinical trials [7]. Moreover, in the diagnosis of sarcoidosis it is important to eliminate the nephrotoxicity of the administered contrast.

Hepatosplenomegaly and lymphadenopathy are the most common discoveries on CT and MRI scans, whereas granulomas are rare (about 5% of cases) [8, 9]. They show up most often in the form of multiple, well demarcated, and non-enhancing (after contrast administration) nodules with a diameter of up to 0.8 mm [10, 11]. This allowed us to reach a conclusion, that sarcoid nodules in the liver and spleen, as non-vascularized structures, which do not impair surrounding vascular architecture [12], will be visualized in CEUS as a hypoechoic nodules — which was confirmed in this study. The CEUS allowed us to distinguish healthy (hyperechoic) liver and spleen parenchyma from numerous, small, avascular (hypoechoic) granulomas.

In the literature, there are first attempts to use CEUS in the diagnosis of systemic sarcoidosis. For example, a case of a 74-year-old woman, suffering from sarcoidosis, in which CEUS confirmed the presence of non-enhancing nodules in the parenchymal organs [13]. Another one is a case of 38-year-old woman with atypical pain in the left lower hemi-abdomen, in which CEUS revealed the presence of hypoechoic nodules in the liver [14]. The authors of those papers, observed a similar pattern of post-contrast behavior, as in our study.

CEUS in a clear and transparent way shows the vascular structure of focal lesions on the background of a homogeneously enhancing liver parenchyma, which allows the differentiation between them, with efficacy similar to MRI [15]. In the literature, the nature of post-contrast enhancement is widely raised as a feature differentiating focal lesions of the liver in CEUS. Focal liver lesions vary in the degree of enhancement, contrast saturation time and the phenomenon called “washout”. There are no (in this diagnostic algorithm) hypoechoic, solid, well-demarcated, non-enhancing focal lesions, and such a pattern of behavior is represented by sarcoid nodules. This feature creates the prospect of high sensitivity and specificity of CEUS in granuloma diagnostics.

Based on our observations, it seems that the main way of CEUS implementation could be searching for systemic sarcoidosis in patients already

diagnosed with pulmonary sarcoidosis (based on biopsy, HRCT, biochemical and serological tests). This method has the potential to become a reliable screening tool in these patients (replacing more expensive and less available imaging methods — MRI, CT). It also seems that CEUS could be an important method of monitoring the effects of therapy in those patients, who require treatment. CEUS has all the qualities to play an important role in the examination of lesions occurring in systemic sarcoidosis.

Conflict of interest

The Authors declare no conflict of interest.

References:

1. Lynch J.I., Baughman R., Sharma O. Extrapulmonary sarcoidosis. *Semin. Respir. Infect.* 1998;13: 229–254.
2. Statement on sarcoidosis. Joint Statement of the American Thoracic Society (ATS), the European Respiratory Society (ERS) and the World Association of Sarcoidosis and Other Granulomatous Disorders (WASOG) adopted by the ATS Board of Directors and by the ERS Executive Committee, February 1999. *Am. J. Respir. Crit. Care Med.* 1999; 160: 736–755.
3. Warshauer D.M., Dumbleton S.A., Molina P.L. et al. Abdominal CT findings in sarcoidosis: radiologic and clinical correlation. *Radiology* 1994; 192: 93–98.
4. Newman L.S., Rose C.S., Maier L.A. Sarcoidosis. *N. Engl. J. Med.* 1997; 24: 1224–1234.
5. Bilir M., Mert A., Ozaras R. et al. Hepatic sarcoidosis: clinicopathologic features in thirty-seven patients. *J. Clin. Gastroenterol.* 2000; 31: 337–338.
6. Marchal G., Vogel T.J., Heiken J.P. et al (ed.): *Multidetector — row computed tomography.* Springer Milan, Italy 2005: 79–89.
7. Piscaglia F, Bolondi L on behalf of Italian Society for Ultrasound in Medicine and Biology (SIUMB) Study Group on Ultrasound Contrast Agents. The safety of Sonovue in abdominal applications: retrospective analysis of 23188 investigations. *Ultrasound in Med. & Biol.* 2006;32: 1369–1375.
8. Kessler A., Mitchell D.G., Israel H.L. et al. Hepatic and splenic sarcoidosis: Ultrasound and MR imaging. *Abdom. Imaging* 1993; 18: 159–163.
9. Warshauer D.M., Dumbleton S.A., Molina P.L. et al. Abdominal CT findings in sarcoidosis — Radiologic and clinical correlation. *Radiology* 1994; 192: 93–98.
10. Warshauer D.M., Molina P.L., Hamman S.M. et al. Nodular sarcoidosis of the liver and spleen: analysis of 32 cases. *Radiology* 1995; 195: 757–762.
11. Spinelli K.S., Stewart E.T., Francis I.R. Radiographic manifestations of gastrointestinal and hepatobiliary sarcoidosis. *The Radiologist* 2002; 9: 125–131.
12. Warshauer D., Semelka R.C., Ascher S.M. Nodular sarcoidosis of the liver and spleen: Appearance on MR images. *J. Magn. Reson. Imaging* 1994;4: 553–557.
13. Pérez-Grueso M.J., Repiso A., Gómez R. Splenic focal lesions as manifestation of sarcoidosis: Characterization with contrast-enhanced sonography. *J. Clin. Ultrasound* 2007; 35: 405–408.
14. Stryckers M., Voet D., Vogelaers D. et al. Contrast-enhanced ultrasonography in hepatosplenic sarcoidosis. *Acta Clin. Belg.* 2011; 66: 429–431.
15. Wong G.L.-H., Xu H.-X., Xie X.-Y. Detection of focal liver lesions in cirrhotic liver using contrast-enhanced ultrasound. *World J. Radiol.* 2009; 31: 25–36.