

Internat. Marit. Health, 2008, 59, 1 - 4

PROFESSIONAL PHOTSENSITIVE ECZEMA OF FISHMEN BY CONTACT WITH BRYOZOANS: DISABLING OCCUPATIONAL DERMATOSIS

BENEDICTE CLIN, MD,^{1,2} CATHERINE STOSSE-GUEVEL, MD,¹,
MARIE-FRANCE MARQUIGNON, MD¹, LAURENCE VERNEUIL, MD³,
MARC LETOURNEUX, PhD, MD^{1,2}

ABSTRACT

Eczema associated with bryozoans is a form of occupational dermatosis caused by a living animal, involving contact eczema, occasionally associated with photosensitivity and concerning fishermen on a quasi-elective basis. This affection can prove to be extremely disabling, frequently generating disastrous social consequences, since the eviction of the responsible allergen is very often synonymous to occupational reclassification, a measure which fishermen, highly attached to their profession, have great difficulty in accepting.

¹ Occupational Health Department, Caen University Hospital, Caen, France

² Institut de recherche et de formation en santé au travail de Basse-Normandie, Caen University Faculty of Medicine, Caen, France

³ Dermatology Department, Caen University Hospital, Caen, France

Address for correspondence :

Dr Bénédicte Clin, MD

Service de Médecine du Travail et Pathologie Professionnelle,

C.H.U. Côte de Nacre 14033 CAEN Cedex – France, Tel: (33) 2 31 06 54 65

E-mail: clin-b@chu-caen.fr

Key words: Bryozoan, contact eczema, photosensitivity, occupational dermatosis, fishermen

Based on the description of three cases of photosensitive eczema associated with contact with the bryozoan, *Alcyonidium gelatinosum*, identified in fishermen from the English Channel coastline, we describe the characteristics and the specificities of this occupational dermatosis, then approach the issue of its prevention, which, unfortunately, remains limited.

INTRODUCTION

Eczema associated with bryozoans is a form of occupational dermatosis caused by a living animal, involving contact eczema, occasionally associated with photosensitivity, i.e. an abnormal reaction to sunlight. This affection follows a highly characteristic geographical distribution: The very first cases were registered within a specific area of the North Sea, referred to as « *Dogger Bank* » (1, 2, 3). Affecting workers in the fishing industry on a quasi-elective basis (predominantly fishermen), this dermatosis can prove to be extremely disabling. Unfortunately, preventive measures are currently limited and the social consequences of this occupational dermatosis can prove to be disastrous. Indeed, the only effective measure is the eviction of the responsible allergen which is very often synonymous to occupational reclassification, a measure which fishermen, highly attached to their profession, have great difficulty in accepting.

The aim of this work is to highlight, through a description of three cases of photosensitive eczema associated with contact with a bryozoan, *Alcyonidium gelatinosum* (*A. gelatinosum*) observed among fishermen working on the English Channel coast, the characteristics and the specificities of this form of occupational dermatosis. We also approach the issue of its prevention, which is often difficult to implement onboard trawlers.

CASE REPORTS

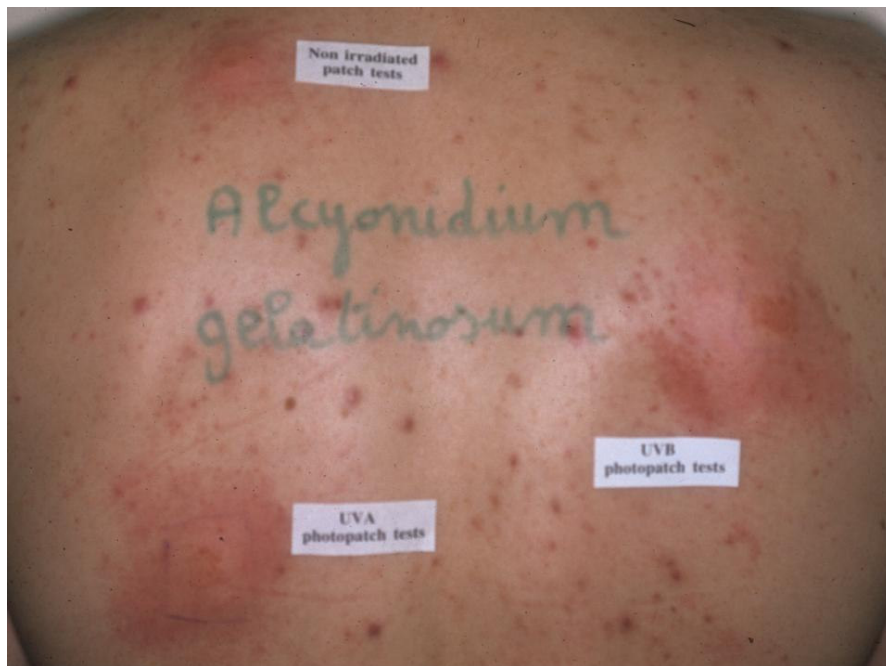Case nr1: Mr. GC

The patient is a 38-year-old fisherman treated in 2006, from the coastal town of Port-en-Bessin in Calvados, presenting, for the last ten years, with localised eczema outbreaks essentially on the face, neck, forearms and hands, progressing towards generalisation and superinfection, and requiring hospital admission. Atopy was initially

evoked and the patient was sent home with progressively decreasing doses of dermocorticosteroids.

The patient rapidly returned to work; however, unfortunately, several identical episodes occurred over the following 8 years, with a clear seasonal rhythmicity in the spring and summer. These seeping eczematous lesions, located on exposed areas (face, arms, forearms) were evocative of an airborne allergy and, in particular, an allergy to bryozoans, given the patient's profession. Questioning on professional activities confirmed that Mr. C handled fishing nets during the annual period within which he was prone to attacks.

After lesion healing, epicutaneous tests were performed, evidencing an extremely intense reaction to *Alcyonidium gelatinosum* (Fig.1a). Photobiological exploration with a solar simulator revealed severe photosensitivity. The Minimal Erythematous Dose (MED) with regard to ultraviolet B (UVB) and A (UVA) radiation was reduced: UVB MED < 27 mJ/cm² (N ≥ 50), UVA MED 14.6 J/cm² (N ≥ 25).



Positive patch and photopatch tests to *Alcyonidium gelatinosum* (case Nr 1)

A change in Mr. C's working habits was recommended, involving the suspension of net handling during the summer.

Mr. C was admitted to hospital again in the summer, for seeping eczematous lesions, essentially on the palms of the hands, with severe oedema of all fingers and dryer eczematous lesions on the wrists and forearms. Erythematous vesicular lesions were also observed on the patient's feet and on the nape of the neck. Mr. C. explained that he did not wish to stop his fishing activity during the summer period.

Case nr 2: Mr JLC

The patient is a 57-year-old fisherman working in the coastal town of Ouistreham in Calvados. He was hospitalised in 1982 for localised eczema on the face, upper chest and back of the hands. His eczema is extremely pruriginous with psoriasiform lesions on the elbows. The patient has explained that he has suffered from these lesions over the past 4 years, and that they always occur during the summer.

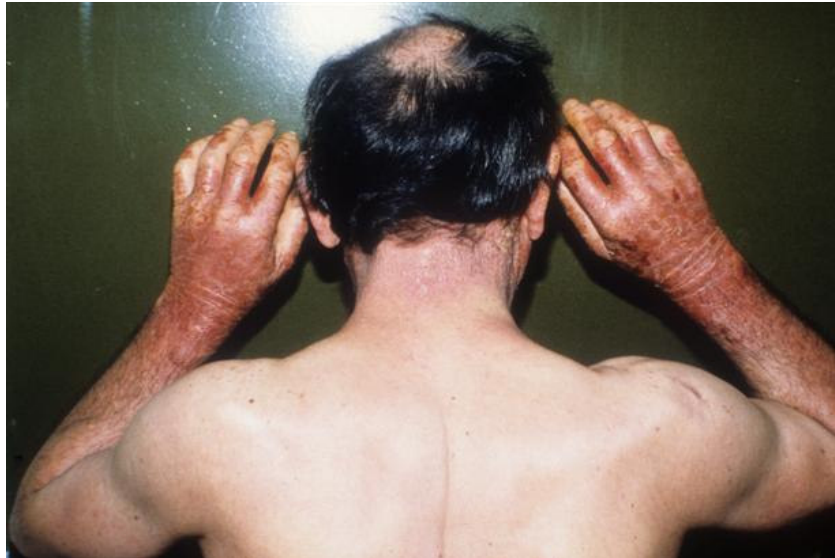They are associated with photosensitivity since the UVA MED and UVB MED are under normal values.

Epicutaneous tests with *Alcyonidium gelatinosum* are positive. Occupational dermatosis associated with contact with bryozoan has been diagnosed.

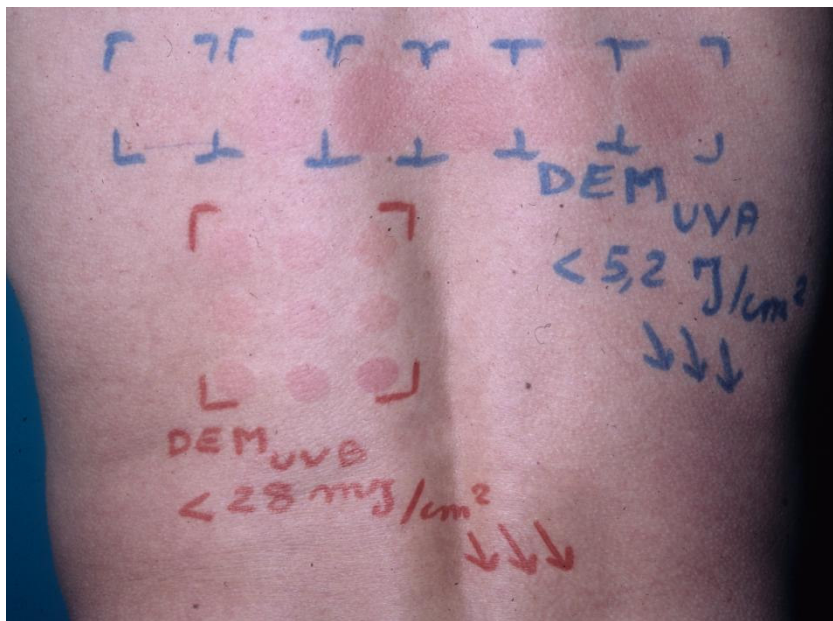
Case nr. 3: Mr PC

Mr. PC is a 54-year-old sailor treated in 1987, in the region of Le Havre, a port in Seine Maritime, regularly fishing with lobster pots and nets, and presenting with localised eczema on the face and forearms (Fig.1b). Attention was drawn to the chronology of symptoms, clearly influenced by the patient's professional activity. Severe photosensitivity was observed, since the UVB MED (<28 mJ/cm²) and the UVA MED (< 5.2 J/cm²) were extremely low (Fig. 1c). Epicutaneous tests with *Alcyonidium gelatinosum* were highly positive.

This patient temporarily ceased all fishing activity during the summer months and his symptoms disappeared. However, they have recurred since he has resumed fishing.



Eczema on sun-exposed areas (neck, forearms and hands). Case Nr 3.



Photosensitivity evidenced by UVA and UVB MED under normal values. Case Nr 3.

DISCUSSION

Bryozoans are invertebrates, also referred to as « moss animals », which are essentially marine organisms, with no connection with algae. Around 4,000 species have currently been identified, forming colonies of thousands of individual organisms measuring less than a millimetre, as fucus epifauna or encrusted on solid substrates (rocks, pebbles, shells).

Torn from the sea bed by fishing nets, they fix onto mineral or organic surfaces and proliferate during the summer season, benefiting from a temperature range of 8° to 22°. Four pathogenic species are the most frequently responsible for the type of contact eczema described in our study: *Alcyonidium gelatinosum*; *Alcyonidium hirsutum*; *Electra pilosa* and *Flustra foliacea*.

From 1930 onwards, an increasing number of cases of eczema were reported, very probably linked to contact with a bryozoan (*A. hirsutum*), among fishermen from the Danish port of Esbjerg. In 1948, Bonnevie (1) conducted the first epidemiological studies and demonstrated, thanks to patch-tests, the role of *A. hirsutum* in contact eczema occurring among fishermen. He named this particular type of eczema, « *Dogger Bank Itch* », due to its geographical origin in a North Sea zone known as « *Dogger Bank* » (2, 3, 4).

Bryozoans-associated eczema

Eczema associated with contact with bryozoans is a contact allergy, initially localised in exposed zones in direct, handborne or airborne contact. Sensitisation occurs during fishing net handling (trammel or bottom trawl nets). Thorough questioning, together with epicutaneous tests performed with sea water collected within the fishing area and/or with bryozoans gathered in the same area, frequently reveal the allergens responsible for such dermatoses.

In 1982, Carle J.S. and Christophersen C. isolated and identified the hapten as (2-hydroxyethyl) dimethylsulfoxonium ion (5).

Although recovery is generally made within a few weeks of eviction of the allergen, progression towards exogenic photosensitivity can also be observed (6). Indeed, the patients described above presented with photosensitivity, which was confirmed by photobiological exploration. Among photosensitive patients, eczema may recur at each exposure to sunlight, or even progress towards chronicity with further outbreaks not involving exposure to bryozoans. Such cases are referred to as chronic actinic dermatitis (CAD), a term which has replaced many previous names, « photosensitive eczema », « actinoreticulosis » and « remnant photosensitivity syndrome » (7). CAD can be distinguished by the presence of localised eczema, particularly in photo-exposed

areas with extreme photosensitivity to ultraviolet rays, but also to visible rays. This type of disease progression is illustrated in observation n°3.

As for all phenomena of allergic origin, the only efficient preventive measure is the total and permanent eviction of the allergen. Such measures are all the more difficult to implement, given that catches are more abundant precisely within zones where bryozoans thrive.

Technical prevention of occupational contact eczema associates, on the one hand, collective measure: limiting exposure through appropriate work organisation (work in kitchens, in the hold). On the other hand, individual measures can be applied: the use of warm, yet lightweight polyurethane clothing is recommended (8), including a jacket and trousers, together with neoprene gloves that can be tucked inside the elastic jacket sleeves, hence proffering improved watertightness and avoiding the possible occurrence of irritant dermatitis caused by sleeves rubbing on the wrists. Unfortunately, such clothing is airtight, very warm and difficult to wear during the summer season. Furthermore, gloves alone only provide temporary protection since sea water rapidly penetrates inside, exacerbated by the rapid presence of punctures (due, in particular, to the presence of small crabs, shells). Applications of sun cream with an UVA-UVB protection factor of 50 is also a recommended protective measure; however the surrounding dampness necessitates frequent reapplication.

CONCLUSION

Photosensitive eczema associated with contact with bryozoans represents a typical nosological entity in its clinical forms, as much in terms of its localisation as its seasonal rhythm. It is a particularly disabling form of dermatosis, for which preventive measures remain, unfortunately, limited. The creation of new health care modalities for occupational diseases among seafarers, together with a census of observed cases of dermatosis, should provide a precise indication of their incidence and their prevalence, for which very little data is currently available.

ACKNOWLEDGEMENTS

To Professor Dominique LEROY (Dermatology Department, Caen University Hospital, Caen, France), for his precious and cordial assistance.

REFERENCES

1. Bonnevie P. Fishermen's "Dogger Bank itch": an allergic contact-eczema due to the coralline *Alcyonidium hirsutum*, the "sea-chervil". *Acta allergologica* 1948;1:40-46.
2. Fraser JH, Lyell A. Dogger Bank Itch. *Lancet* 1963;5(1):61.
3. Newhouse ML. Dogger Bank Itch: survey of trawlermen. *Br Med J*. 1966;1(5496):1142-1145.
4. Pathmanaban ON, Porter JS, White IR. Dogger Bank itch in the eastern English Channel: a newly described distribution of an old problem. *Clin Exp Dermatol*. 2005; 30(6):622-626.
5. Carle JS, Christophersen C. Dogger Bank Itch (4). An eczema-causing sulfoxonium ion from the marine animal, *Alcyonidium gelatinisum* (Bryozoa). *Toxicon*. 1982; 20(1):307-310.
6. Leroy D, Domp martin A, Lauret P, Bouillie MC, Audebert C. Allergic contact dermatitis to Bryozoa and photosensitivity. *Photodermatol*. 1988;5:227-229.
7. Hawk JL. Chronic actinic dermatitis. *Photodermatol Photoimmunol Photomed*. 2004;20(6):312-314.
8. Newhouse ML. Protective clothing for fishermen. Section of occupational medicine, 1966. *Proc. Roy.Soc.Med*. 1970, 63, p. 1005.