

Preliminary metrological study of the lumbar vertebral column during the foetal period

Marcin Czyż, Alicja Kędzia

Department of Normal Anatomy, Medical University of Wrocław, Poland

[Received 23 May 2003; Accepted 18 June 2003]

The aim of our study was to elaborate a scheme for the development of the particular elements of the lumbar vertebral column in the foetal period based on metrological data analysis. 30 human fetuses between 31 and 183 mm C-R length were examined. The whole vertebral column and lumbar segment length, intervertebral spaces and structural elements of each vertebra were measured. Statistical analysis was carried out of the data obtained. The development of the lumbar vertebral column during the foetal period is ongoing, although not in a proportional way. The percentage participation of the lumbar segment in the length of the whole vertebral column increased from 17.5 to 22%. The most intensive development of the particular elements resulted from the period between 60–170 mm. The intensive transversal growth of each vertebra began after 60 mm while the axial growth began after 110 mm CRL. The percentage participation of a single lumbar vertebra in the length of the whole lumbar segment decreased by approx. 5%. The largest contribution to the ossification centres was made in the areas of neural arches L1. Each structural element and the diameter of each lumbar vertebra is characterised by specific growth dynamics.

key words: lumbar vertebral column, metrology, anatomy, foetus

INTRODUCTION

A number of pathologies, concerning the lumbar vertebral column, arise as a result of developmental abnormalities. Advancement in the area of modern imaging techniques enables an early diagnosis of the majority of abnormalities during the foetal period [1, 3]. The sine qua non condition of the proper interpretation of the results achieved is a thorough knowledge of normal anatomical relations and the dynamics of the growth of the structures under examination. The aim of our study was to elaborate a scheme for the development of the particular elements of the lumbar vertebral column

in the foetal period based on metrological data analysis with linear correlations and regression slopes, according to Ursu et al. [7].

MATERIAL AND METHODS

The research was carried out on 30 fetuses of both sexes, obtained from spontaneous abortions with no macroscopic developmental defects. Their C-R length (CRL) varied from 31 to 183 mm. Classical anatomical preparation was performed via a stereoscopic microscope. The total length of vertebral column (A) and lumbar segment length (B) were established. Using Mitutoyo caliper (resolu-

tion 0,01 mm) exact measurements were carried out.

The scheme of measurements is presented in Figure 1. Measurements: E, F, I, J, K were obtained coincidentally for the right and the left side of each vertebra.

Statistical analysis was carried out with the use of the program Statistica Pl; where $p < 0.05$ was considered to be the level of significance.

RESULTS AND DISCUSSION

After the statistical exclusion of asymmetry the results of the relevant measurements were averaged. Results of basic statistical computations are presented in Table 1. The survey of the linear and non-linear correlation between particular diameters and CRL are presented in Figure 2. According to our research, the most dynamic development of the particular elements results from the period between 60 and 170 mm CRL. The dynamic transversal growth begins earlier than the axial growth of the vertebrae and the intervertebral areas. However, the quickened axial growth also takes place during the period above 180 mm CRL.

The phase of intensive development of the transverse diameter of the vertebrae is the period of growth in the length of the neural arches. Dynamic growth in the width of the neural arches commences later on.

The percentage participation of a single lumbar vertebra in the length of the whole lumbar segment decreased by approx. 5%. This process was ongoing, although not in a proportionate way. It was intensified between 50–80 mm and above 160 mm CRL. Taking into account that our research included only the dorsal part of the vertebrae, it is highly probable that the period between 50–80 mm and, respectively, above 160 mm CRL is the dynamic phase of vertebral corpora growth. The ossification centres had the largest contribution in the areas of the neural arches L1, whereas the differences between L1 and L3, L4 and L5 were statistically significant at p values 0.037; 0.004; < 0.0001 respectively. The metrology of the ossification centres confirms the cephalo-caudal conception of lumbar vertebral column ossification [2].

Previous research has demonstrated that a number of lumbar vertebral column pathologies arise due

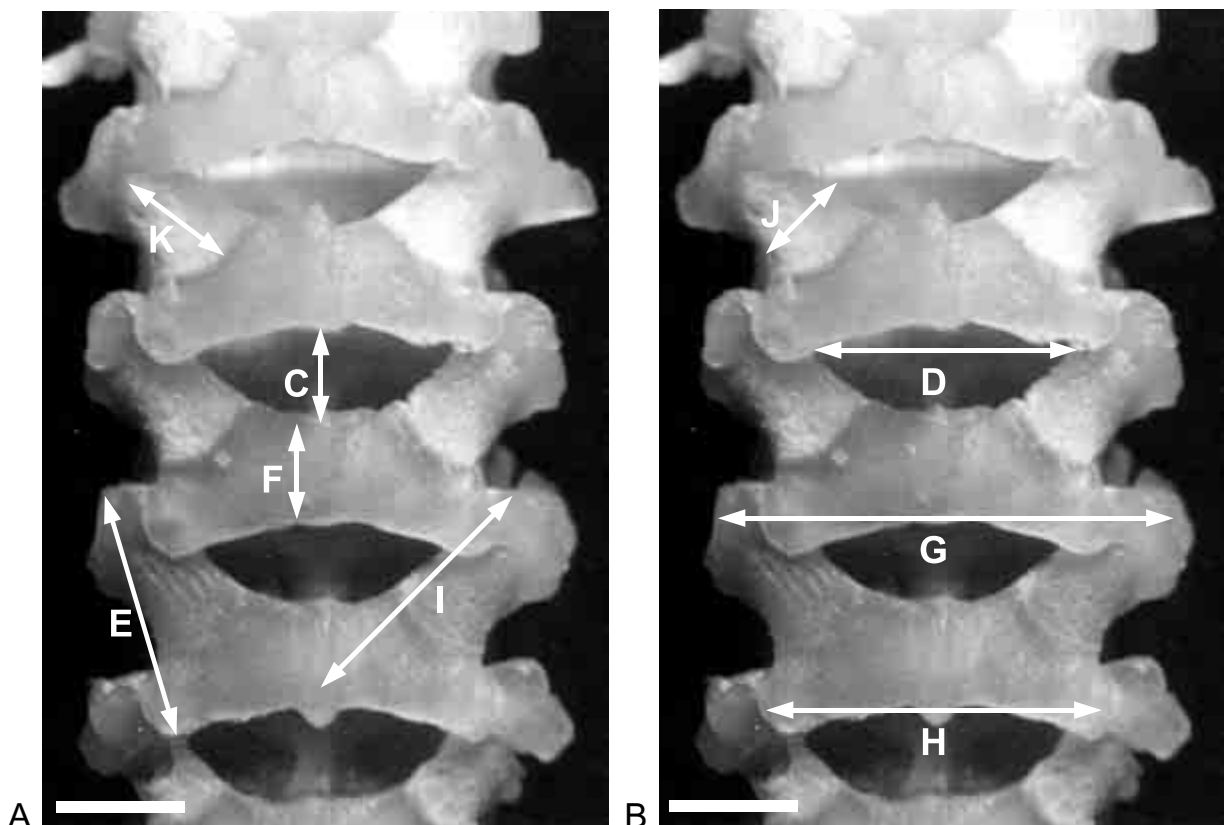


Figure 1. The scheme of axial (A) and transversal precise measurements (B). Lumbar 1 to 4 vertebrae and intervertebral spaces. Male foetus 183 mm CRL. The bar indicates 4 mm.

Table 1. Dimensions of the fetal lumbar vertebral column

Diameter	Mean value	Median value	Minimum	Maximum	Std. dev.
A	84.70	83.40	22.66	152.92	32.34
B	17.28	16.75	4.91	33.34	7.33
C	1.28	1.15	0.37	2.96	0.66
D	4.17	4.27	2.11	6.41	1.38
E	4.58	4.73	1.99	7.27	1.62
F	2.07	2.09	0.38	3.72	0.79
G	8.14	8.33	4.32	12.19	2.47
H	6.59	6.39	3.26	10.04	2.02
I	4.67	4.41	2.42	7.42	1.58
J	1.76	1.66	0.87	2.78	0.59
K	2.00	1.88	0.73	3.39	0.89

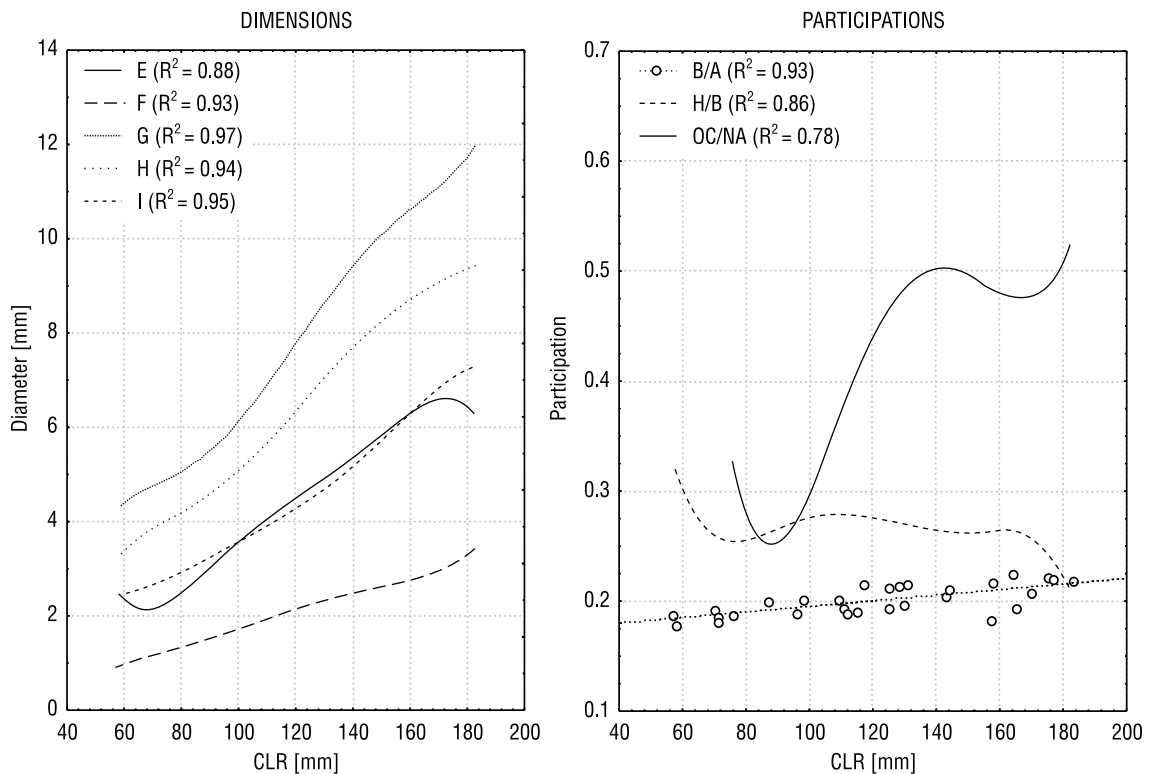


Figure 2. Development of particular dimensions of fetal lumbar vertebral column analyzed with linear correlations and regression slopes; OC — ossification center area (I × J); NA — neural arch area (J × K).

to developmental abnormalities [4–7]. The results of our survey may appear helpful in the early diagnosis of neural tube defects (NTD) and other pathologies of the axial skeleton. They would seem to constitute a landmark for further research based on a wider range of materials.

REFERENCES

1. Amin RS, Nikolaidis P, Kawashima A, Kramer LA, Ernst RD (1999) Normal anatomy of the fetus at MR imaging. *Radiographic*, 19: 201–214.
2. Bareggi R, Grill V, Zweyer M, Narduci P, Forabosco A (1994) A quantitative study on the spatial and temporal ossification patterns of the vertebral centra and

- neural arches and their relationship to the fetal age. *Ann Anat*; 176: 311–317.
3. Ertl-Wagner B, Lienemann A, Strauss A, Reiser MF (2002) Fetal magnetic resonance imaging: indications, technique, anatomical considerations and a review of fetal abnormalities. *Eur Radiol*; 12: 1931–1940.
 4. Nolting D, Fischer B, Keeling J, Kjaer I (1998) Prenatal development of the normal human vertebral corpora in different segments of the spine. *Spine*; 23: 2265–2271.
 5. Sagi HC, Jarvis JG, Uthoff HK (1998) Histomorphologic analysis of the development of the pars interarticularis and its association with isthmic spondylosis. *Spine*; 23: 1635–1640.
 6. Skawina A, Litwin JA, Gorczyca J, Miodoński AJ (1997) The architecture of internal blood vessels in human fetal vertebral bodies. *J Anat*; 191: 259–267.
 7. Ursu TR, Porter RW, Navaratnam V. (1996) Development of the lumbar and sacral vertebral canal in utero. *Spine*; 21: 2705–2708.