

# Developmental changes of morphology in the basolateral complex of the rabbit amygdala

Hanna Jagalska-Majewska, Anna Łuczyńska, Sławomir Wójcik, Jerzy Dziewiątkowski, Renata Kurlapska, Janusz Moryś

*Department of Anatomy and Neurobiology, Medical University of Gdańsk, Poland*

[Received 4 July 2003; Accepted 8 July 2003]

*The aim of the present study is to follow topographical and morphological changes in the development of the amygdaloid basolateral complex (BLC) in the rabbit. The material consists of 35 brains of New Zealand rabbits of both sexes, divided into 7 age groups (P2–P90). In cresyl violet preparations BLC is already well visible on P2 and is composed of the lateral (divided into dorsolateral and ventromedial divisions), basolateral and homogenous basomedial nuclei. On about the 7<sup>th</sup> postnatal day it is possible to divide the basomedial nucleus (BM) into dorsal (Bmd) and ventral (BMv) divisions. The topography and subdivisions set on P7 are maintained in further periods of life. The morphology of neurons (shape, dendrites, staining) changes significantly until P21 in all BLC nuclei. Our results indicate that BLC achieves morphological maturity relatively late, which is probably connected with a long creation of emotional memory and regulation of emotional behaviour.*

**key words:** amygdala, basolateral complex, development, morphology, topography, rabbit

## INTRODUCTION

In spite of numerous studies on the origin and development of the amygdaloid body in various species [1, 2, 6, 9, 14], there are still only scanty data concerning the development of the basolateral complex (BLC) in the rabbit. However, the prenatal development of the rabbit amygdala was reviewed by Clancy et al. [3]. According to these data, the neurons of the rabbit amygdala are generated on about the 16<sup>th</sup> day of prenatal life.

The amygdaloid body consists of two main complexes, the basolateral (BLC) and the corticomedial (CMC). The topography and morphology of the adult rabbit's amygdala have already been described in detail [4, 5, 7, 8, 10]. In this species BLC consists of lateral and basal nuclei. On the basis of morphology, the lateral nucleus splits into the dorsolateral (Ldl)

and ventromedial divisions (Lvm). Ldl is composed of small densely-packed darkly-stained pyramid-like and oval neurons. In contrast, the neurons of Lvm are large palely-stained and loosely-packed, mainly pyramid-like and occasionally fusiform.

Two main cellular groups, the basolateral (BL) and the basomedial (BM) are clearly recognisable in the basal nucleus. BL possess the largest darkly-stained pyramid-like, multipolar and oval neurons. On the basis of the size and density of the neurons BM is divided into the ventral part (BMv), with less dense and larger cells, and the dorsal part (Bmd) containing smaller and more densely-packed neurons.

Although BLC as a whole is considered to be a phylogenetically young structure, differences between its nuclei have recently been emphasised. These differences between particular nuclei are

caused by their remote pattern of connections [11], their various neurotransmitters [13] and their recently revealed difference of origin [12]. Taking into account these distinctions, it would seem interesting to investigate the process of morphological development of BLC neurons and topographical changes in the complex in the rabbit.

## MATERIAL AND METHODS

The material consists of 35 brains of New Zealand rabbits of both sexes, divided into seven age groups (P2, P7, P14, P 21, P30, P60, P90; P — postnatal day). The care and treatment of the animals were in accordance with the guidelines of the European Committee as well as of the Local Ethical Committee. The animals were deeply anaesthetised with a lethal dose of Thiopental (80 mg/kg of body weight i.p.). Next they were perfused transcardially with 50–250 ml (depending on the age of the animal) of cold 0.9% saline containing 10,000 units of heparin, followed by 100–1000 ml 4% solution of paraformaldehyde in 0.1 M phosphate buffer (pH 7.4 at temp. 4°C). After immediate removal from the skulls, the brains were fixed in the latter fluid for 3 hours, kept in 15% and next in 30 % sucrose solution in 0.1 M phosphate buffer (pH 7.4, 4°C) until sunk. Coronal 40- $\mu$ m-thick (age groups P2, P7, P14) or 50- $\mu$ m-thick (remaining age groups), serial sections of brains were cut with a JUNG 1800 cryostat (Leica, Germany). All sections were collected on glass slides, dried at room temperature and coverslipped with DPX (Fluka, Germany). Finally they were studied under the light microscope Labophot (Nikon, Japan) and the set of low magnification images was saved as bitmaps with the usage of light microscope Leica DMLC (Leica, Germany) equipped with camera DP10 (Olympus, Japan).

## RESULTS AND DISCUSSION

On P2 the BLC in the rabbit is already well visible in cresyl violet staining, although it is not yet fully developed. In this period the following nuclei are clearly distinguishable within BLC: the basolateral, the basomedial and the lateral (consisting of its two divisions) (Fig. 1A). Around P7 two neuronal populations in the basomedial nucleus (BM) appear that enable its partition into dorsal (BMd) and ventral (BMv). The topography and subdivisions set on P7 are maintained into later periods of life, although in cresyl violet staining the borders between basolateral complex nuclei are best visible from P7 to P21. During maturation and ageing after P21 BLC becomes difficult to distinguish from the neighbouring structures.

The developmental data available in the literature reveal that BLC in the rat differentiates from the homogenous mass of neuroblasts around the 17<sup>th</sup> day of prenatal life [2]. The lateral and basal nuclei are morphologically homogenous until the 7<sup>th</sup> day of postnatal life when their neuronal populations differentiate. The topography of BLC in the rat created by the 7<sup>th</sup> day of postnatal life remains unchanged until adulthood. From a comparison of the above data we can state that topographical relations within BLC in both species are fully developed after the first week of life.

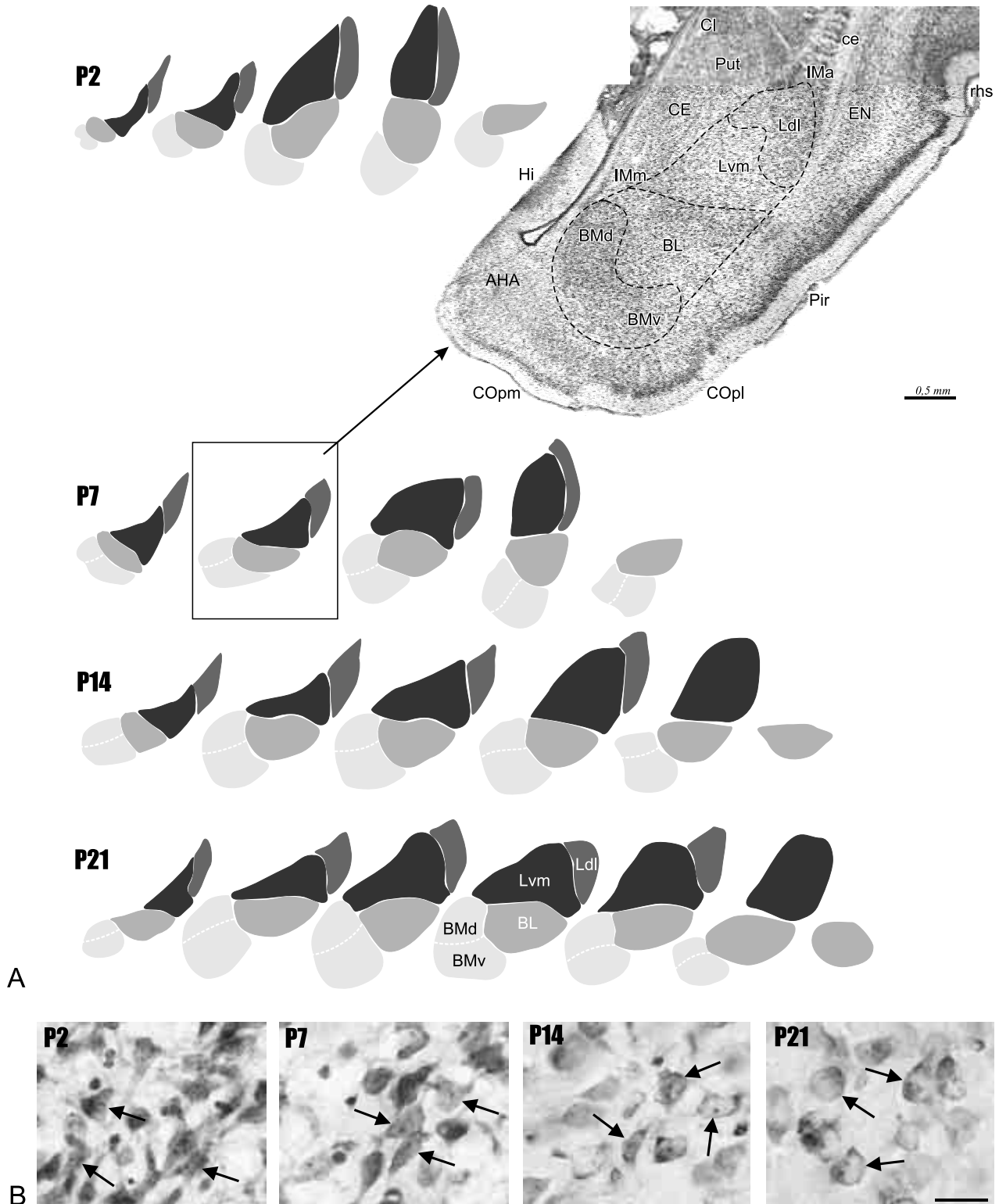
According to our results, neurons of all BLC nuclei undergo significant morphological changes until about P21 (Fig. 1B). After three weeks of postnatal life the shape, staining and size of the neurons stabilise. In younger age groups neuronal cells are pyramid-like, fusiform and multipolar, while later they become mainly pyramid-like, round and oval. Proximal portions of dendrites are clearly visible only from P2 to P14. The intensity of staining of the cytoplasm and nucleus decreases, which is connected with a lower level of basophilic components, indicating lower transcriptional and translational activity. The neurons increase in size and the amount of Nissl granulation in the cytoplasm decreases with age.

The fusiform and multipolar neurons are present in all nuclei but occur only in young age groups. They might either be still migrating neurons or immature settled neuronal cells. Taking into account our unpublished stereological data and the fact that the total number of cells increases during postnatal development, we may predict that these cells migrate from the paraventricular reservoir [1].

Berdel et al. [2], on the basis of morphological parameters (cross sectional area and nucleus/cytoplasm area), has shown that neurons of BLC in the rat reach the appearance characteristic for an adult animal between the 7<sup>th</sup> and 14<sup>th</sup> day of postnatal life.

By means of studies using Golgi techniques it has been revealed that changes in the shape of neurons and the extent of their dendritic tree in the cat basolateral complex stabilise after two weeks of postnatal life, as at this time two neuronal populations appear, spiny multipolar cells and spineless round neurons [15].

Taking the above data into consideration, we conclude that the neurons of the rabbit BLC mature 1–2 weeks later than those of the rat and cat. The protracted development of the rabbit BLC in comparison with other species studied seems to present



**Figure 1. A.** Topographical changes in BLC nuclei in the rabbit from P2 to P21 on coronal sections (the distance between coronal sections equals 0.24 mm). The photomicrograph on P7 at the level of the beginning of the ventral hippocampus. Cresyl violet. Scale bar = 50  $\mu$ m; AHA — amygdalohippocampal area, BL — basolateral nucleus, BM — basomedial nucleus (d, v — dorsal and ventral part, respectively), ce — external capsule, CE — central amygdaloid nucleus, COpm — posteromedial cortical nucleus, COpl — posterolateral cortical nucleus, EN — endopiriform nucleus, Hi — hippocampus, IM — intercalated masses (IMa — anterior, IMm — medial), Ldl — dorsolateral division of the lateral nucleus, Lvm — ventromedial division of the lateral nucleus, Pir — piriform cortex, Pu — putamen, rhs — rhinal sulcus; **B.** Photomicrographs of cells in the dorsolateral division of the lateral nucleus of BLC as an example of morphological changes in different age groups in the rabbit. Arrows show pyramid-like, fusiform and multipolar neurons in P2, P7 and P14 and pyramid-like, oval and round ones in P21. Cresyl violet. Scale bar = 25  $\mu$ m.

a better opportunity for further developmental studies. Our basic research on the rabbit BLC may form a framework for establishing the influence of intrinsic and extrinsic factors on development.

### REFERENCES

1. Bayer SA, Altman J, Russo RJ, Zhang X (1993) Timetables of neurogenesis in the human brain based on experimentally determined patterns in the rat. *Neurotoxicology* 14: 83–144.
2. Berdel B, Moryś J, Maciejewska B (1997) Neuronal changes in the basolateral complex during development of the rat's amygdala. *Int J Dev Neurosci* 15: 755–765.
3. Clancy B, Darlington RB, Finlay BL (2001) Translating developmental time across mammalian species. *Neuroscience* 105: 7–17.
4. Dziewiątkowski J, Berdel B, Kowiański P, Kubasik-Juraniec J, Bobek-Billewicz B, Moryś J (1998) The amygdaloid body of the rabbit — a morphometric study using image analyser. *Folia Morphol (Warsz)* 57: 93–103.
5. Girgis M, Shih-Chang W (1981) *Stereotaxic atlas of the rabbit brain*. Warren H. Green, Inc.
6. Humphrey T (1968) The development of the human amygdala during early embryonic life. *J Comp Neurol* 132: 135–166.
7. Jagalska-Majewska H, Dziewiątkowski J, Wójcik S, Łuczyńska A, Kurlapska R, Moryś J (2001) The amygdaloid complex of the rabbit — morphological and histochemical study. *Folia Morphol* 60: 259–280.
8. Kapp BS, Schwaber JS, Driscoll PA (1985) Frontal cortex projections to the amygdaloid central nucleus in the rabbit. *Neuroscience* 15: 327–346.
9. Moryś J, Berdel B, Jagalska-Majewska H, Łuczyńska A (1999) The basolateral amygdaloid complex — its development, morphology and functions. *Folia Morphol (Warsz)* 58: 29–46.
10. Nitecka L (1975) Comparative anatomic aspects of localization of acetylcholinesterase activity in the amygdaloid body. *Folia Morphol (Warsz)* 34: 167–185.
11. Pitkänen A, Jolkkonen E, Kempainen S (2000) Anatomic heterogeneity of the rat amygdaloid complex. *Folia Morphol* 59: 1–23.
12. Puelles L (2001) Brain segmentation and forebrain development in amniotes. *Brain Res Bull* 55: 695–710.
13. Swanson LW, Petrovich GD (1998) What is the amygdala? *Trends Neurosci* 21: 323–331.
14. ten Donkelaar HJ, Lammers GJ, Gribnau AAM (1979) Neurogenesis in the amygdaloid nuclear complex in a rodent (the Chinese hamster). *Brain Res* 165: 348–353.
15. Wakefield CL, Levine MS (1985) Early postnatal development of basolateral amygdala in kitten: a Golgi morphometric analysis. *Brain Res Bull* 14: 159–167.