

PCNA and laminin as prognostic factors in primary Fallopian tube carcinoma

Agnieszka Haloń, Jerzy Rabczyński

Department of Pathological Anatomy, Medical University, Wrocław, Poland

[Received 17 September 2003; Accepted 23 October 2003]

Primary Fallopian tube carcinoma (PFTC) is one of the rarest malignant tumours of the female genital tract. Staging of the disease according to FIGO scale is the most common prognostic indicator. Others, such as histological type, grading according to Hu classification, depth of tubal wall invasion, the presence of neoplastic cells in peritoneal leakage, invasion of the lymphatic and blood vessels, mitotic activity, DNA ploidy, Ki-67 expression, AgNOR level and p53 and c-erbB-2 immunoreactivity, are not widely accepted.

*70 cases of primary Fallopian tube carcinomas were analysed with regard to clinicopathological data, survival and the expression of proliferating cell nuclear antigen (PCNA) and laminin. Histological classification of PFTC revealed 26 cases of the endometrioid type, 16 undifferentiated, 15 serous, 8 urothelial, 3 clear-cell and 3 of other types. A total of 70 cases revealed positive nuclear staining for PCNA. The index of PCNA (labelling index, LI, proportion of PCNA-positive cells relative to all neoplastic cells) was evaluated. PCNA LI values were classified as high, > 0.45 , or low, ≤ 0.45 . Intracellular expression of laminin was found in 46 cases and extracellular in 28 cases. There was no significant correlation between the expression and distribution of laminin and survival. The *p* value was statistically significant only for PCNA LI as an independent prognostic factor.*

key words: primary Fallopian tube cancer, proliferation, invasiveness, prognosis, survival

INTRODUCTION

Primary Fallopian tube carcinomas (PFTC) are among the rarest female malignant tumours and account for only 0.2 to 1.8% of all malignant tumours of the female reproductive tract [1, 2, 5, 7–9]. This rarity places PFTC in 5th position among malignancies of this localisation. In Lower Silesia in Poland, PFTC is usually diagnosed and histologically confirmed at a frequency of 2 to 4 cases per year. PFTC is associated with an extremely poor prognosis, especially in advanced stages of the disease [1, 2, 7, 8]. The rare incidence of PFTC does not permit enrolment of a significant number of cases in one clinical

centre within a short period and it is, therefore, very difficult to explain PFTC histogenesis and to assess diagnostic modalities and therapeutic efficiency. Staging of the disease in accordance with the FIGO scale is the most common, widely accepted and only reliable prognostic factor for PFTC [5, 9, 10]. The value of other commonly used prognostic factors, such as histological type, grading according to Hu classification, depth of tubal wall invasion, the presence of neoplastic cells in peritoneal leakage, invasion of the lymphatic and blood vessels, mitotic activity, DNA ploidy, Ki-67 expression, AgNOR level and p53 and c-erbB-2 immunoreactivity, have not found wider

acceptance [5, 8, 9]. These may be used as evidence to support a prognosis, but none is an independent prognostic factor.

In the years 1982–2002 in the Department of Pathology of Wrocław Medical University, 70 cases of PFTC were diagnosed or consulted. The tissue samples and paraffin blocks collected in our institution appear to constitute one of the largest collections worldwide and the largest in Poland. We decided to evaluate our histological material according to the criteria established for common epithelial ovarian tumours, clinical course and prognostic factors in PFTC. The evaluation of the biological aggressiveness of cancer cells might be used as a prognostic factor.

One of methods for the assessment of proliferative activity is to determine mitotic activity by detection and evaluation of proliferating cell nuclear antigen (PCNA) positive cells [3, 4]. To date no papers have described PCNA expression in pathological changes of the tube. A further major characteristic of malignancy is invasive growth [6]. Penetration of the basement membranes (BM) by the tumour cells followed by migration into the interstitial stroma is regarded as a first sign [10]. In many types of tumour the BM was found to be discontinuous at the site of invasion. However, BM components such as laminin are also deposited around tumour cell nests [6, 10]. To establish new prognostic factors in PFTC and identify molecular-biological risk groups, we evaluated the expression of PCNA nuclear protein connected with cell cycle regulation as an indicator of proliferation and laminin as a determinant of tumour invasiveness. In this study we have investigated the correlation between the expression of PCNA and laminin and the stage, histological type, grade and the survival of the group of 70 patients with PFTC.

MATERIAL AND METHODS

70 patients with PFTC diagnosed or consulted in the Department of Pathology at Wrocław Medical University during the years 1982–2002. The age of the patients ranged from 38 to 84 years (mean: 57.5). Histological classification of PFTC was performed according to WHO ovarian tumour classification and the staging of the disease was based on the FIGO scale for Fallopian tube cancer. Histological classification revealed the following: 26 endometrioid cancers, 16 undifferentiated, 15 serous, 8 transitional, 3 clear cell and 2 of another type. 38 patients were FIGO I stage, 14 FIGO II stage, 16 FIGO III and 2 FIGO IV. The mean

observation time was 52 months (range: 2–178). 38 patients died with recurrence of the disease.

Formalin fixed, paraffin-embedded tissue samples were cut into 4 μm sections. Immunohistochemical staining for PCNA and laminin was performed using the avidin-biotin peroxidase complex method. Primary antibodies against PCNA — Lyophilised Monoclonal NCL-PCNA Clone PC10 (Novocastra) and laminin — Lyophilised Monoclonal NCL-LAMININ Clone LAM-89 (Novocastra) were used. The computed quantitation of PCNA positive cells was counted in 300 cancer cells in random high-power fields (10×40) and was scored as the labelling index (LI, %). Laminin expression was based on the following two separate scales: percentage of positive cells (grading, G: G0–G2) and staining strength (intensity, I: I0–I3) for intracellular laminin and intensity of extracellular laminin distribution (extracellular, E: E0–E3) (Fig. 1).

Statistical analysis was conducted and the correlation between the markers evaluated and the clinicopathological parameters was assessed using log-rank, the Mantel-Haenszel test and the Cox proportional hazards model. Survival curves were generated according to the Kaplan-Meier method.

RESULTS

Positive staining for PCNA was identified in the nuclei in all cases. LI PCNA values ranged from 0.3231 to 0.8363. LI PCNA values were classified as high, > 0.45 , or low, ≤ 0.45 . There was no correlation between PCNA LI and histological type ($p = 0.262$), grade ($p = 0.077$) or FIGO stage ($p = 0.232$). There was a correlation between PCNA LI and survival ($p \leq 0.09$). Patients with PCNA LI > 0.45 had a significantly worse prognosis, 44.1% and a 5-year survival in contrast to 83.3% for PCNA LI ≤ 0.45 . Intracellular expression of laminin was found in 46 cases and extracellular in 28 cases. There was no significant correlation between the expression and distribution of laminin and clinicopathological features such as FIGO stage, histological type, grade and survival. The p value was statistically significant only for PCNA LI as an independent prognostic factor.

DISCUSSION

Primary Fallopian tube carcinoma is relatively rare and is associated with a poor prognosis [1, 2, 4, 9, 10]. From the various prognostic factors only the staging of the disease at the time of diagnosis in accordance with the FIGO scale has an established value

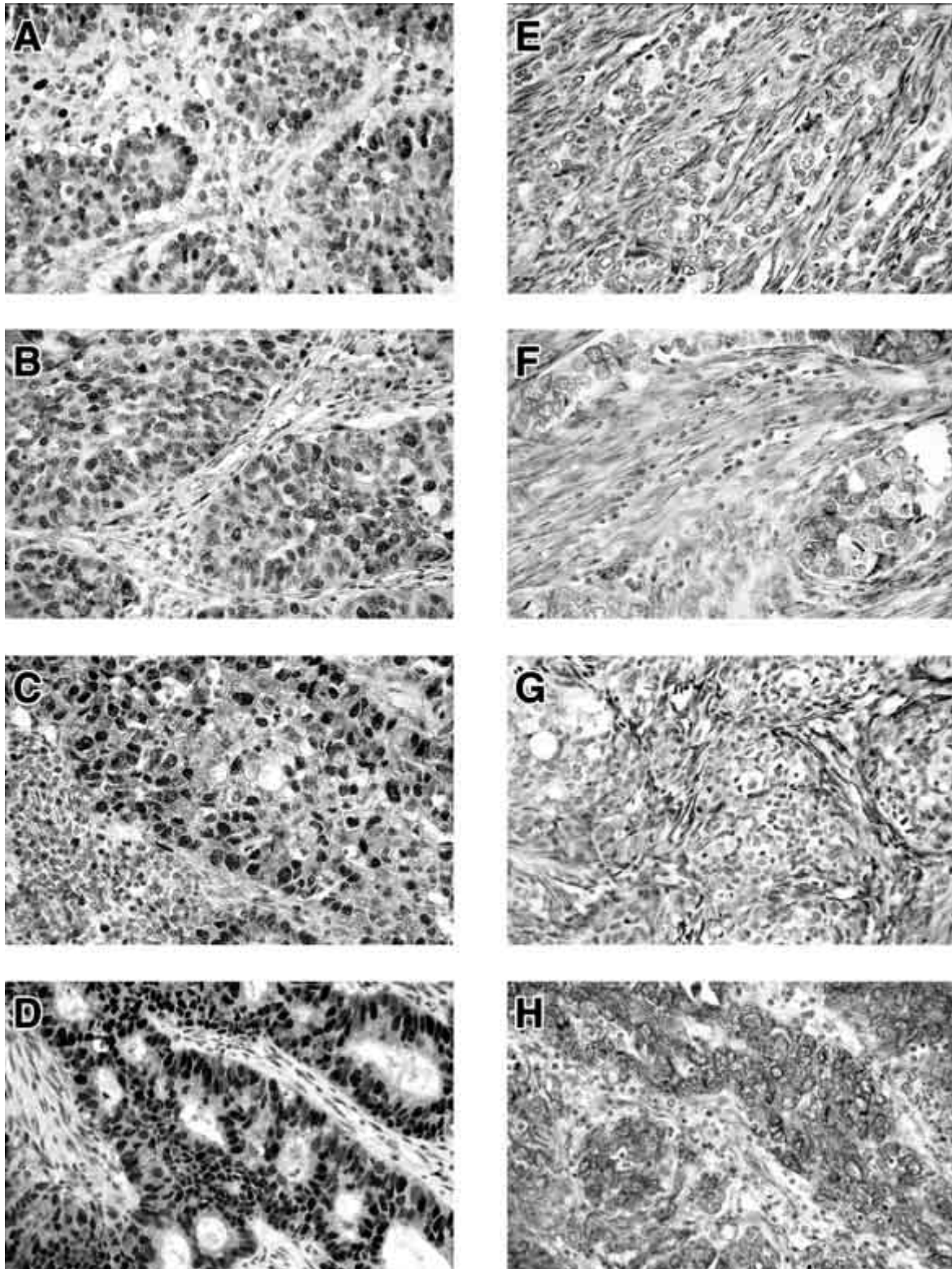


Figure 1. Representative photomicrographs of immunostaining results in primary Fallopian tube carcinomas; magnification 400 \times . Sections immunostained for PCNA (A–D) and laminin (E–H) using specific antibodies. **A.** Primary endometrioid carcinoma (G2), nuclear staining for PCNA, LI = 0.45; **B.** Primary endometrioid carcinoma (G2), nuclear staining for PCNA, LI = 0.65; **C.** Primary undifferentiated carcinoma, nuclear PCNA staining, LI = 0.70; **D.** Primary endometrioid carcinoma (G1), nuclear PCNA staining, LI = 0.75; **E.** Primary undifferentiated carcinoma, extracellular positivity for laminin, G0-I0-E2; **F.** Primary endometrioid carcinoma (G1), diffuse cytoplasmic and partly strong extracellular positivity for laminin, G1-I1-E2; **G.** Primary endometrioid carcinoma (G3), diffuse cytoplasmic and strong extracellular positivity for laminin, G2-I1-E1; **H.** Primary endometrioid carcinoma (G3), strong diffuse, globular cytoplasmic and strong extracellular positivity for laminin, G2-I2-E3.

[4, 9, 11]. It is hard to establish the prognostic criteria for primary Fallopian tube carcinoma due to the limited size of the group with primary tubal cancer. Any conclusive demonstration with regard to the prognostic value of the studied markers and factors affecting the course of PFTC is thereby impaired. Primary Fallopian tube malignant epithelial tumours do not reveal any specific histological structure. They are derived from the Müllerian duct epithelium and indirectly from epithelium overlying the celoma. These neoplasms thus reflect in their histology the whole range of epithelial tumours commonly found in the female genital tract ranging from the uterine cervix to the ovaries [1].

There are promising findings connected with PCNA and laminin expression in various malignant tumours [3, 4, 6, 10]. Recent studies have shown that extensive deposition of laminin is prognostically significant in colorectal carcinomas. A peculiar pattern of laminin staining was noted in squamous cell lung carcinomas (SqclC) [10]. The FIGO stage, as in other studies, turned out to be the main strong independent prognostic factor. Serous and clear cell histological type also constitutes an independent unfavourable prognostic factor. Of the markers evaluated the only self-reliant indicator is a proliferating PCNA index with value > 0.45 , which unequivocally types the patients with the worst prognosis. The use of laminin as a prognostic factor in primary Fallopian tube carcinoma has not been definitively explained. Nevertheless, we can not exclude their influence upon the total survival rate and the course of the disease. In the light of contemporary knowledge and experience with laminin, however, their evaluative and forecasting potential cannot be utilised as independent diagnostic and prognostic factors.

REFERENCES

1. Alvarado-Cabrero I, Young RH, Vamvakas EC, Scully RE (1999) Carcinoma of the fallopian tube: a clinicopathological study of 105 cases with observations on staging and prognostic factors. *Gynecol Oncol*, 72: 367–379.
2. Baekelandt M, Nesbakken AJ, Kristensen GB, Trope CG, Abeler VM (2000) Carcinoma of the Fallopian tube. Clinicopathologic study of 151 patients treated at the Norwegian Radium Hospital. *Cancer*, 89: 2076–2084.
3. Delahunt B, Bethwaite PB, Nacey JN, Ribas JL (1993) Proliferating cell nuclear antigen (PCNA) expression as a prognostic indicator in renal cell carcinoma: comparison with tumour grade. Mitotic index and silver staining nucleolar organizer region numbers. *J Pathol*, 170: 471–477.
4. Hall PA, Levison DA, Woods AL, Yu CC-W, Kellock DB, Watkins JA, Barnes DM, Gillett CE, Camplejohn R, Dover R, Waseem NH, Lane DP (1990) Proliferating cell nuclear antigen (PCNA) immunolocalization in paraffin sections: an index of cell proliferation with evidence of deregulated expression in some neoplasms. *J Pathol*, 162: 285–294.
5. Hellström AC, Silfverswärd C, Nilsson B, Pettersson F (1994) Carcinoma of the Fallopian tube. A clinical and histopathologic review. The Radiumhemmet series. *Int J Gynecol Cancer*, 4: 395–400.
6. Liotta LA, Rao CN, Wewer UM (1986) Biochemical interactions of tumour cells with the basement membrane. *Ann Rev Biochem*, 55: 1037–1057.
7. Nordin AJ (1994) Primary carcinoma of the fallopian tube: a 20-year literature review. *Obstet Gynaecol Surv*, 49: 349–361.
8. Rabczyński J, Ziółkowski P, Kochman A, Górzyńska E (1998) Primary Fallopian tube carcinoma. Histopathology of 46 cases. *Pol J Pathol*, 49: 285–292.
9. Rosen AC, Ausch M, Hafner E, Klein M, Lahousen M, Graf AH, Reiner A (1998) A 15-year overview of management and prognosis in Fallopian tube carcinoma. Austrian Cooperative Study Group for Fallopian Tube Carcinoma. *Eur J Cancer*, 34: 1725–1729.
10. Ten Velde GP, Havenith MG, Volovics A, Bosman FT (1991) Prognostic significance of basement membrane deposition in operable squamous cell carcinomas of the lung. *Cancer*, 67: 3001–3005.