

Immunohistochemical and electron-microscopical identification of neuroendocrine cells in the respiratory tract of rats with experimental uraemia

Irena Kasacka, Bogusław Sawicki

Department of Histology and Embryology, Medical University, Białystok, Poland

[Received 11 September 2003; Accepted 9 January 2004]

The aim of the present study was to characterise immunohistochemically and ultrastructurally the neuroendocrine cells in the pulmonary systems of uraemic rats. Pieces of lung and trachea were collected 1, 2 and 4 weeks after nephrectomy. Paraffin-embedded sections were stained with H+E and by silver impregnation. For the identification of neuroendocrine cells immunohistochemical reactions were performed with the use of specific antibodies against calcitonin (CT), somatostatin (SOM), synaptophysin (SYN), neuron-specific enolase (NSE) and calcitonin gene-related peptide (CGRP). For electron microscopy, ultrathin sections were used. The analysis showed an increased number of both the solitary neuroendocrine cells and of neuroepithelial bodies in uraemic rats when compared to control animals.

Key words: APUD cells, lung, trachea, rats, uraemia

INTRODUCTION

Damage to lung function and impaired regulation of breathing are consequences of uraemia [3]. These symptoms may, at least in part, result from abnormal functioning of the endocrine cells that act in conjunction with the higher neural and endocrine control systems to maintain pulmonary structure and function [1, 5]. It is known that neuroepithelial bodies (NEB) serve as chemoreceptors, while solitary neuroendocrine cells (PNECs) and their secretory peptides are also thought to regulate airway tone and pulmonary blood flow during respiration [1, 5].

The aim of the present study was to determine, on the basis of immunohistochemical investigations and ultrastructural pictures, the presence, location and changes in functional morphology of APUD cells in the lungs of uraemic rats.

MATERIAL AND METHODS

The study was carried out on 51 male Wistar rats (200–250 g b.w.). The animals were housed at 20°C with a relative humidity of 40–45% and a 12 h light/dark cycle. They were given tap water and standard rat chow. The experimental uraemia was induced in 21 rats according to the method described by Ormord and Miller [4]: surgical resection of one kidney and removal of 70% of the other kidney cortex. 15 animals in the first control group underwent a sham operation (SO). The second control group did not undergo any surgical procedure. One, 2 and 4 weeks after surgery pieces of the lungs and trachea were collected under deep pentobarbital anaesthesia (50 mg/kg b.w.). The specimens were fixed in Bouin's fluid and embedded in paraffin in a routine manner and in 2.5% purified glutaraldehyde for electron microscopy. Sections (5 μ m) were stained with H+E




Figure 1. Electron micrographs of neuroendocrine cells, with electron dense granules (arrows); **A.** Control rat; **B.** After two weeks following nephrectomy. $\times 3000$.

and with the silver method according to Grimelius [2]. The immunohistochemical reactions were performed by the use of specific antibodies against CT (1:50; DAKO), SOM (1:200; DAKO), SYN (1:10; DAKO) and CGRP (1:8000; SIGMA). For visualisation of immunocomplexes, the avidin-biotin complex was used according to commercial protocol. Ultrathin sections (60 nm) were examined with an OPTON 900 PC electron microscope. In addition, blood serum creatinine and urea levels were determined by a Beckman-CX4 Analyzer.

RESULTS AND DISCUSSION

The results of the electron-microscopic pictures supplement and confirm evidence for the presence of neuroendocrine cells in the rat lung (Fig. 1). No significant differences were found between the control groups of rats and therefore only the results relating to the animals subjected to a SO were discussed. In uraemic rats the concentration of creatinine and urea increased when compared to the control group. The creatinine level was 0.54 ± 0.052 mg/dl in the control rats and 0.67 ± 0.09 , 0.9 ± 0.06 , 0.77 ± 0.06 mg/dl in the uraemic rats (1, 2 and 4 weeks after nephrectomy, respectively). The urea concentration in the control rats was 43.83 ± 5.97 mg/dl and 58.8 ± 8.44 , 97.57 ± 8.01 and 83.5 ± 7.71 mg/dl in the uraemic animals (1, 2 and 4 weeks after nephrectomy, respectively). After routine H+E staining only single cells with a dark-staining nucleus lying centrally in a light, poorly eosinophilic cytoplasm could sometimes be observed. After impregnation with silver salts, both PNECs and NEB were observed (Fig. 2). The immunohistochemical



Figure 2. Photomicrograph of the lung of a rat two weeks after nephrectomy. The neuroepithelial body is impregnated with silver according to the Grimelius method. $\times 400$.

studies revealed a positive cytoplasmatic reaction in neuroendocrine cells of the lung and trachea in all the rats examined (Fig. 3, 4). The analysis showed an increased number of APUD cells in uraemic rats, which may be a morphological manifestation of their hyperfunction after functional impairment of renal parenchyma. The largest number and reaction intensity of cells occurred after 14 days of uraemia. Investigations concerning APUD cell activity in uraemia have not as yet been conducted. Taking into consideration the homeostatic disturbances of the organism induced by the impairment of renal parenchyma and the key role of neuroendocrine cells in many of the organs that regulate the functioning of the organism, it should be assumed that PNEC are closely involved in the chain of physiological events that takes place in the lungs during uraemia.




Figure 3. Immunohistochemical reaction for somatostatin in the lungs of rats. **A.** Control group ($\times 300$); **B.** Two weeks after nephrectomy ($\times 200$); **C.** 4 weeks after nephrectomy ($\times 300$).

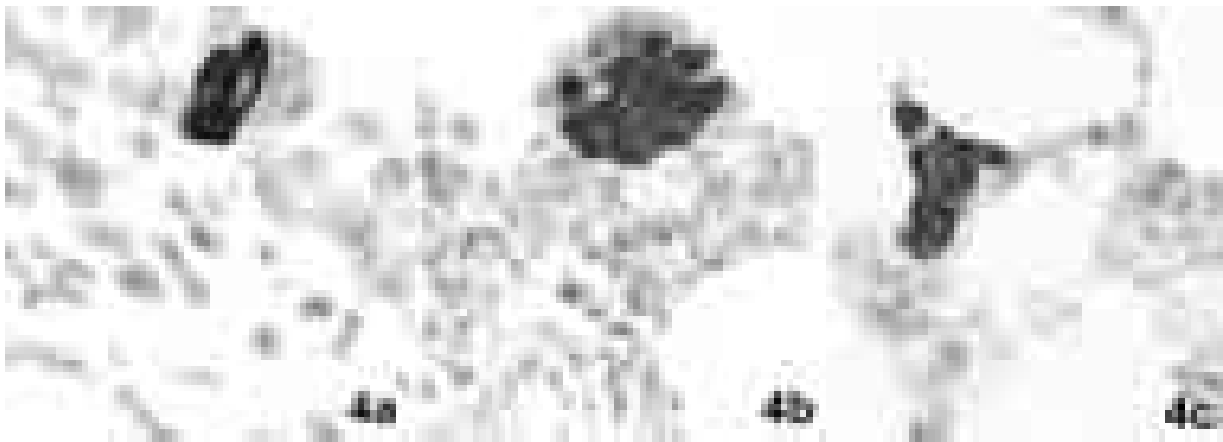


Figure 4. Immunohistochemical reaction showing CGRP in the lungs of the rats. **A.** 7 days ($\times 600$); **B.** 2 weeks ($\times 400$); **C.** 4 weeks after nephrectomy ($\times 200$). A significant increase in the number of CGRP-immunoreactive cells was observed 2 and 4 weeks following nephrectomy.

REFERENCES

1. Avadhanam KP, Plopper ChG, Pinkerton KE (1997) Mapping the distribution of neuroepithelial bodies of rat lung. *J Pathol*, 150: 851–857.
2. Grimelius L (1968) A silver nitrate stain for $\alpha 2$ cells in human pancreatic islets. *Acta Soc Med Uppsal*, 73: 243–294.
3. Kalender B, Erk M, Pekpak M, Apaydin S, Ataman R, Serdengecti K, Sariyar M, Ereğ E (2002) The effect of renal transplantation on pulmonary function. *Nephron*, 90: 72–77.
4. Ormrod D, Miller T (1980) Experimental uremia. *Nephron* 26: 249–254.
5. Peake JL, Reynolds SD, Stripp BR, Stephens KE, Pinkerton KE (2000) Alteration of pulmonary neuroendocrine cells during epithelial repair of naphthalene-induced airway injury. *Am J Pathol*, 156: 279–286.