

Bone graft substitutes in periodontal and peri-implant bone regeneration

T. Bayerlein¹, T. Mundt², F. Mack², V. Bienengraber³, P. Proff¹, T. Gedrange¹

¹Clinic for Orthodontics and Preventive and Paediatric Dentistry, University of Greifswald Dental School, Greifswald, Germany

²Clinic for Prosthodontics, Ernst Moritz Arndt University, Greifswald, Germany

³Clinic for Cranio-Maxillofacial and Plastic Surgery, University of Rostock, Germany

[Received 21 December 2005; Accepted 8 February 2006]

Regenerative medicine provides different therapy alternatives alongside gold standard autogenous grafts for the treatment of periodontal or peri-implant osseous defects. Continuing progress in the field of alloplastic bone substitutes has yielded promising solutions to the appropriate indications with the membrane technique either alone or in combination with enamel matrix derivatives. Their clinical outcomes, however, still require critical discussion.

Key words: bone graft substitutes, bone regeneration, periodontology, implantology

INTRODUCTION

For over two decades regenerative therapy has been finding its way into the disciplines of periodontology and implantology. Bone graft substitutes are used for the periodontal reconstruction of supportive tissue and for implantological bone augmentation and therapy of peri-implant lesions, thus providing an alternative to autologous bone grafts, which require an intraoral or extraoral second entry, depending on the indication and quantity needed. The development of biological-alloplastic osteoconductive bone reconstruction materials, which primarily aim at bony defect regeneration not only in physical but also in biological terms, has steadily gained importance during recent years [7, 13, 15]. Beside these alloplastic bone substitutes, primarily used for implant-supporting therapy, the scope of the materials used in periodontal regenerative therapy has been broadened by membrane systems used according to the principles of guided tissue regeneration (GTR) and the application of enamel matrix derivatives (EMD).

REGENERATIVE TREATMENT OF PERIODONTAL DEFECTS

The objective of periodontal therapy is a significant reduction in pocket depth and a gain of clinical attachment, with treatment mainly including mechanical debridement of root and tooth surfaces (Fig. 1). Large defects or unfavourable pocket configurations, where complete healing is not achieved by mechanical debridement, may lend themselves to defect filling, not only in order to achieve physiological

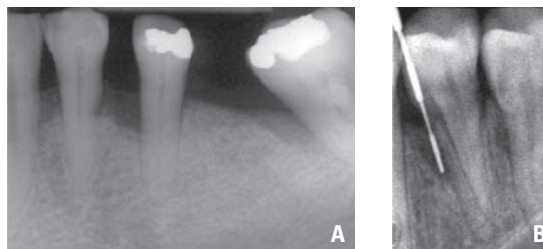


Figure 1. A. X-ray presentation of periodontal bone defect 34 and 36 with loss of tooth 35; B. Periodontal bone defect with periodontal testing probe.

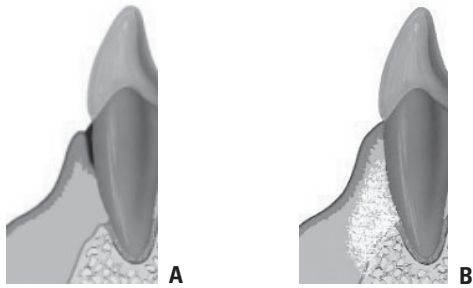


Figure 2. A. Periodontal bone loss (sketch); B. Periodontal bone loss with application of bone substitute.

bone morphology but also to improve the healing prospects of the tooth root in the alveolus [11]. Beside the initially exclusive application of barrier membranes, bone grafts or bone substitutes have been used more often (Fig. 2).

BONE GRAFTS AND BONE SUBSTITUTES

Lost bone may be replaced by autogenous, allogeneous or xenogeneous bone grafts or, alternatively, treated using alloplastic bone substitutes. Good results in the treatment of periodontal bone loss have been obtained using bone grafts. Both autogenous (formed from a natural part of the body) or allogeneous (foreign to the body) grafts are of human origin by definition. Normally the chin area, the tuber region and the toothless jaw segments serve as donor regions. In the treatment of periodontal osseous defects such intraoral bone transplantation, leading to formation of new cementum, periodontal ligament and alveolar bone is, therefore, superior to extraoral transplantation (e.g. iliac crest) with the increased risk of ankylosis and root resorption. However, the quantity of available bone is *per se* limited, which makes extraoral bone harvesting inevitable in severe, albeit rare, cases of bone loss. Generally, autogenous bone grafting in intrabony alveolar defects yields a clinical defect filling of 25 to 50% [3].

Allogeneous bone is produced from long tubular bones of multi-organ donors. In contrast to autogenous bone grafts, the demineralised freeze-dried bone allografts (DFDBA) are harvested without the burden of a second surgical entry and are available in an unlimited quantity. A disadvantage is the potential danger of a virus infection, although the risk of disease transmission is estimated at only 1:1 million to 1:8 million, depending on the tissue preparation [11].

Xenogeneous bone grafts (e.g. Bio-Oss®) have long been used in the treatment of periodontal bone defects. These materials are produced from animal bone

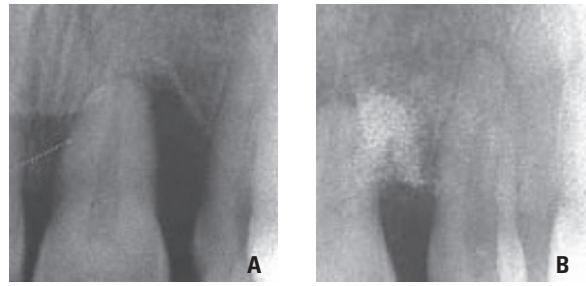


Figure 3. A. Periodontal bone loss with pronounced bone defect; B. Bone defect filled up with bone substitute.

and cannot be used until they have undergone sufficient sterilisation and deproteinisation. Thermally (> 1.200 degrees) and chemically treated bovine bone has elastic modules similar to intact bone and is available in huge quantities. However, problems remain regarding the immunological situation, the residual infection risk and patient acceptance.

Many animal experiments and patient studies show that periodontal regeneration occurs after xenogeneous bone grafting [2, 9]. Regenerative results were enhanced by improved wound management (application of collagen membranes) [8] (Fig. 3).

New-generation alloplastic bone substitutes on the basis of anorganic bone mineral-related calcium phosphate ceramics (α -tricalcium phosphate, β -tricalcium phosphate and hydroxyapatite) show the best osteoconductive properties with respect to the desired bone reconstructive function. They are used for critical defect filling with increasing clinical success.

The outcome of periodontal supportive tissue reconstruction depends upon defect configuration as much as upon the material applied. Narrow three-walled pockets represent the best conditions for vital preservation and substitution with least risk of infection [11]. α - and β -tricalcium phosphate (TCP) are produced similarly to the synthetic hydroxyapatite ceramics (HA ceramics), although they display different resorption properties. Within the body α -TCP partially or completely hydrolyses to hydroxyapatite and is, therefore, hardly degradable like the latter. The novel nanoporous hydroxyapatites, however, promise a distinctly improved resorption behaviour supposed to correspond to that of β -tricalcium phosphates (e.g. Cerasorb®, Curasan-Pharma GmbH, Kleinostheim, Germany) which are degraded almost completely. However, the use of β -tricalcium phosphate in the treatment of periodontal bony defects has been critically discussed in the literature [12].

Since 1989 coralline calcium carbonate (e.g. Bio-coral[®], Inoteb, B.P. Saint-Gonnelly, France) as a protein-free and sterilised natural coral skeleton has been approved for application in humans. Mainly after implantation of this material in the mandible, the zygomatic bone and the frontal calvarium, healing proceeds without problems [14]. The absence of specific proteins minimises the risk of immunological reactions. In the treatment of periodontal bony defects, however, the use of coralline bone substitutes does not yield the desired outcome.

MEMBRANE APPLICATION

Another treatment approach for periodontal osseous defects utilises the self-healing effect of bone. This method aims to restore the lost periodontal structures by a differentiated tissue response and is referred to as "guided tissue regeneration" (GTR) using resorbable or non-resorbable membranes. This principle implies the creation of a secluded hollow space, in which bone tissue regenerates but gingival connective tissue is prevented from growing. The hollow space is filled with bone, bone reconstructive material or a mixture of both. Subsequently, a slowly resorbable membrane is inserted as a physical barrier. In consequence, desmodontal cells are the first to form on the root surface of the tooth. These new desmodontal structures then coalesce with the gingival connective tissue, thus leading to elimination of the periodontal pocket.

The use of resorbable membranes involves various polylactides and copolymers of polylactides/polyglycolides, while filter membranes and polytetrafluorethylene (Teflon) have been successfully used as non-resorbable materials. We have to consider, however, that a surgical re-entry is required for the removal of non-resorbable membranes. The use of membranes permits combination with bone grafts or bone substitute materials.

ENAMEL MATRIX DERIVATIVES

Studies on tooth development conducted by Hammarström in 1997 [5] showed that acellular cementum is formed as soon as dental follicle cells come into contact with an endogenous or exogenous enamel matrix. On the basis of these findings attempts have been made to integrate enamel matrix proteins into periodontal regenerative therapy as a possible treatment alternative. The application of EMDOGAIN[®] (BIORA AB, Malmö, Sweden), a hydrophobe mixture of enamel matrix proteins produced from the tooth germs of young pigs, to the

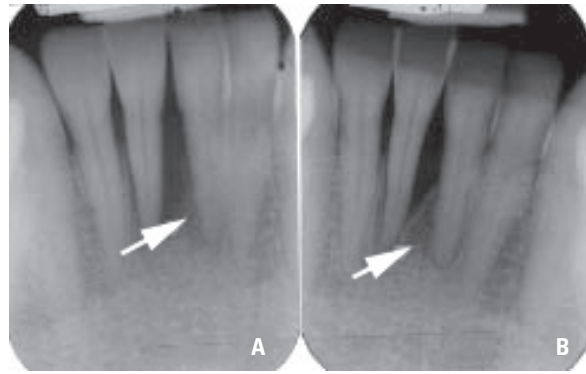


Figure 4. A. Intrabony defect before treatment; B. Periodontal regeneration of intrabony defect after treatment with Enamel Matrix Derivatives.

debrided root surface aims to mimic the cell-matrix interaction of embryogenesis with the associated formation of acellular cementum, which plays a key role in the periodontal regeneration of intrabony defects and, therefore, is supposed to improve the latter (Fig. 4).

Numerous studies, such as that by Heijl et al. [6], who applied EMDOGAIN[®] to infra-alveolar bone pockets and subsequently observed the formation of new cementum, periodontal ligament, and a 66% defect filling with new bone after 36 months, appear to prove the effectiveness of this therapy concept.

However, the use of EMDOGAIN[®], which is composed of purified amelogenins, has the disadvantages that it can be used only in existing periodontal bone defects and not in implantology and that its effects are not fully predictable [13].

PERI-IMPLANT BONE REGENERATION

In the field of implantology a deficient bone supply in the implantation area on the one hand and a loss of peri-implant bone as a result of peri-implantitis on the other hand are often a great challenge to the dental practitioner. Numerous augmentative procedures with their respective advantages and disadvantages as mentioned above with respect to periodontal regenerative therapy are also utilised for peri-implant bone regeneration. Research and further development of bioceramic bone substitute materials on a calcium phosphate basis from a merely "bridging" to a "bone-reconstructive" function turns those materials into an applicable alternative for the respective indications.

Particularly in elderly prosthodontic patients, the clinician faces a reduced bone supply as a result of

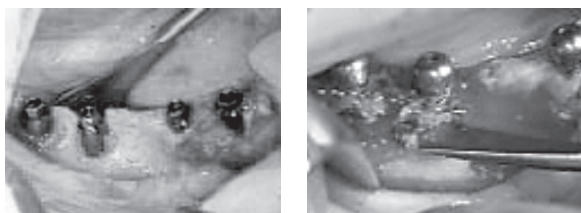


Figure 5. Bone deficit after implantation. Application of a bone chipping/bone substitute mix in the defect region covered by a titan mesh.

progressive atrophy of the alveolar ridge. As an example, Tiolox implants (Tiolox, Implants GmbH, Dentaorium Company) are demonstrated in regions 43, 44, 46, and 47 with vestibular bone deficit after implantation. The defects have been covered using bone grafts, which were harvested during preparation of the implant bed.

Additionally, Biogran (Fa. 3i) was applied in the two distal implants. The relatively large augmentation areas were covered by a titan mesh, Tiomesh (Tiolox Implants GmbH, Dentaorium Company, Ispringen) for material fixation. The titan mesh was fixed to the implant by means of the cover screw (Fig. 5). In the regenerative therapy of multi-factorial funnel-shaped and slit-shaped peri-implant defects with progressive bone resorption both the membrane technique associated with frequent premature membrane exposure [4] and the use of bone substitutes [10] are a subject of controversy. In contrast, defect filling using autogenous bone grafts without membrane coverage yields far better results [1].

PROSPECTS

As well as the integration of enamel matrix derivatives into surgical periodontal therapy as a novel regenerative technique the application of "tissue engineering" from patient cells also permits the production of very well tolerated tissue transplants. 3D cultivation of human mesenchymal stem cells and osteogenous differentiation for bone tissue production are already performed in many laboratories. However, a large-scale clinical application of "tissue engineering" in the treatment of periodontal bone defects is not yet possible.

In the near future industrially manufactured biomaterials are likely to be applied in combination with laboratory-grown cells.

REFERENCES

1. Behneke A, Behneke N, d'Hoedt B (2000) Treatment of peri-implantitis defects with autogenous bone

- grafts: six-month to 3-year results of a prospective study in 17 patients. *Int J Oral Maxillofac Implants*, 15: 125–138.
2. Camelo M, Nevins ML, Schenk RK, Simion M, Rasperini G, Lynch SE, Nevins M (1998) Clinical, radiographic, and histologic evaluation of human periodontal defects treated with Bio-Oss and Bio-Gide. *Int J Periodontics Restorative Dent*, 18: 321–331.
3. Ehmke B, Flemmig TF (1999) Knochen und Knochenersatzmaterialien zur parodontalen Regenerationen. *Wissenschaftliche Stellungnahme der Deutsche Gesellschaft für Zahn-, Mund und Kieferheilkunde*.
4. Haas R, Baron M, Dortbudak O, Watzek G (2000) Lethal photosensitization, autogenous bone, and e-PTFE membrane for the treatment of peri-implantitis: preliminary results. *Int J Oral Maxillofac Implants*, 15: 374–382.
5. Hammerström L (1997) Enamel matrix, cementum development and regeneration. *J Clin Periodontol*, 24: 658–668.
6. Heijl L, Helden G, Svardstrom G, Ostgren A (1997) Enamel matrix derivate (EMDOGAIN®) in the treatment of intrabony periodontal defects. *J Clin Periodontol*, 24: 705–714.
7. Horch HH, Sader R, Kolk A (2004) Synthetische, phasenreine Beta-Trikalziumphosphat-Keramik (Cerasorb) zur Knochenregeneration bei der rekonstruktiven Chirurgie der Kiefer-Eine klinische Langzeitstudie mit Literaturübersicht. *Deutsche Zahnärztliche Zeitschrift*, 59: 680–686.
8. Mellonig JT (2000) Human histologic evaluation of a bovine-derived bone xenograft in the treatment of periodontal osseous defects. *Int J Periodontics Restorative Dent*, 20: 19–29.
9. Nevins ML, Camelo M, Rebaudi A, Lynch SE, Nevins M (2005) Three-dimensional micro-computed tomographic evaluation of periodontal regeneration: a human report of intrabony defects treated with Bio-Oss collagen. *Int J Periodontics Restorative Dent*, 25: 365–373.
10. Nociti FH Jr, Machado MA, Stefani CM, Sallum EA (2001) Absorbable versus nonabsorbable membranes and bone grafts in the treatment of ligature-induced peri-implantitis defects in dogs: a histometric investigation. *Int J Oral Maxillofac Implants*, 5: 646–652.
11. Schwenzer N, Ehrenfeld M (2000) Zahn-Mund-Kiefer-Heilkunde. Lehrbuch zur Aus- und Weiterbildung Bd. 1-3, 3. Aufl. G. Thieme Verlag, New York.
12. Sculean A, Willershausen B (2004) Regenerative parodontaltherapie. *Quintessenz*, 55: 491–499.
13. Siervo S, Coraini C, Siervo P, Giardini R (2001) Cerasorb® und PRP in der regenerativen parodontalen und implantatunterstützten Therapie. *Implantologie J*, 6: 49–58.
14. Soost F (1996) Biocoral — an alternative bone substitute. *Chirurg*, 67: 1193–1196.
15. Wolff KD, Swaid S, Nolte D, Bockmann RA, Holzle F, Muller-Mai C (2004) Degradable injectable bone cement in maxillofacial surgery: indications and clinical experience in 27 patients. *J Cranio-Maxillofac Surg*, 32: 71–79.