

Critical considerations on the diagnostic appraisal, adaptation and remodelling of bone graft substitutes

T. Gedrange¹, T. Bayerlein¹, J. Fanghänel¹, P. Landsberger¹, A. Hoffmann¹, E. Kauschke², E. Rumpel², W. Gerike³, V. Bienengräber⁴, P. Proff¹

¹Clinic for Orthodontics and Preventive and Paediatric Dentistry, University of Greifswald Dental School, Greifswald, Germany

²Institute of Anatomy and Cell Biology, Ernst Moritz Arndt University, Greifswald, Germany

³Artoss GmbH, Rostock, Germany

⁴Clinic for Cranio-Maxillofacial and Plastic Surgery, University of Rostock, Germany

[Received 21 December 2005; Accepted 8 February 2006]

The diagnostic assessment of skeletal defects has a long-standing tradition. As a result of the development of new bone grafting materials, the demands on diagnostic assessment have also increased. The mode and quality of diagnostic appraisal are crucial to further clinical use and outcome prediction. Alongside traditional clinical and biological techniques, molecular biological methods have gained a broad scope of application and will be used even more frequently in the future.

Key words: bone, bone graft substitutes, diagnostics

INTRODUCTION

The development and application of bone grafting substitutes has been established as an independent subject of biomedical research during recent years. The treatment of skeletal defects, however, has a long-standing tradition. Successful bone grafting was reported as early as 1670 [3, 4]. Since the quantity of autogenous tissue is limited, the production of artificially grown bone, which has thus far only rarely been studied, provides, beside alloplastic bone substitutes and the so-called "allografts", an alternative to autogenous grafts in craniofacial reconstruction.

Moreover, the utilisation/stress ratio, even in small osseous defects, argues for the use of foreign materials. Numerous implanted materials from several physically and chemically different groups are a complement to tissue engineering with respect to tissue regeneration. The scope of bone substitute materials far outreaches medical application alone. All fields

of dentistry have been using bone graft substitutes for varying periods of time. Alongside maxillofacial and plastic surgery, where bone substitute materials have already become established, recent areas of application have included both periodontology and orthodontics.

The huge variety of bone substitute materials clearly demonstrates the importance not just of the correct use but also of the diagnostic assessment of material acceptance and surrounding tissue reactions. Since no ideal bone substitute product has been found thus far, the search for suitable bone graft substitutes still continues.

MATERIAL AND METHODS

The quality of newly formed bone and the temporal dynamics of new formation in bone tissue require exact diagnostic assessment. Clinical diagnostics is among the oldest methods for appraisal of the healing process. Macroscopic determination of

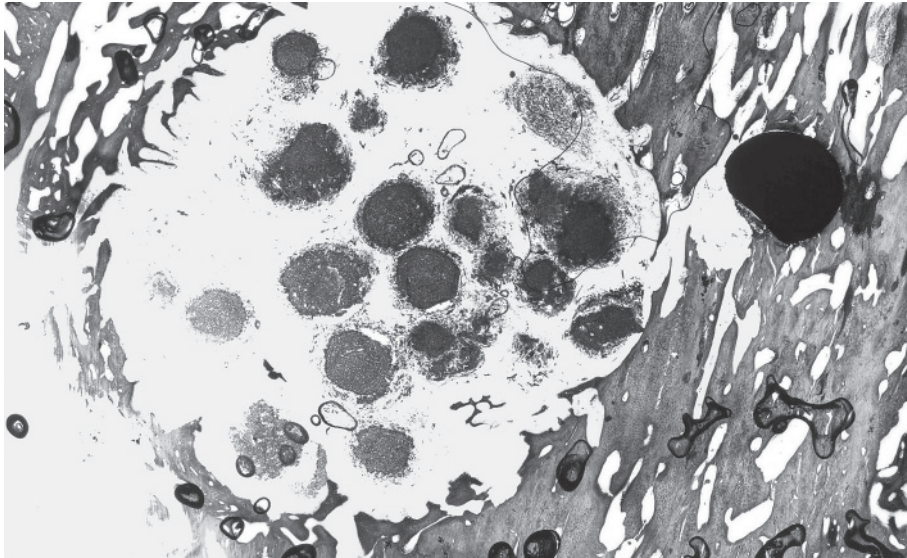


Figure 1. Histological specimen of a 1.2 cm bone defect filled with Cerasorb® (Curasan Pharma GmbH, Kleinostheim) after 50 days' healing time.

morphological changes provides a first impression and clues to the necessity of further examination (Fig. 1). An inflammatory process can be diagnosed clinically from its cardinal symptoms, thus providing clues to possible disturbed healing. However, the use of clinical examination alone is no longer sufficient.

Another option for revealing bone changes is provided by x-ray examination. From a comparison of preoperative and postoperative images (preferably using identical x-ray projections and fluoroscopic energies), radiographs permit immediate appraisal of postoperative results, as well as quantification of changes. Sequential images enable resorption and remodelling processes over pre-defined intervals of time to be appraised and recorded. Changes in the blackening intensity of the x-ray film indicate changes of bone density. Determination of bone density (osteodensitometry) is a method for determining bone mineral content. Radiation attenuation is assessed during bone passage in comparison to a reference body with known mineral density. This non-invasive examination method and analysis is a routine diagnostic technique performed on all patients.

Conventional x-ray images such as tooth films are best suited to retrospective assessment of the surgical outcome of small defect treatment. The most frequently used imaging technique for the appraisal of larger defects is orthopantomography (OPTG) [1] (Fig. 2). The orthopantomograph provides a panoramic overview of the upper and lower jaw, including the temporomandibular joints and

parts of the maxillary sinuses. This imaging technique is suited to following up bone grafts, despite the method-specific linear blurring with projection of the spine and various distortions of the single imaged areas. Much more accurate determination of change is provided by computed tomography (CT), which permits discrimination of structures displaying smaller density differences as compared to conventional radiographic diagnostics. Images are produced by computer-assisted calculation after radiography of predefined areas using a "tomographic" procedure. Common layer thickness range from 1 to 10 mm. Three-dimensional imaging (3D-CT) of the cranial bone allows a clear and comprehensive appraisal of grafting outcome and volume [2]. For cost reasons and because of radiation exposure, this procedure is not primarily suitable for routine follow-ups. Furthermore, a similar mineral composition found in native bone and bone grafting substitutes complicates exact discrimination of the two structures, also noticeable in conventional radiography.

The best method for appraisal of cellular alterations is provided by histological examination, although this is inappropriate for routine diagnostics in humans owing to its invasive nature. This type of examination has been used in animal studies of bone substitute tolerance. Since the hydroxyapatite ceramics used for bone substitute materials are insoluble and very hard, the histological specimens are produced by means of the "sawing and grinding" technique. The whole bone area is embedded in a plastic

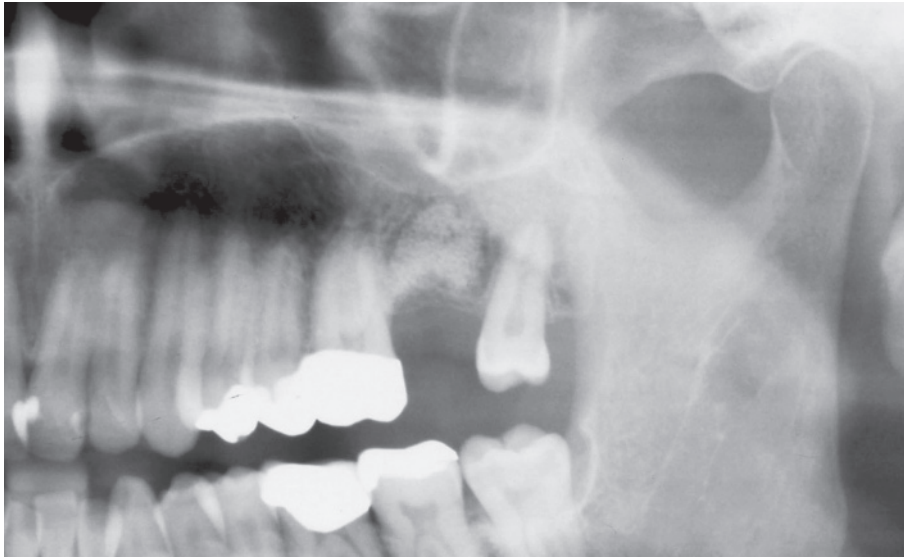


Figure 2. Detail of orthopantomographic image. Alveolus filled with Cerasorb® in region 27.

block sawn and ground to the appropriate thickness. Histological examinations have been enhanced by polychrome sequence marking and clearly reflect the healing process. Beside cellular changes, the contour, shape and structure of the grafted bone are also evaluated. In addition, evidence of revascularisation and revitalisation of free spongy bone grafts is possible using this method.

Another method for the assessment of bone changes after the application of a substitute material is based on measurement of metabolic activity in this area. Metabolic processes may be reflected by nuclear magnetic resonance imaging. This kind of examination is primarily used for assessment of soft tissue structures, while its use for assessment of bone structures and dimensions is limited. The P^{37} coil yields 3D imaging of different phosphate compounds. Since phosphates are actively involved in cell metabolism, this permits visualisation of processes with increased metabolism. The application of radioactively labelled substances that show a specific affinity for bone tissue and are attached to skeletal areas with distinct changes enables the dynamics of bone metabolic processes to be imaged. Skeletal scintigraphy, whose validity is based on an increased bone remodelling rate rather than on changes of mineral content as in conventional radiography, utilises technetium-labelled phosphate complexes. These osteotropic nuclides show a strong affinity for vital osteoblasts. Thus the extent of accumulation in a bony region reflects the osteoblast activity of bone turnover [5]. These nuclear medical techniques not only permit the examina-

tion of osteogenetic dynamics following bone grafting or implantation of bone substitutes but also enable conclusions to be drawn regarding mineralisation. With the use of this method the extent and kinetics of physiological and pathological bone remodelling processes can be assessed qualitatively and semi-quantitatively as well as visualised. The disadvantage of this sensitive nuclear medical examination method is its low selectivity in combination with limited resolution, which clearly restricts its diagnostic validity.

The future of diagnostics lies in the molecular biological detection of changes. Molecular biological methods are very well suited to diagnosing the acceptance of bone grafting substitutes. The small amount of sample required for measurement ensures a minimal burden for the patient and, therefore, an optimal healing process. These methods permit examination of bone changes either on the protein or on the mRNA level. Nowadays immunological detection methods such as western blot or 2D electrophoresis are used to determine bone protein composition. Bone diagnostics on the mRNA level has developed greatly over recent years. Techniques based on reverse transcription, such as competitive RT-PCR and real-time PCR, are used as standard methods. Further progress in bone diagnostics is provided by Gene Chip Arrays (Affymetrix Inc.). These chips enable parallel expression analysis of up to 50.000 in a single array. The great variety of genes analysed permits interrelations between the processes that take place during the adaptation and remodelling of bone grafting substitutes to be charted. In this context many studies show that growth and

differentiation factors markedly contribute to the regulation of bone development and maturation. Thus there is need for chip application and the amount of information it provides. Furthermore, individual differences in adaptation are demonstrated and explained more clearly using the Affymetrix expression arrays.

DISCUSSION AND PROSPECTS

The variety of diagnostic options clearly shows that interdisciplinary co-operation is required not only for treatment but also for diagnostic assessment. Diagnostic assessment should ideally yield the representation of the healing process that is necessary for the application of bone substitutes in various areas of dentistry. It permits, beside therapy prognosis, intervention when a deviation occurs from the intended course of treatment.

REFERENCES

1. Herzog M, Horch HH, Wegner T, Rudzki-Janson I (1993) Röntgenbefunde nach sekundärer bzw. tertiärer Osteoplastik bei Lippen-Kiefer-Gaumenspalten. *Fortschr Kiefer Gesichtschir*, 38: 64–66.
2. Jensen J, Sindet-Pedersen S, Oliver AJ (1994) Varying treatment strategies for reconstruction of maxillary atrophy with implants: results in 98 patients. *J Oral Maxil Surg*, 52: 210–216.
3. Lindqvist C, Kaartinen E, Santavirta S (1985) Knochentransplantationen in der Chirurgie und Kieferchirurgie. Eine Übersicht. *Zahn Mund Kieferheilkd*, 73: 291–300.
4. Prolo DJ, Rodrigo JJ (1985) Contemporary bone graft physiology and surgery. *Clin Orthop*, 200: 322–342.
5. Winkel K (1990) *Nuklearmedizin*. Springer, Berlin Heidelberg New York.