

This is a provisional PDF only. Copyedited and fully formatted version will be made available soon.



ISSN: 0015-5659

e-ISSN: 1644-3284

Rare morphological variants of the bones: epicondylar processes, metopic suture and Wormian bones in XVIII century skeleton

Authors: Jacek Kuchinka, Tadeusz Kuder, Aleksander Szczurkowski, Elżbieta Nowak, Waldemar Gliński, Jarosław Kwieciński

DOI: 10.5603/FM.a2019.0055

Article type: CASE REPORTS

Submitted: 2019-03-29

Accepted: 2019-04-09

Published online: 2019-05-10

This article has been peer reviewed and published immediately upon acceptance. It is an open access article, which means that it can be downloaded, printed, and distributed freely, provided the work is properly cited.

Articles in "Folia Morphologica" are listed in PubMed.

Rare morphological variants of the bones: epicondylar processes, metopic suture and Wormian bones in XVIII century skeleton

Running head: Epicondylar process and metopic suture

J. Kuchinka¹, T. Kuder², A. Szczurkowski¹, E. Nowak¹, W. Gliński³, J. Kwieciński⁴

¹Department of Comparative Anatomy, Institute of Biology, Jan Kochanowski University, Kielce, Poland

²Department of Anatomy, Institute of Medical Science, Jan Kochanowski University, Kielce, Poland

³Archaeological Research Laboratory, Kielce, Poland

⁴Private Dental Practices, Kielce, Poland

Address for correspondence: J. Kuchinka, Department of Comparative Anatomy, Institute of Biology, Jan Kochanowski University in Kielce, ul. Świętokrzyska 15, 25–406 Kielce, Poland, e-mail: jacek.kuchinka@ujk.edu.pl

Abstract

Analysis of the female skeleton from the eighteenth century revealed a collection of morphological changes. Anthropological evaluation and dental X-ray techniques allowed the age to be determined at 12-13 years. The distal parts of the both humerus bones had distinct, supracondylar processes of about 5 mm at the medial-lateral surface. The frontal bone had a well-preserved metopic suture along the entire length of the squama. There were also two Wormian bones (Inca bones), asymmetrical mastoid foramen, and only left non-obliterated condylar canal. The skull measurements allowed the cranial index to be determined – 93.5 (*brachycephalia*) and height-length index – 98.6 (*akrocephalus*). Moreover, X-ray analysis of incomplete dentition was made.

Key words: morphological varieties of skeleton, epicondylar process, metopic suture

Introduction

Bone material analysis from archaeological excavations can provide a wealth of information on the morphological structure of the skeleton and its morphological variations or disorders of the movement apparatus [16]. The presented research concerns the analysis of the skeleton of a juvenile individual with rare morphological forms. During ontogenesis, a series of changes that manifest in the postnatal life may already occur at the stage of organogenesis. Very often they refer to bone tissue, when the process of osteogenesis is disturbed and morphological forms of skeleton are created. One such example is the presence of the metopic suture associated with a disorder of fusing the two parts of the frontal bone. The presence of this structure in adults was described by a number of authors in various groups of people [1, 4, 5, 8, 10, 24]. The persistent metopic suture is clinically important and should be included in the diagnosis of a skull fracture [10].

The creation of additional ossification centres may lead to changes in the type of Wormian bones (Inca bones). In turn, some of the morphological variations may be the result of disorder in the development processes and constitute embryological remains from our ancestors. This type of morphological change includes the occurrence of the epicondylar processes, normally present in reptiles, animals climbing trees, some marsupials, lemurs, cats, wide-nosed monkeys, and occasionally in man [18, 22]. The epicondylar process (*processus epicondylaris*) has long attracted the attention of anatomists, anthropologists, and physicians. It is a primitive homologue of the epicondylar and trochlear foramen sometimes occurring in vertebrates [22].

The presence of the epicondylar process may leads to clinical problems, such as incarceration of the median nerve and / or brachial artery caused by the presence of the Struthers ligament or "high" division of the brachial artery [6, 23]. The epicondylar process is often mistakenly regarded as a pathological bone condition and not as an example of anatomical variation. However, this change has its clinical implications, as it is usually associated with the symptoms of median nerve compression and claudication of the brachial artery [6, 12, 23].

Morphological changes of the skeleton usually occur one at a time, whereas their accumulation in one individual raises the question of whether it is still an individual variation or perhaps some clinical case? Therefore, a precise analysis of this case is interesting from a morphological and clinical point of view and is fully justified.

Materials and methods

During the inventory of osteological material belonging to 150 individuals from archaeological excavations on the church square of St. Wojciech in Kielce, conducted by the Archaeological Research Laboratory Waldemar Gliński [11], three humerus bones with preserved epicondylar processes were found. The burials came from the 17th century cemetery. Two humerus bones with epicondylar processes belonged to one individual. Moreover, bones of his forearm, pelvis, shoulder, and a complete skull have also been preserved. A careful analysis of the bones of this individual showed the presence of other rare morphological features. Bone morphometry, including epicondylar processes, was performed using anthropological instruments. In order to determine the exact age (teeth age) of the individual, alveolar processes of the maxilla and mandible were examined with an X-ray method using dental apparatus Carestream CS 2200 (KODAK 2200).

Results

Detailed investigations of the skeleton of one juvenile individual revealed several morphological variants. On the skull non-obliterated cranial sutures and spheno-occipital fissure were visible. Moreover, the epiphysis and shaft of the humerus, forearm bones, shank bones, and pelvic bones were not grown together. These features indicate the youthful age of (*Juvenis*), to be about 12-13 years old. Taking into account the dimorphic features of the skeleton the sex of the individual was determined as female.

Epicondylar process (*processus epicondylaris*)

The presence of distinct epicondylar processes was found on both humeri. They were present placed on the medial-lateral side of the distal part of the humeri, 25.4 mm above the trochlea (connection line) on the left humerus and 29.4 mm on the right bone, respectively (Fig. 1). The process on the left side was in the form of a downward curved bone structure 5.5 mm in length and with base dimensions of 17.8 mm x 4.0 mm. The epicondylar process on the right humerus was more massive, also curved downwards and measured 5.3 mm in length and its base had dimensions - 11.7 mm x 3.5 mm. Additionally, in the examined bone material, the left humeral bone of an adult female with the epicondylar process present was also found. The process here was in the form of a bony eminence, 4.2 mm in length and its base dimensions were 37.0 mm x 5.0 mm. Unfortunately, no other bones of this individual were found, therefore her presence was included only to calculate the frequency of occurrence. Moreover, dimensions of long bones (without epiphysis) are shown in Table 1.

Taking into account the above data, an attempt was made to determine the body height based on the Najnys formula, which was approximately 144 cm [17].

Morphological changes of the skull

The frontal bone had a preserved complete metopic suture (*sutura metopica*) with a wavy course, extending from the *nasion* point to the bregma point (Fig. 2). The degree of corrugation increased in its upper part. In addition, the Wormian bones (Inca bones) were found in the right part of the lambdoid suture and in the left parietomastoid suture. Moreover, the asymmetrical condylar canal was found. On the left side it was properly formed, while on the right side it was only slightly marked on the external surface of the bone as a result of stenosis. Lateral variability of the mastoid foramen was also observed; it was located lower on the right than on the left side.

The skull had a spheroidal shape with some asymmetry of the parietal bones visible in the superior aspect, and the convexity in the region of the parietal tumour on the right bone is greater than the analogous convexity on the left bone. The skull was relatively flat in front of the parietal bones. Particularly on the right parietal bone is marked a small lowering (up to 2 mm). It runs parallel to the coronal suture, approximately 2 cm away from it. The cephalic index was 93.5, indicating a very short skull. In turn, the cranial height-length index was 89.6, which is characteristic for high-head skulls. The head circumference was 48.7 cm.

Dental analysis

Both in the mandible and maxilla 12 fully developed teeth were found. In addition, further teeth in the erupting phase were also visible. All teeth on the right side were the permanent teeth. On the left side, the fifth tooth of the dental arches was still a milk tooth (m2 - 65, 75). The images of x-ray examinations show advanced root resorption and eruptive permanent teeth (P2 - 25, 35) with shaped roots but still with unclosed tops (stage G) (Fig. 3). The alveolar processes of maxilla and mandible show the second molars (M2-17, 27, 37, 47, 77) in the pre-functional eruption phase. The crowns of these teeth were shaped, and roots were in the process of forming with length equal to the crown height (stage F). In the maxilla near the maxilla tuber on the right side, the crown of the wisdom tooth (M3 - 18) in the pre-eruptive phase was visible and on the left side there was no third molar tooth bud. On both sides, the first permanent molars of the maxilla, and on the left side of the mandible (16, 26, 36), medium advanced carious lesions are visible (1 class according to Black). There was no evidence of intravital tooth defects. The dental formula (FDI) of the examined skull,

according to the numbering of the World Health Organization, is presented in Table 2. Taking into account the above data, the dental age of the examined skull can be estimated to be about 12-13 years old.

Discussion

The epicondylar process is an example of the morphological variability within the humerus. It is located in the lower part of the humerus on its medial margin, a few centimetres from the medial epicondyle. It is a primitive homologue of the supracondylar foramen and supratrochlear foramen sometimes occurring in vertebrates, e.g. in lemurs, marsupials, and some felids [15, 18, 22]. In the felids, the epicondylar process forms a kind of roof over the supratrochlear foramen through which the blood vessels and nerve fibres pass. It forms a type of protection and gives a strong structure for the pronator teres muscle attachment [2]. Sometimes, a supratrochlear foramen may also appear in man [14, 19], and sometimes also an epicondylar process [12, 22]. Some authors try to correlate the incidence of this rare anatomical variety with individual races. However, according to Gupta and Mehta [12], the data on this topic are equivocal, and the incidence of epicondylar processes ranges from 0.1% to 2.7%. It seems that its frequency of occurrence may be slightly higher because there is a lack of a complete data on this subject. In the present studies, where 3 bones with epicondylar process were found in 150 individuals (two belonged to the one individual described) the incidence rate is 1.3 %. The Struthers ligament attaches to the epicondylar process and forms a fibrous band reaching the medial epicondyle of the humerus. A part of the pronator teres muscle is attached to it. Between the Struthers ligament and the medial margin of the humerus there is a space for the median nerve and the brachial artery. This may cause symptoms of median nerve compression (pronator teres syndrome) and claudication of the brachial artery or its "high" division. In this way, this rare anatomical variability acquires clinical significance, because it can cause paraesthesia and ischemic pain in the forearm and hand, and sometimes even the need for surgical decompression [6, 23]. This variability is also described as one of the possible coexisting features in the Cornelia de Lang syndrome [20]. Therefore, knowledge about morphological variability of bones is important not only for anthropologists but also for anatomists, radiologists, surgeons, or orthopaedists.

It is known that the frontal bone has two ossification points in development and initially consists of two bone plates, connected with frontal suture or metopic suture. Some authors believe that this is the adaptation of a big fetal head to the delivery and fast brain growth in the first years of life. Others suggest that it is associated with the active expression

of cytokines during the development of cranial bones [9, 10]. Usually, in the first or second year of life, the obliteration process of metopic suture begins. There are also reports that this process may last up to 7 years old [3]. The ossification starts from the nasal bone and gradually goes up to the *bregma* point. As can be seen from the literature, however, a persistent metopic suture is seen relatively often in adults. The authors give the range of this variability from 1 to 38% (Table 3). There have been various attempts to correlate this morphological variability with other features. According to some authors, the metopic suture is more commonly found on female skulls [7, 10]. According to the studies of Castillio et al. [7], it was found in 60.9% of women in relation to 31.1% of men. The present case is consistent with this relationship. It can be found in literature that in the case of persistent metopic suture, there may be disturbances in the development of frontal sinus [8]. However, studies by Bilgin et al. [5] did not show significant statistical differences in this respect. There are also data according to which the metopion is more common on short-headed skulls [8]. This case could also confirm the existence of such a dependency. The hypothesis in the literature [7] of the increased incidence of metopic series in tall individuals seems unlikely. There is discrepancy in the data regarding the metopic suture progression. According to Castillio et al. [7] it had a 69% rectilinear course, while most authors noted a wavy or serrated course [5, 10, 21]. It was similar in the described case of the metopic seam; it initially had a wavy course, becoming more serrated in the upper part of frontal bone.

Insertion bones (Wormian bones), or Inca bones, have been known for a long time. Various relationships between Wormian bones and congenital anomalies are described in the literature. Although the mechanisms responsible for the formation of these bones are unknown, some researchers indicate that their presence in the form of big structures may serve as a marker to identify anomalies of the central nervous system. Smaller insertion bones are an expression of individual variation [13]. In the analysed case, these were small bones, which are rather a manifestation of frequent individual variability and not pathological changes. The more so because the analysed skull and other bones of the limbs, although they represent numerous morphological variants, are generally located in the so-called widely understood morphological norm.

Summing up, it should be noted that although morphological variability is a common phenomenon affecting each system, the frequency of specific variants varies. The morphological variations of the skeleton described in this study are usually Wormian bones, asymmetries of foramens, or their stenosis. A metopic suture is a relatively rare feature, affecting only about 10% of individuals. The most rarely occurring morphological variant is

the epicondylar process. Its presence on two humeri in the same individual is extremely rare. In turn, the accumulation of all these morphological variations in one individual is virtually unheard of. Admittedly, Das et al. [8] describe the coexistence of the Wormian bone and only partially preserved metopic suture in one individual, however, this is definitely a smaller degree of variation than the skeleton analysed in the present study. This raises the question of whether this is a manifestation of such high variability, or perhaps a non-described clinical case? After a thorough and comprehensive analysis, in the opinion of the authors it may be the result of certain developmental disorders in the prenatal period, caused by malnutrition, maternal illnesses, or other factors occurring at the turn of the seventeenth/eighteenth century. A disturbance at the organogenesis stage would also be supported by the fact that the bones of the postnatal period showed a lack of lesions. However, it should be noted that bone analysis did not show any disorders or malnutrition.

An important conclusion resulting from this work is that knowledge about these rare morphological variants of the skeleton, besides the cognitive aspect, has practical significance and can be used in radiology, neurosurgery, or orthopaedics.

References

1. Agarwal SK, Malhotra VK, Tewari SP. Incidence of the metopic suture in adult Indian crania. *Acta Anat (Basel)*. 1979; 105: 469-474.
2. Aydinlioglu A, Cirak B, Akpınar F, Tosun N, Dogan A. Bi lateral median nerve compression at the level of Struthers' ligament. *J Neurosurg*. 2000; 92: 693-696, DOI: 10.3171/jns.2000.92.4.0693
3. Baaten PJ, Haddad M, Abi-Nader K, Abi-Ghosn A, Al-Kutoubi A, Jurjus AR. Incidence of metopism in the Lebanese population. *Clin Anat*. 2003; 16:148-151 DOI: 10.1002/ca.10050
4. Bergman RA, Afifi AK, Miyauchi R. *Compendium of human anatomical variation: text, atlas and word literature*. Baltimore. Urban & Schwarzenberg. 1988; 41:282-288
5. Bilgin S, Kantari UH, Duymus M, Yildirim CH, Ercakmak B, Orman G, Gunenc Beser C, Kaya M, Gok M, Akbasak A. Association between frontal sinus development and persistent metopic suture. *Folia Morphol (Warsz)*. 2013; 72(4): 306-310, DOI: 10.5603/FM.2013.0051

6. Casadei R, Ferraro A, Ferruzzia A, Innao V, Mercuri M. Supracondylar process of the humerus: four cases. *Chir Organi Mov.* 1990; 75(3): 265-267
7. Castillo SMA, Oda YJ, Santana GDM. Metopism in adult skulls from Southern Brazil *Int J Morphol.* 2006; 24: 61-66
8. Das S, Suri R, Kapur V. Anatomical observations on *os inca* and associated cranial deformities. *Folia Morphol (Warsz).* 2005; 64(2): 118-121
9. Falk D, Zollikofer CPE, Morimoto N, de Leonc MSP. Metopic suture of Taung (*Australopithecus africanus*) and its implications for hominin brain evolution. *Proc Nat Acad Sci.* 2012; 109: 8467-8470, DOI: 10.1073/pnas.1119752109
10. Gardner S. A persistent metopic suture: A case report. *Austin J Anat.* 2016; 3(1): 1049-1050
11. Gliński W, Glińska N. Plac św. Wojciecha w świetle badań archeologicznych, przeprowadzonych w 2006-2007 roku. *Rocz. Muzeum Narodowego w Kielcach.* 2012, 27: 229-270
12. Gupta RK, Mehta CD. A study of the incidence of supracondylar process of the humerus. *J Anat Soc India.* 2008, 57: 111-115
13. Jeanty P, Silva SR, Turner C. Prenatal diagnosis of wormian bones. *J Ultrasound Med.* 2000; 19(12):863-9.
14. Hima BA, Narasinga RB. Supratrochlear foramen – a phylogenic remnant. *Int J Basic App Med Sci.* 2013; 3(2): 130-132
15. Laburthe-Tohra Y, Barbet P, Kalifa G, Duboussed J, Seringe R, Godinot M. Radiographies foetales post-mortem of processus supracondyliare de l'humerus. e-mémoires de l'Académie Natl Chir. 2007; 6(3) : 96-102
16. Lorkiewicz W, Teul I, Zasadzka P, Borucki A. Przyczynek do historii medycyny w Polsce: Szczątki kostne z cmentarzyska przyszpitalnego z XIV-XVIIIw. W Łęczycy (woj. łódzkie). *Ann Acad Med Stetinensi.* 2011; 57(1): 113-116
17. Najnys JV. Identyfikacja liczebności według kości kończyn (in russ), Vilnius. 1972.
18. Nikumbh RD, Nikumbh DB, Doshi MA, Ugadhe MN. Morphometric study of the supracondylar process of the humerus with its clinical utility. *Int J Anat Res.* 2016; 4 (1): 1941-1944

19. Papaloucas Ch, Papaloucas M, Stergioulas A. Rare cases of humerus septal apertures in Greeks. Trends Med Res. 2011; 6(3): 178-183, DOI: 10.3923/tmr.2011.178.183
20. Peeters FL. Radiological manifestations of the Cornelia de Lange syndrome. Pediatr Radiol. 1975; 24(3): 41-46
21. Skrzat J, Walocha W, Zawiliński J. A note on the morphology of the metopic suture in the human skull. Folia Morphol (Warsz). 2004; 63(4): 481-484
22. Shivaleela C, Suresh BS, Kumar GV, Lakshmiprabha S. Morphological study of the supracondylar process of the humerus and its clinical implications. J Clin Diag Res. 2014; 8(1): 1-3
23. Subasi M, Kesemenli C, Necmiogulu S, kapukaya A, Demirtas M. Supracondylar process of the humerus. Acta Orthop Belgica. 2002; 61(1): 72-75
24. Woo JK. Ossification and growth of the human maxilla, premaxilla and palate bone. Anat Rec. 1949; 105: 737-761

Table 1. Dimensions diaphysis of long bones (cm).

Bone	Right (cm)	Left (cm)
<i>Femur</i>	31,5	31,0
<i>Humerus</i>	22,6	22,3
<i>Radius</i>	15,9	16,3
<i>Ulna</i>	18,4	18,0

Table 2. Dental formula (FDI) of investigated skull according to the numbering and registration of the World Health Organization.

<u>16,15,14,13,12,11</u>	<u>21,22,23,24,65,26</u>
46,45,44,43,42,41	31,32,33,34,75,36

Table 3. Frequency of metopic suture in different populations according to different authors.

Population	% of occurrence	Author
Blacs	1	Bergman et al. 1988
Asians	5	Bergman et al. 1988

Polish	9,7	Skrzat et al. 2004
Turkey	9,7	Biling et al. 2013
Mongoloid	10	Woo 1949
Czech	11	Woo 1949
Indians	38,17	Agarwal 1979
	5,5	Das et al. 2005

FIGURES AND LEGEND

Figure 1. Right and left humeral bones with epicondylar processes.

Figure 2. Skull in *norma anterior*. Completely metopic suture is visible.

Figure 3. RTG images of maxilla – left side with advanced root resorption ($m_2 - 65$) and eruptive permanent teeth ($P_2 - 25$).



Fig. 1

10 mm

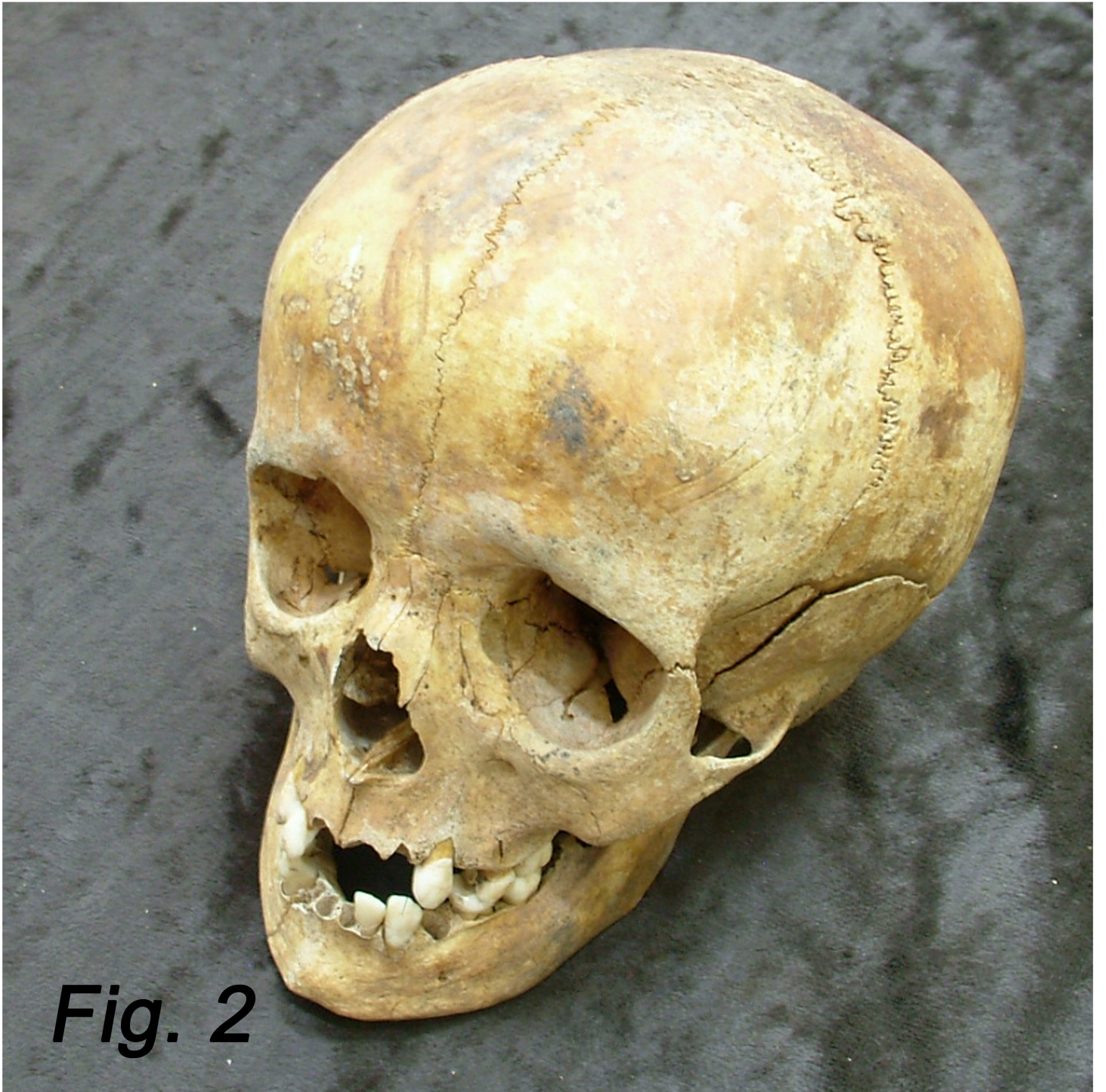

Fig. 2

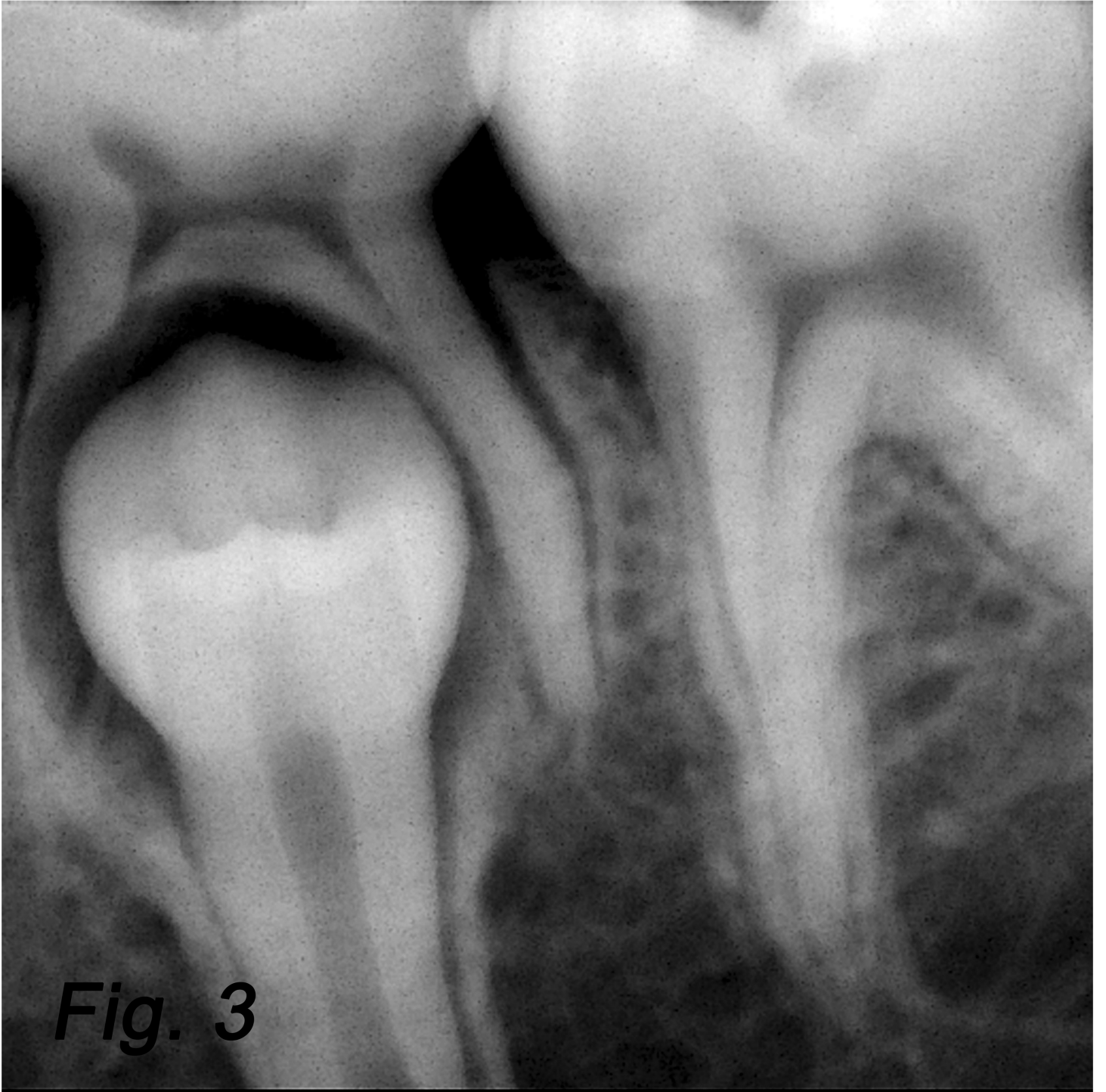


Fig. 3