

ONLINE FIRST

This is a provisional PDF only. Copyedited and fully formatted version will be made available soon.



ISSN: 0015-5659

e-ISSN: 1644-3284

## **Anatomical description of the aortic arch of a rare species "the giant armadillo" (*Priodontes maximus* - Kerr, 1792): a case report**

**Authors:** Rosany Santos, Mayara Fernandes, Soraia Figueiredo de Souza, Carlos Augusto dos Santos-Sousa, Yuri Karaccas de Carvalho

**DOI:** 10.5603/FM.a2019.0053

**Article type:** CASE REPORTS

**Submitted:** 2019-03-20

**Accepted:** 2019-04-19

**Published online:** 2019-05-06

This article has been peer reviewed and published immediately upon acceptance. It is an open access article, which means that it can be downloaded, printed, and distributed freely, provided the work is properly cited.

Articles in "Folia Morphologica" are listed in PubMed.

## **Anatomical description of the aortic arch of a rare species "the giant armadillo"**

**(*Priodontes maximus* - Kerr, 1792): a case report**

The aortic arch of the giant armadillo

**Rosany Santos, Mayara Fernandes, Soraia Figueiredo de Souza, Carlos Augusto dos Santos-Sousa, Yuri Karaccas de Carvalho**

Federal University of Acre, Rio Branco, Brazil

**Address for correspondence:** Yuri Karaccas de Carvalho, Federal University of Acre, BR 364 road, KM 4, 69915000 Rio Branco, Brazil, e-mail: ykaracas@yahoo.com.br

### **Abstract**

The giant armadillo (*Priodontes maximus*) is found in diverse habitats from South America. A female adult giant armadillo with a body mass of 45 kg was used. The animal was a victim of trampling on highway AC-40, at Km 70, near the municipality of Capixaba-Acre and the corpse donated to the Animal Anatomy Laboratory at Federal University of Acre (UFAC). The arterial system was filled with natural latex by means of thoracic aorta in a direction opposite the blood flow to the description of the aortic arch and its side branches. The study was approved by CEUA/UFAC – n° 053/2015 and SISBIO n° 47124-1. The aortic arch issued side groups, which had the following sequence: brachycephalic trunk; Left carotid artery; Left subclavian artery. The brachycephalic trunk forked forming the right subclavian artery and the right common carotid artery. The arrangement allowed the whole carotid blood supply to the brain and surrounding structures present in the animal's head. The subclavian arteries, of homologous way, originated the arteries: vertebral, thoracic, and cervical costocervical trunk. The aortic arch armadillo showed a pattern the same as described for the *Euphractus sexcinctus* and different from reported to the *Dasypus novemcinctus* and *Tamandua tetradactyla*. In addition, the function assigned to each branch was the same regardless of the species with which it was compared.

**Key words:** armadillo, arteries, heart, comparative anatomy

## INTRODUCTION

The superorder Xenarthra is distinguished from the remaining superorders by the presence of additional articulations between the lumbar vertebrae, known as "xenarthrans," a name derived from the Greek *xenon* (foreign) and *arthros* (articulation). The superorder consists of placental mammals, including armadillos (the most primitive of the superorder), anteaters, and arboreal sloths, with 6–9 cervical vertebrae, depending on the species, in contrast to other mammals, which largely have 7 cervical vertebrae [1]. The giant armadillo (*Priodontes maximus*) belongs to this superorder and is also known as "armadillo-açu" (large armadillo) or "armadillo-carreta" (trailer armadillo), as it can measure up to one meter in length and weigh 60 kg. The following physical characteristics can be highlighted: a massive body owing to the presence of a large number of mobile bands, a small head, a tapered snout, a long tail with small plates, and sparse fur [2]. This animal is found in South America, east of the Andes, from Venezuela, Colombia, and Guyana all the way to Argentina, Paraguay, and Brazil. In Brazil, it is found in the midwest and in Amazonia [2]

This species has nocturnal and solitary habits [3]. According to the Brazilian Institute of Environment and Renewable Natural Resources (IBAMA), the giant armadillo is on the list of endangered species. The expansion of agriculture and strong hunting pressure are the most serious risk factors for the species [2]. Therefore, this species is listed in Appendix I of the International Trade of Endangered Wildlife Species of the Flora and Fauna (CITES).

However, no morphological data are available for this endangered species. The present study aimed to systematize and describe the lateral branches of the aortic arch and its primary branches in the giant armadillo. Results were compared to those of animal references of the same family and superorder, and even to those of wild and domestic animals.

## CASE REPORT

This study was conducted at the Federal University of Acre (UFAC) in the Animal Anatomy Laboratory of the Center of Biological and Natural Sciences and was approved by the Animal Ethics Committee of UFAC (under protocol No. 053/2015) and by the Biodiversity Authorization and Information System (SISBIO) under protocol No. 47124-1. In eight years, the

Animal Anatomy Laboratory of UFAC received only one specimen, given its rarity and vulnerability

One cadaver of a female adult giant armadillo (*Priodontes maximus*) with a body mass of 45 kg was used. The animal was a victim of trampling on highway AC-40, at Km 70, near the municipality of Capixaba-Acre, and was maintained under refrigeration until it was processed. The cadaver was positioned in right lateral decubitus and by thoracic incision the 4th, 5th, 6th and 7th ribs were removed. Its thoracic aorta was dissected *in situ* to be cannulated to wash its vascular systems with saline solution and to fix it with 10% formaldehyde solution. Immediately afterwards, its vascular system was filled with natural latex (Natex<sup>®</sup>) applied by the thoracic aorta in the opposite direction of the blood flow. It was injected until resistance emerged through the syringe plunger, in order to guarantee vascular filling. Subsequently, the cadaver was immersed in a 500 liter low-density polyethylene box containing 10% formaldehyde solution, which remained for 5 days for the complete polymerization of the latex. After this period, the cadaver was removed and washed in running water to proceed with dissection. The dissection was performed with the aid of a stereoscopic microscope and the arrangement of the lateral vessels of the aortic arch was described using the disruption-replenishment technique [4]. The nomenclature used to name the identified structures was based on the Nomina Anatomica Veterinaria[5].

The aorta of the giant armadillo originates from the left ventricle, emerges in the cranio-dorsolateral direction to the left, and forms the aortic arch. Lateral branches originate from the aortic arch in the following sequence: the brachycephalic artery, the left carotid artery, and the left subclavian artery (Fig. 1).

The first branch of the aortic arch of the giant armadillo is the brachycephalic trunk, which is located on the right antimer and branched into the following vessels a few millimeters from its origin: the right subclavian and right common carotid arteries.

The second branch of the aortic arch is the left common carotid artery. The right and left carotid arteries ascend the neck laterally, following the trachea, and reach the base of the cranium. The third branch of the aortic arch of the giant armadillo is the left subclavian artery. The right and left subclavian arteries in the giant armadillo are primarily responsible for blood

supply to the thoracic and cervical regions of the thoracic limbs. The subclavian arteries formed the vertebral artery, thoracic artery, costocervical trunk, and cervical artery.

## DISCUSSION

The organization of the aorta of the giant armadillo and the arrangement of the lateral branches originated by the aorta and described in our study was similar to that observed in the six-banded armadillo (*Euphractus sexcinctus*) [6] probably because these species belonged to the same family. However, the comparison of the giant armadillo with the nine-banded armadillo (*Dasypus novemcinctus*) indicate that these two animals differ significantly, particularly in that the aortic arch of the nine-banded armadillo forms only two brachycephalic trunks, and the common carotid arteries and subclavian arteries originate from these trunks [7]. A possible explanation for the differences between the nine-banded and giant armadillos is that the anatomical description was made based on a single specimen, which does not allow confirmation that these observations extend to all individuals of the same species.

Recently, [8] in study using ten sloths (*Bradypus variegatus*) observed that in 75% of the females and 66.7% of the males, three branches emerged: the right brachiocephalic trunk, the left common carotid artery and the left subclavian. These findings corroborate with those described in this report.

Following this comparison, considering that the lesser anteater (*Tamandua tetradactyla*) also belongs to the same superorder of the giant armadillo, Xenarthra, the brachycephalic trunk was divided into the right subclavian artery and bicarotid trunk, which in turn divided into the right and left common carotid arteries [9], and this conformation of the aortic arch differed from that observed in the giant armadillo.

The differences in conformation and arrangement of the lateral branches of the giant armadillo, family *Dasypodidae*, superorder Xenarthra, from those of other animals tend to be greater with increased phylogenetic distance of the animal species used for comparison.

According to [10] the aortic arch of the crab-eating fox (*Cerdocyon thous*) divides into the thoracic artery and brachycephalic trunk. In the capybara (*Hydrochoerus hydrochaeris*), brachycephalic trunk is the only branch of the aortic arch, and this characteristic differs from that observed in the giant armadillo, which has three branches in the aortic arch [11]. In ruminants

and horses, the brachycephalic trunk originates from the aortic arch and forms the left and right subclavian arteries and the bicarotid artery [12]. In dogs, cats, and pigs, the aortic arch divides into the brachycephalic trunk and subclavian artery [13] .

In the giant armadillo, the first branch of the brachycephalic trunk in the aortic arch forms the right subclavian artery and the right common carotid artery. In domestic animals, including cattle and horses, the brachycephalic trunk forms the right subclavian artery and the bicarotid trunk. In addition, in some domestic species, including bovine and equine species, the two carotid arteries originate from the brachycephalic trunk [14] In our study, we observed that only the right common carotid artery originates from the brachycephalic trunk, and the left common carotid artery originates directly from the aortic arch.

The left common carotid artery is the second branch of the aortic arch in the giant armadillo. The right and left common carotid arteries ascend the cervical region, reach the base of the skull, and supply blood to the animal's head. This arrangement is similar to that found in domestic [14] and wild animals, including the capybara [11], anteater [13] , and six-banded armadillo [6]. It is notable that, despite the different arrangement and emergence of the right and left carotid arteries, its function remained the same regardless of the species evaluated.

In the giant armadillo, the left subclavian artery, which is the third branch of the aortic arch, and the right subclavian artery are responsible for supplying blood to the forelimbs and the thoracic and cervical regions. This conformation is similar to that found in domestic [15] and wild animals, including the rodent *Kerodon rupestris* and the procyonid *Procyon cancrivorus* [6]. Anatomically, the disposition of the right subclavian artery in the giant armadillo is similar to that observed in swine and dogs because, in the latter two species, this artery originates directly from the brachycephalic trunk [14].

Our findings indicate that the aortic arch of the giant armadillo exhibited a pattern similar to that observed in the six-banded armadillo and differed from that observed in the nine-banded armadillo and lesser anteater. However, it should be noted that the function ascribed to each of these branches is the same regardless of the species used for comparison.

## **FUNDING**

This study was financed (Grant term n.26/2018) by the Research Foundation of the State of Acre (PPP-FAPAC/CNPq – Brazil)

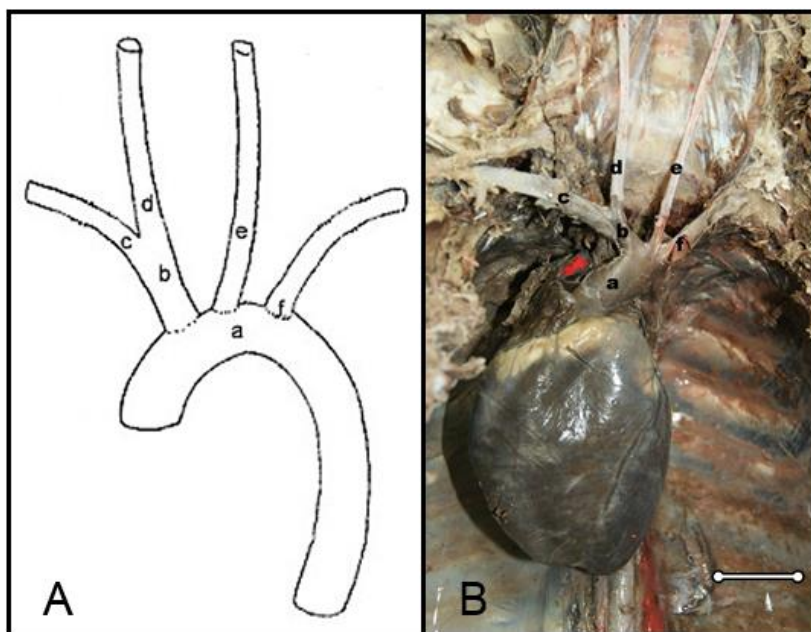
## REFERENCES

1. Dos Reis NR. Mamíferos do Brasil. Londrina; Parana: Sema, Universidade Estadual de Londrina Estado do Paraná IniFil Universidade Regional de Blumenau Shering-Plough; 2006.
2. Anacleto TCS, Marinho-Filho J. Hábito alimentar do tatu-canastra (*Xenarthra*, *Dasypodidae*) em uma área de cerrado do Brasil Central. *Revista Brasileira de Zoologia*. 2001 Sep;18(3):681–8.
3. Silveira L, Jácomo AT de A, Furtado MM, Torres NM, Sollmann R, Vynne C. Ecology of the Giant Armadillo (*Priodontes maximus*) in the Grasslands of Central Brazil. *eden*. 2009 Dec;2009(10):25–34.
4. RODRIGUES, H. Técnicas Anatômicas. Vitória: Edison Arte; 2010. 269 p.
5. INTERNATIONAL COMMITTEE ON VETERINARY GROSS ANATOMICAL NOMENCLATURE. 6º. Editorial Committee; 2017. 178 p.
6. Wilson Machado de Souza, Roberto Carvalhal, Nair Trevizan Machado de Souza, Maria Angélica Miglino, Roberto Gamerio de Carvalho. Ramos do arco da aorta no tatu peba (*Euphractus sexcinctus*). *Vet Not*. 1996;2:25–30.
7. Fantin Domeniconi R, Fernandes de Abreu MA, Benetti EJ, da Silva Villaça J. THE CONTRIBUTION OF THE AORTIC BRANCHES IN THE VASCULARIZATION OF CERVICAL REGIONS, DURING THE DEVELOPMENT OF THE NINE BANDED ARMADILLO (*Dasypus Novemcinctus*, L. 1758). *International Journal of Morphology*. 2004;22(2):113–8.

8. Albuquerque PV, Sena DGF, Braz RS, Mesquita EP, Lacerda MAS, Silva WJ, Sá FB, Amorim MJAAL. Ramos do arco aórtico e da aorta torácica em bicho-preguiça (*Bradypus variegatus*). Arquivo Brasileiro de Medicina Veterinária e Zootecnia. 2018 Aug;70(4):1203–11.
9. Pinheiro VDLC, De Lima AR, Pereira LC, Gomes BD, Branco É. Descrição anatômica dos ramos colaterais do arco aórtico do tamanduá-mirim (*Tamandua tetradactyla*). Biotemas [Internet]. 2012 May 18 [cited 2019 Mar 19];25(2). Available from: <http://www.periodicos.ufsc.br/index.php/biotemas/article/view/20839>
10. Engel S, Maiochi RR, Birck AJ, Filadelpho AL, Guimarães GC. Origem e distribuição do arco aórtico do cachorro-do mato (*Cerdocyon thous*). Rev Cient Elet Med Vet, 2013.
11. Culau P de OV, Reckziegel SH, Lindemann T, Araújo ACP de, Balzaretto F. Colaterais do arco aórtico da capivara (*Hydrochoerus hydrochaeris*). Collaterals of the aortic arch in capybara (*Hydrochoerus Hydrochaeris*) [Internet]. 2007 [cited 2019 Mar 19]; Available from: <https://lume.ufrgs.br/handle/10183/20565>
12. Rosa MC de B, Neto OJ da S, Birck AJ, Gonzalez PO, Corrêa GG. Variação dos ramos do arco aórtico em um ovino da raça Santa Inês: relato de caso = Variation of branches of the aortic arch in a Santa Ines sheep: case report. 1 [Internet]. 2011 Feb 1 [cited 2019 Mar 19];27(1). Available from: <http://www.seer.ufu.br/index.php/biosciencejournal/article/view/7350>
13. Martins DM, Lima AR, Pinheiro LL, Brígida SS de S, Araújo EB, Melul R, Jr ACCL, Meneses AMC, Souza ACB de, Pereira LC, Fioretto ET, Branco É. Descrição morfológica dos ramos colaterais do arco aórtico e suas principais ramificações em *Leopardus pardalis*. 1. 2010 Apr 23;4(2):74–7.
14. KONIG, H. E, LIEBICH, H. G. Anatomia dos Animais Domésticos–Órgãos e Sistemas. 6°. Porto Alegre: Artmed; 2016. 786 p.



15. FILADELPHO, André Luís, CAMPOS, Valêncio José de Mattos, Joffre G-F, SILVA, Ricardo de Carvalho Pinto e, ALVIM, Nivaldo César, BIRCK, Arlei José. AUSÊNCIA DO TRONCO BRAQUIOCEFÁLICO EM CÃO (*Canis familiaris*). *Rev Cient Elet Med Vet.* :7.



**Figure 1.** **A.** Schematic representation of the aortic arch of the giant armadillo (*Priodontes maximus*); **B.** Photomacrograph of the heart and aortic arch of the giant armadillo (*P. maximus*). a = aortic arch, b = brachiocephalic trunk, c = right subclavian artery, d = right common carotid artery, e = left common carotid artery, f = left subclavian artery. Bar = 2 cm.