

Persistent jugulocephalic vein: case report including commentaries on distribution of valves, blood flow direction and embryology

G. Wysiadecki¹, M. Polgúj², M. Topol¹

¹Department of Normal and Clinical Anatomy, Interfaculty Chair of Anatomy and Histology, Medical University of Lodz, Poland

²Department of Angiology, Interfaculty Chair of Anatomy and Histology, Medical University of Lodz, Poland

[Received: 9 June 2015; Accepted: 22 June 2015]

This paper is a detailed case study of the persistent anastomotic channel between the cephalic vein and the external jugular vein, running anterior to the clavicle, corresponding to the jugulocephalic vein present at early stages of the ontogenesis in humans. This connection is not only a relic of early foetal development seldom occurring in adults, but it may also be of clinical significance, increasing the risk of complications during the cephalic vein catheterisation, clavicular fractures or head and neck surgery.

The novelty in this paper was to determine the presence and distribution of valves within the persistent jugulocephalic vein. Three bicuspid venous valves were found that allowed the blood to flow only in one direction — from the cephalic vein to the external jugular vein. The anastomosis between the persistent jugulocephalic vein and the thoracoacromial veins was additionally present. Due to lack of similar data in the literature, further research should be performed on the presence and distribution of the venous valves in various types of the persistent jugulocephalic vein in humans. (Folia Morphol 2016; 75, 2: 271–274)

Key words: cephalic vein, cephalic vein catheterisation, external jugular vein, venous valves

INTRODUCTION

In the 2nd century, A.D., Galen of Pergamon transposed his observations made on monkeys onto humans and claimed that the cephalic vein (CV) (Galen's humeral vein) 'arose' from the external jugular vein and encircling the clavicle 'ran towards the periphery' [3]. Although in humans the CV typically drains into the axillary vein below clavicular level, basic literature on anatomy contains observations that it may sometimes communicate with the external jugular vein (EJV) 'via a branch anterior to the clavicle' [12]. Such a variation, developmentally corresponding to the persistent jugulocephalic

vein (JCV), is typical of some non-human primates [4, 13], and is only sporadically described in humans [4, 5, 7–11]. While examining the CV in the deltopectoral triangle, Loukas et al. [8] found a collateral branch between the CV and the EJV in 4 out of 200 limbs examined.

Upon analysis of the literature, however, we found no data on the distribution of venous valves within the persistent JCV in humans. Therefore, the purpose of this report, in addition to the detailed case study of the persistent JCV, is to determine the presence and distribution of valves in this vein.

Address for correspondence: M. Polgúj, MD, PhD, Department of Angiology, Interfaculty Chair of Anatomy and Histology, Medical University of Lodz, ul. Narutowicza 60, 90–136 Łódź, Poland, tel: +42 630 49 49, e-mail: michal.polguj@umed.lodz.pl

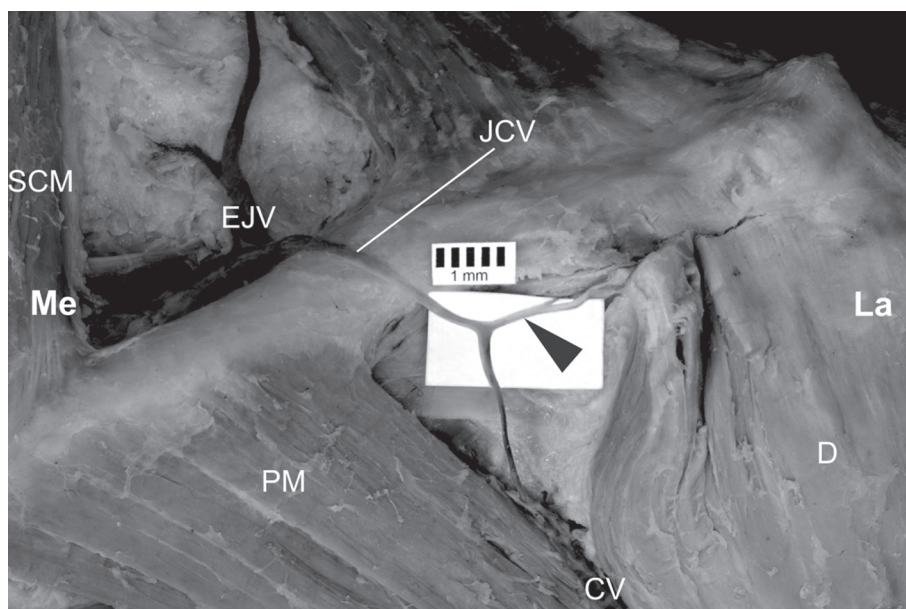


Figure 1. Persistent jugulocephalic vein (JCV) passing anterior to the clavicle. The origin of the clavicular part of the deltoid has been cut and reflected. Anastomosis between the persistent JCV and the thoracoacromial veins has been exposed; CV — cephalic vein; D — deltoid; EJV — external jugular vein; La — lateral side; Me — medial side; PM — pectoralis major; SCM — sternocleidomastoid. Black arrowhead — anastomosis with the thoracoacromial veins.

CASE REPORT

Body of a 68-year-old man was subjected to a routine dissection at the Department of Normal and Clinical Anatomy at the Medical University of Lodz. During the inspection of the left deltopectoral triangle, a persistent anastomotic channel between the left CV and the left EJV, running anterior to the clavicle was found. It corresponded to the persistent JCV (Fig. 1). The dissection was carried out with the use of traditional techniques. After visualising the JCV, it was cut lengthwise, in order to expose the valves. The presence of valves was examined *in situ*, magnified 2.5 times by means of HEINE® HR 2.5 × High Resolution Binocular Loupe (HEINE Optotechnik GmbH & Co. KG, Herrsching, Germany). The measurements were made with Digimatic Calliper (Mitutoyo Corporation, Kawasaki-shi, Kanagawa, Japan).

The total length of the persistent JCV on the examined body was 66.2 mm, whereby the vein emerged from the CV trunk, approximately 34.8 mm from the lower edge of the clavicle (Fig. 1). The JCV diameter measured at the point of emerging from the CV and at the point of opening into the EJV was 1.93 mm and 2.38 mm, respectively. The persistent JCV received anastomosis with the thoracoacromial veins 28.9 mm from the point of emerging from the CV and just before crossing the clavicle (Figs. 1, 2). The diameter

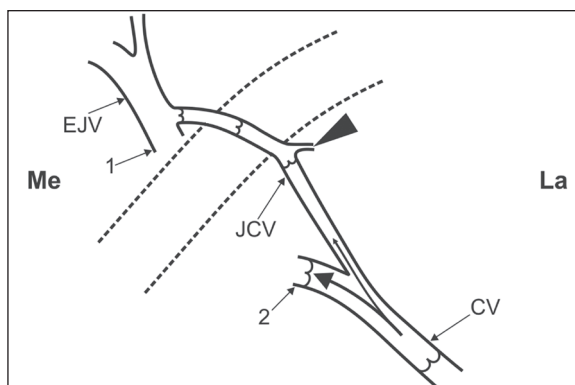


Figure 2. Schematic representation of the distribution of venous valves within the persistent jugulocephalic vein (JCV); CV — cephalic vein; EJV — external jugular vein; La — lateral side; Me — medial side; 1 — opening of the external jugular vein into the subclavian vein; 2 — opening of the cephalic vein into the axillary vein. Black arrows show the direction of the blood flow, black arrowhead shows the anastomosis with the thoracoacromial veins, dotted lines mark the location of the clavicle.

of the anastomosis was 1.55 mm. Further, the JCV coursed anterior to the lateral third of the clavicle and drained into the EJV (Figs. 1, 2). The CV diameter in the deltopectoral groove was 3.67 mm below the beginning of the JCV and 3.62 mm above the beginning of the JCV. The length of the CV in the deltopectoral groove was 89.2 mm. Within the deltopectoral triangle, the CV ran below the clavicle and

emptied into the axillary vein. The EJV diameter was 3.83 mm before receiving the JCV and 3.95 mm just after receiving the JCV.

Within the CV, the valve preceding the JCV beginning was located 40.6 mm away, while the first valve above the JCV beginning was 9.6 mm away. The said venous valves were set so as to prevent the backflow of blood to the CV. Within the JCV, one valve located right before the anastomosis with the thoracoacromial veins was detected (27.4 mm from the JCV beginning) and two valves above the anastomosis: one located 11.4 mm before the JCV opening into the EJV and the other directly at the point of the JCV opening into the EJV (Fig. 2). The valves described above were bicuspid and located so as to enable the blood to flow only in one direction — from the CV to the EJV (Fig. 2).

DISCUSSION

During the ontogeny in humans, the basilic vein emerges from the postaxial primitive vein. Subsequently, the preaxial vein develops into the CV at further stages of development [12, 14]. The preaxial vein primarily empties into the venous plexus located within the neck [15]. At the approximately 22 mm stage of embryonic development, the EJV emerges from the plexus and receives the CV as a tributary. Thus, the CV acquires a new connection with the axillary vein only at a further stage of the ontogeny, while, usually, the part of the CV running over the clavicle (the JCV) gradually atrophies [10, 15].

The developmental relationships described above explain the existence of numerous anatomic variations, including the persistent anastomotic channel between the CV and the EJV. There are reports of atypical supraclavicular course of the superficial veins in literature. In the case described by Lau et al. [7], the CV drained into the subclavian vein after a supraclavicular course. Ramírez et al. [11] evidenced a case of the CV draining into the EJV above the clavicle. Patil et al. [10] presented a case of absent EJV, where the persistent 'jugulocephalic segment' of the CV ran anteriorly to the clavicle, further opening into the subclavian vein. Kim and Han [6] presented a different case in which the EJV and the CV 'were joined to constitute a common trunk at the anterior border of clavicle' further opening below the clavicle at the point of junction of the subclavian and the internal jugular vein. A case of three superficial veins running over the

clavicles (i.e. the EJV constituting a common trunk with the CV that drained into the subclavian vein on the right side of the neck, and the EJV descending distally to drain into the subclavian vein and additional posterior external jugular vein descending to drain into the CV on the left side) was described by Anastasopoulos et al. [1]. Bergman et al. [2] describes variants where the EJV 'may pass over the clavicle and open into the cephalic', 'in some cases it forms an annulus around the clavicle' or 'receives' the CV as a tributary.

The precise examination for the presence and distribution of the venous valves may explain the way the variants specified above differ from one another in terms of blood flow direction. In the presented case, the venous valves present in the persistent JCV enabled the blood flow only in one direction — from the CV to the EJV. Due to lack of similar data in the literature, further research should be performed on the presence and distribution of the venous valves in various types of the persistent JCV in humans.

In humans the persistent JCV is not only the relic of the early ontogenetic stages, but it may also be of clinical significance. This vein may be injured during distal clavicle fractures, causing the occurrence of a haematoma [1]. Large hematomas may potentially lead to inflammation, fever, or even infection, thus causing impaired wound healing. Due to its topographical relationships, unexpected persistent JCV may also increase the risk of complications during head and neck surgery [10]. Furthermore, such anastomosis may constitute a cosmetic defect [4].

In the context of the CV catheterisation, implementing transvenous pacemaker or cardioverter defibrillator the persistent JCV or an atypical supraclavicular course of CV may cause complications. The hazards related to both above-mentioned anomalies were emphasised by: Lau et al. [7] who accentuates the possibility of 'damage to the vital structures in the thoracic inlet region', De Maria and Cappelli [5] as 'the risk of lead fracture or skin erosion over the clavicle', and Ramírez et al. [11] who added the 'lead dysfunction, erosion or collateral vascular damage' to the complications mentioned above. If persistent JCV or an atypical supraclavicular course of the CV are detected, a selection of another point of vascular access is recommended in order to avoid complications [5, 7, 11].

CONCLUSIONS

In the presented case of a persistent JCV, three bicuspid valves were observed and their location allowed the blood to flow only in one direction — from the CV to the EJV. Further research should be conducted on the presence and distribution of venous valves in various types of persistent jugulocephalic veins in humans. A persistent JCV is not only a relic of early foetal development, seldom occurring in adults, but it may also be clinically relevant, as it increases the risk of complications during cephalic vein catheterisation, clavicular fractures or surgery in the neck area.

REFERENCES

- Anastasopoulos N, Paraskevas G, Apostolidis S, Natsis K (2015) Three superficial veins coursing over the clavicles: a case report. *Surg Radiol Anat*, 37: 1129–1131. doi: 10.1007/s00276-015-1445-4.
- Bergman RA, Afifi AK, Miyauchi R. *Illustrated Encyclopedia of Human Anatomic Variation: Opus II: Cardiovascular System: Veins: Head, Neck, and Thorax*. <http://www.anatomyatlases.org/AnatomicVariants/Cardiovascular/Text/Veins/JugularExternal.shtml> (accessed May 2015).
- Brain P (1986) *Galen on bloodletting: a study of the origins, development, and validity of*. Cambridge University Press, Cambridge, pp. 140–141.
- Brook WH, Smith CJD (1989) Clinical presentation of a persistent jugulocephalic vein. *Clin Anat*, 2: 167–173.
- De Maria E, Cappelli S (2013) Cephalic vein with a supraclavicular course: rare, but do not forget it exists! *J Cardiovasc Med*, doi: 10.2459/JCM.0b013e32836132d6.
- Kim DI, Han SH (2010) Venous variations in neck region: cephalic vein. *Int J Anat Var*, 3: 208–210.
- Lau EW, Liew R, Harris S (2007) An unusual case of the cephalic vein with a supraclavicular course. *Pacing Clin Electrophysiol*, 30: 719–720.
- Loukas M, Myers CS, Wartmann ChT, Tubbs RS, Judge T, Curry B, Jordan R (2008) The clinical anatomy of the cephalic vein in the deltopectoral triangle. *Folia Morphol*, 67: 72–77.
- Nayak SB, Kv S (2008) Abnormal formation and communication of external jugular vein. *Int J Anat Var*, 1: 15–16.
- Patil RA, Rajgopal L, Lyer P (2013) Absent external jugular vein-Ontogeny and clinical implications. *Int J Anat Var*, 6: 103–105.
- Ramírez JD, Sáenz LC, Rodríguez D, Restrepo AJ, Villegas F (2014) Supraclavicular course of the cephalic vein. *IJCRI*, 5: 281–284.
- Standring S ed. (2008) *Gray's anatomy: the anatomical basis of clinical practice*. 40th ed. Churchill Livingstone, Edinburgh, London, p. 828.
- Thiranagama R, Chamberlain AT, Wood BA (1989) The comparative anatomy of the forelimb veins of primates. *J Anat*, 164: 131–144.
- Thiranagama R, Chamberlain AT, Wood BA (1991) Character phylogeny of the primate forelimb superficial venous system. *Folia Primatol*, 57: 181–190.
- Thyng FW (1914) Anatomy of a 17.8 mm human embryo. *Am J Anat*, 17: 32–113.