

Ring-shaped variation of the coeliac trunk branches

A. Raikos, N. Pynadath, N. Anguswamy, S. Vallath, P. Kordali, A. Stirling

Faculty of Health Sciences and Medicine, Bond University, Queensland, Australia

[Received 3 March 2015; Accepted 3 April 2015]

Aberrant arterial variations in the branching pattern of the coeliac trunk are of great interest to surgeons and radiologists. We report on a rare arterial variation found in a 79-year-old cadaver during educational dissection. Specifically, the coeliac axis formed a unique incomplete trunk termed the hepato-hepatic trunk. The splenic artery arose separately from the anterior aspect of the abdominal aorta. On the right side, there was a right hepatic artery giving rise to a gastroduodenal but an absence of the left hepatic. On the left side, there was a branch coursing towards the porta hepatis; the left hepatic artery, dividing into the left gastric, an accessory left gastric, and a branch to the distal oesophagus. The hepato-hepatic trunk formed a ring-shaped vascular structure around the caudate lobe of the liver. Precise mapping and observation of the extrahepatic arteries and bile duct branches is essential in a variety of hepato-biliary laparoscopic procedures of the liver and gallbladder. Other operative procedures requiring, a comprehensive knowledge of the varied coeliac trunk patterns are liver transplantation and arterial embolism for hepatic tumour therapy. (Folia Morphol 2015; 74, 4: 540–543)

Key words: coeliac artery, coeliac axis, hepatic artery, hepato-hepatic trunk, incomplete coeliac trunk, left hepatic artery, splenic artery

INTRODUCTION

The coeliac trunk has been widely recognised as an important vessel within the upper abdomen, its branches supplying multiple structures derived from the embryological foregut such as the stomach, spleen, distal oesophagus, duodenum, liver, gallbladder, pancreas, and greater and lesser omentums. The first description of the topography and branches of the coeliac trunk was from Albrecht von Haller [2] who compared the branching shape with that of a tripod. Initially, the coeliac trunk arises from the abdominal aorta at the L1 vertebral level and immediately trifurcates into splenic, left gastric, and common hepatic arteries. The splenic artery courses along the superior aspect of the pancreas, giving off branches to the pancreas, the left gastro-omental artery, short gastric arteries and a posterior gastric artery before eventually terminating at the spleen.

The left gastric artery runs along the superior part of the lesser curvature of the stomach. The common hepatic artery travels towards the liver, giving off the gastroduodenal and right gastric artery before becoming the proper hepatic artery. It then divides into the right and left hepatic arteries supplying the liver. There are various other branches that come off each these arteries supplying the different structures in the upper abdomen [12].

The coeliac trunk and its branches exhibit a broad range of variation in location, number, and course. Due to the high clinical significance of these branches many studies have documented the arterial variations of the major unpaired arteries that originate from the aorta. Some studies offer classifications with the types and frequency of these variations, in an effort to illustrate the extensive variety [1, 3, 5–8, 14]. In a review of the literature, on 2141 cadavers, 87.6% of coeliac

Address for correspondence: Dr A. Raikos, Assistant Professor of Anatomy, Anatomical Sciences, Faculty of Health Sciences and Medicine, Bond University, Varsity Lakes, QLD 4229, Australia, e-mail: a.raikos@yahoo.com

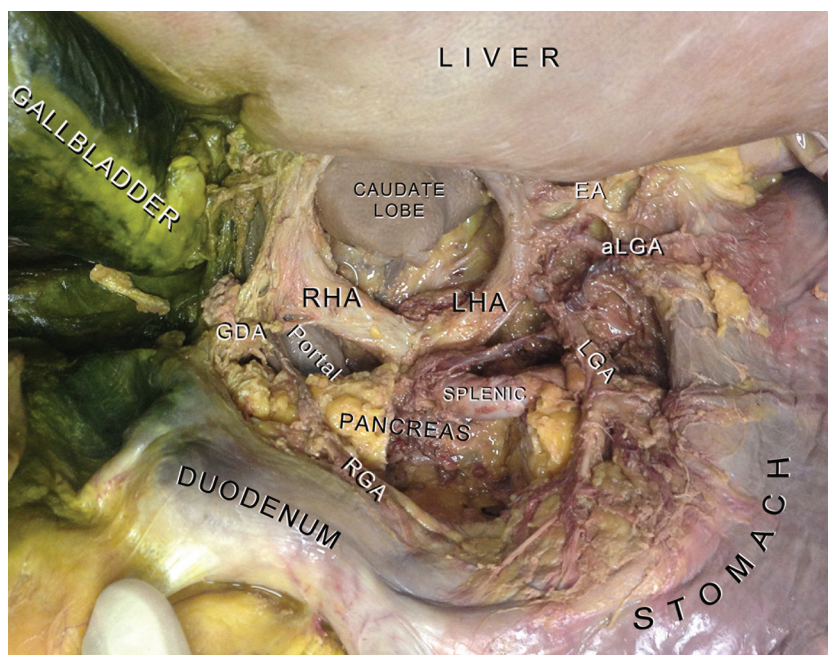


Figure 1. Incomplete hepato-hepatic trunk. The left hepatic artery (LHA) arose from the left side of the trunk and gave off the left gastric artery (LGA), an accessory left gastric artery (aLGA) supplying the cardiac region of the stomach, and an oesophageal branch (EA) for the distal oesophagus. There is an absence of common and proper hepatic artery. The liver is reflected for a better view. Part of the body of the pancreas has been resected for exposing the splenic artery; RHA — right hepatic artery; GDA — gastroduodenal artery; RGA — right gastric artery; Portal — portal vein.

trunks had the classical trifurcation, 12.2% presented an incomplete bifurcated coeliac trunk and in 0.2% was absent [14]. In a second study of 604 selective coeliac angiographies, 79.1% of patients exhibited a typical coeliac trunk anatomy [5]. In yet another study of 974 cadavers, only 10.2% of specimens had a variation in the branching pattern. There was no significant difference in frequency between males and females [1]. In an extensive review of 12196 cases, the 89.4% had the typical complete trifurcation of the coeliac trunk while 10.6% exhibited variations. It seems there is a prevalence of Korean and Japanese populations presenting coeliac trunk variations more frequently than Caucasians [8]. In rare cases, the coeliac branches may arise independently from the anterior wall of the abdominal aorta [4, 6, 14]. Knowledge of such variations has important clinical significance especially in regards to certain abdominal, invasive arterial, and radiological procedures.

The aim of this study is to describe a rare finding of an incomplete coeliac trunk forming a ring-shaped arterial formation around the caudate lobe of the liver. We comment on the clinical significance of the variation, review the relevant literature, and provide a new insight on the existing record of the coeliac trunk classifications.

CASE REPORT

A variation of the coeliac trunk branches was noticed during the routine dissection for educational purposes of a 79-year-old male, formalin-fixed, cadaver. The most interesting aspect of this finding was the ring-shaped arrangement of the coeliac trunk branches around the caudate lobe of the liver (Fig. 1). Specifically, an incomplete coeliac trunk with 2 branches was found. The splenic artery arose separately from the coeliac trunk. The first branch of the incomplete trunk, on the right side, demonstrated a similar course to that of a right hepatic artery. After giving off the gastroduodenal artery, the main branch did not however divide any further and entered the porta hepatis. The common and proper hepatic artery was missing due to the absence of bifurcation to right and left hepatic arteries. This terminal branch could be named as right hepatic artery owing to its distribution. The second branch of the incomplete trunk arose from the left side of the coeliac axis and had similar diameter to the branch on the right. Its course was also towards the porta hepatis of the liver and could be termed as a left hepatic artery. During its course it gave off the left gastric artery, an accessory left gastric artery (supplying the cardiac region of the stomach), and an oesophageal branch (Fig. 2). The

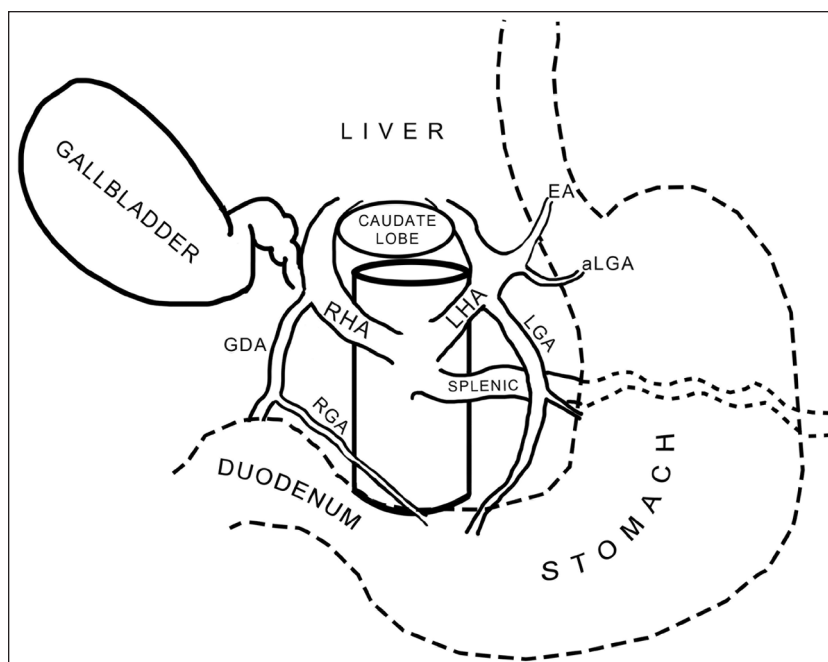


Figure 2. Schematic representation of Figure 1; abbreviations as in Figure 1.

caudate lobe of the liver was encircled by the 2 thick main vessels of the incomplete coeliac trunk.

In an effort to classify the exact pattern of the arterial variation the literature was reviewed. To the best of our knowledge, no available classifications existed that matched this particular arterial pattern. The incomplete coeliac trunk could be called a gastro-hepatic trunk (type-II according to Michels) since the splenic artery arise separately [7]. However, the course and diameter of the branch on the left side did not conform to this categorisation. The most appropriate term for the variation is an incomplete coeliac trunk forming a hepato-hepatic trunk.

DISCUSSION

The abdominal aorta and its branches are commonly found to be variable in their pattern and distribution, and there have been extensive studies on these anomalies. The branches may vary in position, be replaced by other vessels, exhibit an aberrant course, be accompanied by accessory branches, or have absence of branches [3–9, 11, 14]. There are a multitude of classifications within the literature describing the variations of the coeliac trunk, with an impressive number of studied material ranging from autopsies, cadavers, radioimaging, angiographies, and surgical observations.

We tried to classify the variations in the present case, according to the available classifications in the literature without success. Specifically we focused on the hepatic artery variations relating to the presence of a hepato-hepatic trunk in our cadaveric observation. Michels [7] was the first who suggested an extensive classification proposal of 10 different types of hepatic artery variations modified by Hiatt et al. [3] 28 years later. In a review on 1081 liver transplantations, 30% of the livers exhibited variations in the arterial supply, and 12 different patterns/types were described [6]. In 9.7% of cases, the left hepatic artery was replaced by the gastric artery (type II). In these cases, the left gastric is the main branch giving off a secondary terminal branch to the liver. At first glance, someone could classify our described variation on the left side of the coeliac axis as a replaced left gastric artery. This is however not accurate because a main branch coursing in acute angle towards the liver can clearly be observed with secondary, smaller diameter, branches such as the left gastric and oesophageal artery arising along its distribution. Moreover, the branch on the left had similar diameter as the common hepatic artery on the right side of the axis. The 2 vessels together form a hepato-hepatic trunk and surround the caudate lobe of the liver. Lopez-Andujar et al. [6], highlight the concept that aberrant hepa-

tic vessels should be classified either as “accessory” or “replaced” because hepatic arteries are terminal vessels. We disagree with this description as the diameter and course of a vessel should also be taken into consideration. The present case is an example of such a variation which may not have been highlighted by other studies as it is difficult to estimate the diameter of the vessel particularly in those studies based on angiographic data.

Chen et al. [1] classified the possible common arterial trunk formations after studying 974 cadavers. The six types of trunks reported are hepatosplenic (4.4%), hepatosplenomesenteric (0.7%), gastrohepatic (0.3%), coeliacomesenteric (0.7%), hepatomesenteric (3.4%), and gastrosplenic (0.5%) [1]. None of the described types included the hepato-hepatic trunk found in the present case. In a review including 9829 cases, a hepatosplenic trunk was found in 3.3%, a splenogastric and hepatomesenteric trunk was found in 1.9%, and a splenogastric trunk in 1.1% of studied subjects [8]. Additional trunks with very low incidence were presented but we could not match any of them with the presented hepato-hepatic trunk. The authors of the review comment that none of the already existing coeliac trunk classification contains all the reported variations in the literature.

It is important for clinicians intervening in the upper abdomen to be aware of the wide range of possible arterial anatomical variations of cardinal vessels so as to avoid clinical misadventure. Any erroneous interpretation of blood vessels may lead to unwarranted bleeding or organ ischaemia, both of which may have medico-legal implications. Extrahepatic arterial variations are of utmost importance and should be precisely mapped to ensure complete arterialisation of the graft in liver transplantation [3]. Common procedures that involve the left gastric and left hepatic artery include Appleby’s procedure, which involves resection of pancreatic tumours and possible reconstruction of the hepatic artery [13]. Other procedures include liver transplantation, laparoscopic surgery, and vascular procedures for abdominal aortic aneurysms [14]. Hence, it is important for doctors to identify and precisely map any variations when interpreting

radiological imaging [9, 10]. Aberrant hepatic artery anatomy should be taken into consideration during surgical planning, employing appropriate diagnostic and intraoperative strategies.

REFERENCES

1. Chen H, Yano R, Emura S, Shoumura S (2009) Anatomic variation of the celiac trunk with special reference to hepatic artery patterns. *Ann Anat*, 191: 399–407.
2. Haller A (1756) *Icones anatomicae in quibus aliquae partes corporis humani delineatae proponuntur et arteriarum potissimum historia continetur*. Vandenhoeck, Göttingen.
3. Hiatt JR, Gabbay J, Busstitt RW (1994) Surgical anatomy of the hepatic arteries in 1000 cases. *Ann Surg*, 220: 50–52.
4. Iacob N, Sas I, Joseph SC, Ples H, Miclaus GD, Matusz P, Tubbs RS, Loukas M. (2014) Anomalous pattern of origin of the left gastric, splenic, and common hepatic arteries arising independently from the abdominal aorta. *Rom J Morphol Embryol*, 55: 1449–1453.
5. Koops A, Wojciechowski B, Broering DC, Adam G, Krupski-Berdien G (2004) Anatomic variations of the hepatic arteries in 604 selective celiac and superior mesenteric angiographies. *Surg Radiol Anat*, 26: 239–244.
6. Lopez-Andujar R, Moya A, Montalva E, Berenguer M, De Juan M, San Juan F, Pareja E, Vila JJ, Orbis F, Prieto M, Mir J (2007) Lessons learned from anatomic variants of the hepatic artery in 1,081 transplanted livers. *Liver Transpl*, 13: 1401–1404.
7. Michels NA (1966) Newer anatomy of the liver and its variant blood supply and collateral circulation. *Am J Surg*, 112: 337–347.
8. Panagouli E, Venieratos D, Lolis E, Skandalakis P (2013) Variations in the anatomy of the celiac trunk: Aa systematic review and clinical implications. *Ann Anat*, 195: 501–511.
9. Raikos A, Paraskevas GK, Natsis K, Tzikas A, Njau SN (2010) Multiple variations in the branching pattern of the abdominal aorta. *Rom J Morphol Embryol*, 51: 585–587.
10. Rusu MC, Jianu AM, Sztika D, Cuzino D, Loreto C (2011) Three extremely rare anatomic variants of the hepatic artery. *Ann Vasc Surg*, 25: 1138.e1–1138.e7.
11. Schwarz L, Huet E, Yzet T, Fuks D, Regimbeau JM, Scotte M (2014) An extremely uncommon variant of left hepatic artery arising from the superior mesenteric artery. *Surg Radiol Anat*, 36: 91–94.
12. Standring S (2005) *Gray’s anatomy*. 39th Ed. Churchill Livingstone, Edinburgh.
13. Takenaka H, Iwase K, Ohshima S, Hiranaka T (1992) A new technique for the resection of gastric cancer: modified appleby procedure with reconstruction of hepatic artery. *World J Surg*, 16: 947–951.
14. Yi SQ, Terayama H, Naito M, Hirai S, Alimujang S, Yi N, Tanaka S, Itoh M (2008) Absence of the celiac trunk: case report and review of the literature. *Clin Anat*, 21: 283–286.