

# Chiari type I malformation with high foramen magnum anomaly

H. Ulutabanca<sup>1</sup>, N. Acer<sup>2</sup>, A. Küçük<sup>1</sup>, S. Doğan<sup>3</sup>, A. Tümtürk<sup>1</sup>, A. Kurtsoy<sup>1</sup>, A. Sağıroğlu<sup>2</sup>, M. Bilgen<sup>4</sup>

<sup>1</sup>Department of Neurosurgery, Medical Faculty, Erciyes University, Kayseri, Turkey

<sup>2</sup>Department of Anatomy, Medical Faculty, Erciyes University, Kayseri, Turkey

<sup>3</sup>Department of Radiology, Medical Faculty, Erciyes University, Kayseri, Turkey

<sup>4</sup>Department of Biophysics, Medical Faculty, Adnan Menderes University, Aydin, Turkey

[Received 21 September 2014; Accepted 3 November 2014]

*A 14-year-old male with a neck pain and hypoesthesia in the upper extremities was diagnosed with Chiari type I malformation (CMI) and syringomyelia. The posterior part of the occipital bone was removed via cranio-cervical decompression. The accuracy of measuring the posterior cranial fossa (PCF) and foramen magnum (FM) dimensions were evaluated and compared with the literature. The linear PCF and FM dimensions as well as volumes were measured using computed tomography (CT) images with different techniques.*

*The volume data were compared with similar data from literature. Use of the posterior fossa approach remains controversial when treating patients with minor little brain stem dislocation, small PCF, and or incomplete C1, but the approach can easily be applied if FM and PCF sizes are known. Linear measurements that were assessed for concordance with CT measurements had the best agreement. Quantification of PCF volume and high FM should be taken into consideration for differential diagnosis of tonsillar herniation and prediction of surgical outcome in CMI. (Folia Morphol 2015; 74, 3: 402–406)*

**Key words: foramen magnum, posterior cranial fossa, computed tomography, Chiari malformation**

## INTRODUCTION

Posterior cranial fossa (PCF) abnormality of the skull is a developmental disorder and its variations have widely been reported in the literature [2, 4, 9]. Chiari malformations, Dandy Walker malformations, spina bifida and craniovertebral junction disorders are the common forms of the structural abnormality [1, 7]. Knowledge of the morphological variations makes it possible to conduct optimal preoperative surgical planning, minimise retraction and reduce morbidity during PCF exposure surgery. In this paper, we report an unknown case of Chiari malformation of type 1 (CM1). Specifically, we present an elevated foramen magnum (FM) and altered

shape and dimension of its border, as unique anatomical characteristics of this case. We provide a z-print model of the skull based on data obtained from computed tomography (CT) scan for 3 dimensional (3D) visualisation and evaluation in real time and explicitly give the dimensions and volumes of PCF and FM.

## MATERIALS AND METHODS

Measurements were conducted in a way similar to the anatomic bone assessment with axial, sagittal and coronal scans (Toshiba scanner; Aquillion 256 detectors, with technical parameters including 1.25 mm thick slices, FOV: 290 mm, matrix: 512 × 512,

Address for correspondence: Doç. Dr N. Acer, Erciyes Üniversitesi Tıp Fakültesi, Anatomi Anabilim Dalı, TR-38000 Kayseri, Turkey, tel: +90 352 4374901, fax: +90 352 4375285, e-mail: [acerniyazi@yahoo.com](mailto:acerniyazi@yahoo.com)

pixel size: 0.58 mm, 200 mA, 120 kV). Scanning data were transferred to a work station with 3D visualisation software (Osirix) using 3D volume rendering technique. We calculated intracranial volume (ICV) and PCF volume.

After the establishment of the symmetrical raw data, images were reformatted in the workstation. The measurement points were defined on the 3D reformatted image and their correspondent arrows were confirmed on the axial, sagittal and coronal planes. The best position to get the most accurate measurement was ensured by rotating the 3D reformatted image and checking the correspondent axial, sagittal and coronal views.

FM measurements (sagittal, transverse, circumference and area) were obtained from reformatted axial sections. The FM sagittal diameter (FMSD) was recorded as the greatest anteroposterior dimension of the FM and the FM transverse diameter (FMTD) was recorded as the greatest width of the FM. The FM circumference (FMC) and the FM area (FMA) were automatically given after tracing the bony margin of the FM (Fig. 1). Using a reconstructed CT 3D image, we measured clival length (from the basion to the top of the dorsum sellae), the supraocciput (from the internal occipital protuberance to the opisthion) [5].

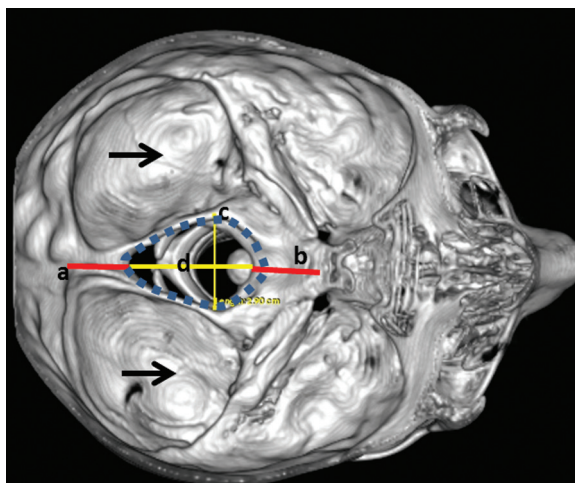
#### Linear measurements of the PCF

The lengths of 3 midsagittal PCF structures were measured on the midsagittal CT image by a trained expert with 5 years of experience (H.U.). These structures were characterised as follows:

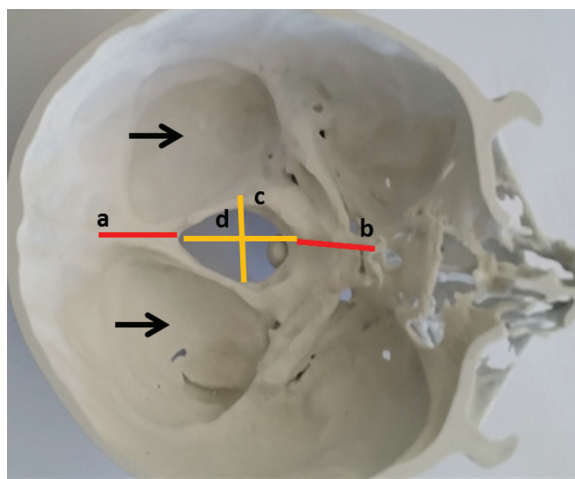
1. McRae line measured from the basion and the opisthion.
2. Height, width and length of the PCF.
3. Tonsillar herniation measured from the McRae line to tip of the cerebellar tonsil [2, 11]. The diagnosis of CMI was based on the determination of a cerebellar tonsillar herniation of at least 5 mm below the FM [3].

The skull of our case was printed using 3D printer (Z printer 450) (Fig. 2). Both radiological and calliper measurements (3D-CT) of the FM dimensions, supraocciput and clival length were also conducted on our case. Three parameters were analysed on printed skull. The measured parameters were: the length of clivus, the supraocciput, and the anteroposterior and transvers diameter of the FM (Fig. 2).

Anatomic measurements were performed by an anatomist (N.A.) using a Vernier calliper accurate to



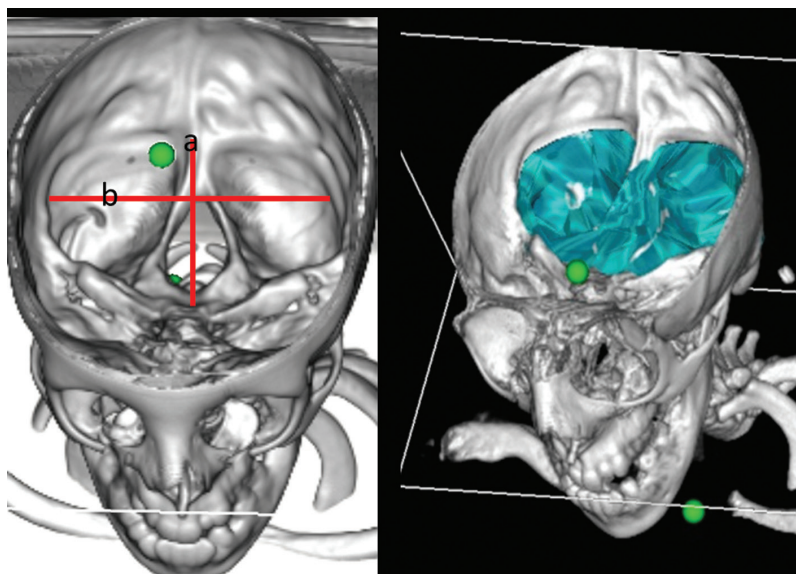
**Figure 1.** Reconstructed skull. Measurement of diameters of foramen magnum (FM) measurements; a — supraocciput; b — clival length; c — transverse length of FM.



**Figure 2.** Z printed skull; a — supraocciput; b — clival length; c — transverse length of foramen magnum (FM); d — anteroposterior length of FM.

0.1 mm, whereas the CT measurements were performed by a neurosurgeon (H.U.) on bone window CT. The depth, height, and width of the PCF were measured using 3D-CT scans evaluating morphological variations between the two sides.

The PCF was defined as the osseous anatomical area with a floor formed by the occipital bone and the basisphenoid [11]. The extent of cerebellar herniation was measured from the tips of the cerebellar tonsils to a line drawn between the basion and opisthion [11]. We used Osirix program for ICV and PCF volume calculation. The Osirix program automatically added



**Figure 3.** Reconstruction image of computer tomography of the abnormal skull. Antero-posterior (a) and transverse diameter (b) of posterior cranial fossa measurement and volume.

the area of each slice and then PCF volume was determined (Fig. 3). Calculated volume was obtained as the sum of the areas of the structure transects on consecutive systematic sections multiplied by the distance between sections. This program allows the user to determine contrast, select true threshold value to estimate counting automatically.

### CASE REPORT

An adolescent male (14 years old) complaining of neck pain and numbness in upper extremities was presented to the clinics. The patient was neurologically evaluated and ordered for radiological head and neck examination. CT scan revealed normal cerebral structures and no calcification, but craniovertebral malformation. The diagnosis was CMI which manifested as syringomyelia. Our case has got more bony anomalies: C1 spina bifida, PCF anomalies and CM1.

The bony abnormality had special anatomical features that have not been observed by our radiology team nor reported previously in the literature. To further explore the nature of the distinguished malformation, we displayed and closely examined the skull using 3D volume rendering after stripping off the skull bones in CT images with intensity thresholding. The structural abnormalities of PCF and FM were depicted by the arrows in Figure 1. The dimension and volumes were measured using manual segmentation on the volumetric CT data. In the figure, FM is

seen as significant elevated and distorted as such its borders shaped more like ellipse with greater aspect ratio compared to a normal.

For real life visualisation, we next printed a physical model of the abnormal skull using 3D printer (Z printer 450, Z Corporation, Burlington, USA). The resulting model was shown in which antero-posterior and transverse diameter of PCF measurement and volume were seen in Figure 3.

Total ICV and PCF volumes were  $1609.15 \text{ cm}^3$  and  $100.91 \text{ cm}^3$ , respectively. The length of tonsil herniation was 1.69 cm. The length of clivus, supraocciput and antero-posterior length and transverse length of FM were found as 3.43 cm, 2.92 cm, 4.02 cm, 2.90 cm using reconstructed 3D-CT image. The FMC and FMA were 12.18 cm,  $9.65 \text{ cm}^2$ , respectively. The width and length of PCF were 8.22 cm and 11.41 cm, respectively.

The clival length, supraocciput, antero-posterior and transverse lengths of FM were found as 3.45 cm, 2.59 cm, 4.09 cm, 2.80 cm using printed skull. The elevation of FM was measured as 2.0 cm (Table 1).

### DISCUSSION

Because the base of the cranium is so complex studying the shape of the FM, due to the important relation of the FM with its contents, is very interesting, from a descriptive and topographic point of view. The FM is a large foramen which is present in the base of the skull and considered as an important landmark.

**Table 1.** Foramen magnum (FM) measured anatomical and radiological parameters on our case

	Radiologic (CT)	Printed skull
Clival length [cm]	3.43	3.45
Supraocciput [cm]	2.92	2.59
Anteroposterior length [cm]	4.02	4.09
Transverse length [cm]	2.90	2.80
Elevation of FM [cm]	–	2.0
Circumference of FM [cm]	12.18	–
Area of FM [cm <sup>2</sup> ]	9.65	–

CT — computed tomography

Since the FM includes specific neuroanatomical structures and lesions in that region particularly require microsurgical intervention, choosing and establishing the most suitable surgical techniques need a careful planning mainly based on the FM size to prevent any neurological injury [6]. Moreover, intradural and extradural tumours, such as common congenital abnormalities as FM syndrome produced by atlanto-occipital assimilation, and cerebellar tissue herniations invaginating into the FM may lead to neural compression and even death is a commonly met pathological disorder in this region.

The FM is usually described as oval in shape in the literature. In a study of 200 skulls, Zaidi and Dayal [12] reported that oval FMs were found in 128 (64%) skulls. The FM was hexagonal in 24.5%, pentagonal in 7.5%, irregular in 3.5% and round in 0.5% of the skulls [12]. In our case, FM shape was ellipsoidal.

Sexual dimorphism determined by analysing the dimensions of the FM, which was about 3 cm wide by 3.5 cm antero-posteriorly, as reported by Uysal et al. [10]. Aydın et al. [1], who examined a retrospective cohort of 60 adult patients with CMIs, and made multiple measurements on magnetic resonance imaging, found that reduced mean length of clivus, reduced mean length of PCF, reduced height of supraocciput, increased anteroposterior length of FM in CMI reached statistically significant difference compared to controls.

In clinical and experimental studies, the cerebellar tonsillar herniation occurring in CMI is reported to mainly result from overcrowding of a normally developing hindbrain within a primary small and shallow PCF due to an anomaly in the embryological development of the occipital bone [1, 3, 4, 7, 9].

There is a wide variation in the PCF volumes reported in literature. Bağcı et al. [2] used 9 CMI patients for an atlas-based automated PCF parcellation approach as manually delineated PCF. PCF volumes measured by use of the automated method and with manual delineation were found to be similar,  $196.2 \pm 8.7$  vs.  $196.9 \pm 11.0$  cm<sup>3</sup>, respectively. The mean PCF volumes previously reported in CT and magnetic resonance-based measurements of 186 cm<sup>3</sup> by Nishikawa et al. [7],  $174 \pm 25$  cm<sup>3</sup> by Noudel et al. [8] and  $166 \pm 8$  cm<sup>3</sup> by Milhorat et al. [5] and  $165.57 \pm 19.37$  cm<sup>3</sup> by Vurdem et al. [11]. As for our finding, PCF volume was 100.91 cm<sup>3</sup>.

Vurdem et al. [11] found that the mean  $\pm$  standard deviation PCF volume, cerebellar volume, herniated tonsillar volume, herniated tonsillar length, cerebellar volume to PCF volume ratio, and herniated tonsillar volume to cerebellar volume ratio were  $146.01 \pm 19.07$  cm<sup>3</sup>,  $117.49 \pm 18.28$  cm<sup>3</sup>,  $0.89 \pm 0.50$  cm<sup>3</sup>,  $9.63 \pm 3.37$  mm,  $80.39 \pm 6.68\%$ , and  $0.77 \pm 0.38\%$  in the CMI group, respectively.

Furtado et al. [4] found that the PCF volume in childhood patients with CMI was significantly lower than that in the control group ( $p = 0.002$ ). They found that the mean PCF volume was 204.1 cm<sup>3</sup> in patients with CMI and 252.8 cm<sup>3</sup> in the age and sex matched control group. Also, they found that the PCF volume in adult patients with CMI was 245.4 cm<sup>3</sup>. All studies noted a smaller PCF volume in the CMI patients. Our case PCF volume is smaller than other studies. Also, FM linear dimensions were larger than those in other studies. High FM and deep PCF have not previously been described in the literature.

In morphometric studies about PCF volume, significantly smaller volume or underdevelopment bony part of the PCF has been shown clearly [1]. Trigylidas et al. [9] found that mean PCF volumes was smaller in paediatric CMI patients than in control patients.

Dagtekin et al. [3] examined 15 adult patients with CMI. Multiple measurements were made on magnetic resonance images. The results were compared with the findings in 25 controls and 30 dry skulls. What was found is that the mean length of the supraocciput was significantly shorter and the average diameter of the FM was significantly longer in the CMI group when compared to the control group and dry skulls. Dagtekin et al. [3] found that the average amount of tonsillar herniation was 7.4 mm (range 4.9–12.1 mm) in CMI patients. Our case had 1.69 cm tonsillar herniation length.

In order to determine such malformations as Arnold Chiari syndrome, which shows expansion of transverse diameter, the knowledge of FM diameters is needed [9].

Our study has some advantages and some limitations. One of the advantages is the establishment of the real dimensions through radiological evaluation compared to the morphometric measurement. Therefore, dry skulls were evaluated through direct anatomic, morphometric measurement by the electronic calliper and CT with the comparison of each other. One case and no control is a major limitation. Recently, morphometric studies have clearly shown significantly smaller volume or underdeveloped bony parts of the PCF in adults [1–3, 5]. A significant smaller basiocciput in CMI group was demonstrated by Noudel et al. [8], but no significant difference was found in the length of the supraocciput and FM. No significant difference in the length of the clivus, basiocciput and spheniocciput between the CMI and the control group was reported by Nishikawa et al. [7].

However, they showed a significantly smaller supraocciput in CMI group. Aydin et al. [1] reported a significantly smaller length of clivus and supraocciput in CMI group. They demonstrated significantly longer FM in CMI group. Our study has demonstrated that the lengths of the basiocciput and supraocciput were shorter than in other studies. The elevation of FM was measured as 2.0 cm and the area of FM opening was 9.65 cm<sup>2</sup> as compared to 7.50 cm<sup>2</sup> of normal FM.

Our study suggests that the PCF in our case is smaller than the one seen in the general population due to significant shortness of the basiocciput and supraocciput. But anteroposterior length and length of tonsillar herniation are higher than those in other studies.

What we can conclude is that a rapid and reliable diameter measurement technique tool is considered as useful for morphological differences of FM in view of the software requirement for 3D volume measurement. These devices and methods can be applied for surgical processes. Since measuring PCF volume and dimensions of FM becomes important in assessing the response to decompressive surgery or monitoring growth in patients with Chiari, other craniovertebral

anomalies should be taken into consideration. We are of the opinion that the small PCF and high FM with Chiari-related cases would be useful if the operations are to be conducted in these cases.

## REFERENCES

1. Aydin S, Hanimoglu H, Tanriverdi T, Yentur E, Kaynar MY (2005) Chiari type I malformations in adults: a morphometric analysis of the posterior cranial fossa. *Surg Neurol*, 64: 237–241.
2. Bagci AM, Lee SH, Nagornaya N, Green BA, Alperin N (2013) Automated posterior cranial fossa volumetry by MRI: applications to Chiari malformation type I. *Am J Neuroradiol*, 34: 1758–1763.
3. Dagtekin A, Avci E, Kara E, Uzmsansel D, Dagtekin O, Koseoglu A, Talas D, Bagdatoglu C (2011) Posterior cranial fossa morphometry in symptomatic adult Chiari I malformation patients: comparative clinical and anatomical study. *Clin Neurol Neurosurg*, 113: 399–403.
4. Furtado SV, Reddy K, Hegde AS (2009) Posterior fossa morphometry in symptomatic pediatric and adult Chiari I malformation. *J Clin Neurosci*, 16: 1449–1454.
5. Milhorat TH, Nishikawa M, Kula RW, Dlugacz YD (2010) Mechanisms of cerebellar tonsil herniation in patients with Chiari malformations as guide to clinical management. *Acta Neurochir (Wien)*, 152: 1117–1127.
6. Muthukumar N, Swaminathan R, Venkatesh G, Bhanumathy SP (2005) A morphometric analysis of the foramen magnum region as it relates to the transcondylar approach. *Acta Neurochir (Wien)*, 147: 889–895.
7. Nishikawa M, Sakamoto H, Hakuba A, Nakanishi N, Inoue Y (1997) Pathogenesis of Chiari malformation: a morphometric study of the posterior cranial fossa. *J Neurosurg*, 86: 40–47.
8. Noudel R, Jovenin N, Eap C, Scherpereel B, Pierot L, Rousseaux P (2009) Incidence of basioccipital hypoplasia in Chiari malformation type I: comparative morphometric study of the posterior cranial fossa. *Clinical article. J Neurosurg*, 111: 1046–1052.
9. Trigylidas T, Baronia B, Vassilyadi M, Ventureyra EC (2008) Posterior fossa dimension and volume estimates in pediatric patients with Chiari I malformations. *Childs Nerv Syst*, 24: 329–236.
10. Uysal S, Gokharman D, Kacar M, Tuncbilek I, Kosa U (2005) Estimation of sex by 3D CT measurements of the foramen magnum. *J Forensic Sci*, 50: 1310–1314.
11. Vurdem UE, Acer N, Ertekin T, Savranlar A, Inci MF (2012) Analysis of the volumes of the posterior cranial fossa, cerebellum, and herniated tonsils using the stereological methods in patients with Chiari type I malformation. *ScientificWorld J*, 2012: 616934.
12. Zaidi SH, Dayal SS (1988) Variations in the shape of foramen magnum in Indian skulls. *Anat Anz*, 167: 338–340.