

# A combined anatomical variation of inferior epigastric vessels\*

B. Ercakmak<sup>1</sup>, A. Firat<sup>1</sup>, C. Gunenc Beser<sup>1</sup>, S. Bilgin<sup>2</sup>, M.F. Sargon<sup>1</sup>, R. Basar<sup>1</sup>

<sup>1</sup>Department of Anatomy, Faculty of Medicine, Hacettepe University, Ankara, Turkey

<sup>2</sup>Faculty of Medicine, Kafkas University, Kars, Turkey

[Received 2 July 2012; Accepted 7 September 2012]

*During the routine gross anatomical dissection of the right inguinal region of a 45-year-old male cadaver, a variation was observed both in the inferior epigastric artery and the inferior epigastric vein. In this case, the right inferior epigastric artery originated from the femoral artery 13 mm inferior to the inguinal ligament. Additionally, in this cadaver, the single right inferior epigastric vein drained into femoral vein 8 mm inferior to the inguinal ligament. The distal origin of the inferior epigastric artery from the femoral artery and the lower drainage of the single inferior epigastric vein to the femoral vein must be taken into consideration by surgeons. (Folia Morphol 2012; 71, 4: 267–268)*

**Key words:** human cadaver, inferior epigastric artery, inferior epigastric vein, inguinal hernia, variation

## INTRODUCTION

The inferior epigastric artery originates from the external iliac, posterior to the inguinal ligament. Its accompanying veins, usually two in number, drain into the external iliac vein. The artery has an important infero-medial relation with the deep inguinal ring and may be damaged during extensive medial dissection of the deep ring during hernia repair [1, 2].

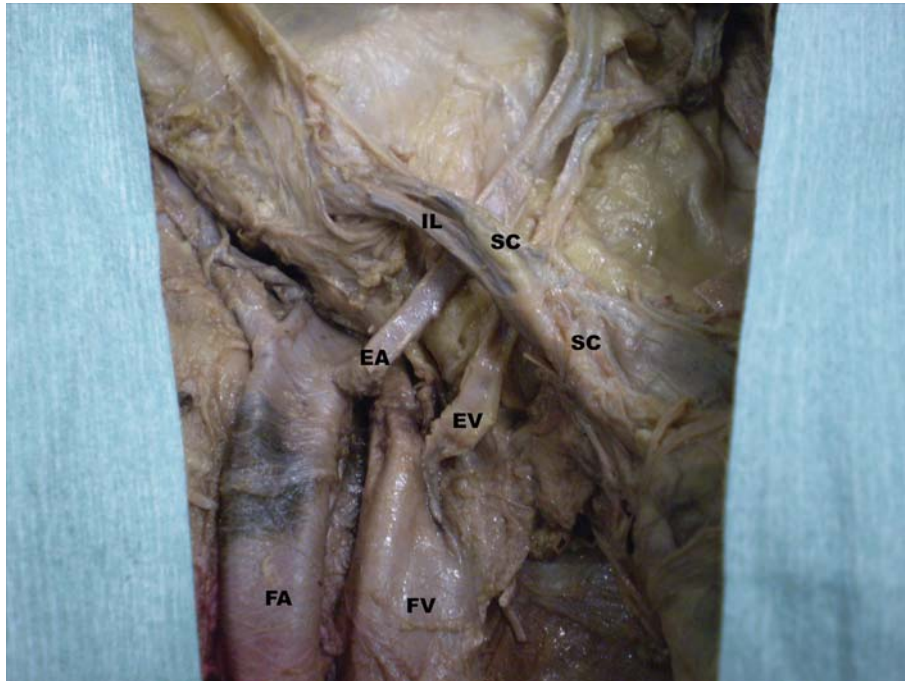
Although the anatomical variations of inferior epigastric vessels are well documented [2–5], in this case we report a combined anatomical variation of inferior epigastric artery and its accompanying single inferior epigastric vein, which may have great clinical importance for surgeons during inguinal hernia repair.

## CASE REPORT

During the routine gross anatomical dissection of the right inguinal region of a 45-year-old male cadaver, a variation was observed both in the inferior epigastric artery and in the inferior epigastric vein. In this case, the right inferior epigastric artery originated from the femoral artery 13 mm inferior to the inguinal ligament. Then, this artery coursed on the lateral side of the variant inferior epigastric vein. The diameter of this variant artery was 3 mm at its origin. Additionally, in this cadaver, the single right inferior epigastric vein drained into the femoral vein 8 mm inferior to the inguinal ligament. The diameter of the variant vein was 4 mm at its draining point. Both the variant artery and vein passed posterior to the spermatic cord, and their

Address for correspondence: B. Ercakmak, MD, Department of Anatomy, Faculty of Medicine, Hacettepe University, Ankara 06100, Turkey, e-mail: burcue@hacettepe.edu.tr

\*This study was presented as an oral presentation in the 9<sup>th</sup> EACA Congress, 5–8 September 2007, Prague, Czech Republic.



**Figure 1.** The variant inferior epigastric vessels; IL — inguinal ligament; SC — spermatic cord; EA — inferior epigastric artery; EV — inferior epigastric vein; FA — femoral artery; FV — femoral vein.

courses in the rectus sheath were normal in every aspect (Fig. 1).

The left inguinal region and inferior epigastric vessels of the cadaver were normal in every aspect.

## DISCUSSION

The anatomical variations of inferior epigastric vessels are well documented. Tanyeli et al. [6] described a deep femoral artery with four variations in a 72-year-old male cadaver. In this case, the inferior epigastric artery originated from the proximal part of the deep femoral artery [1]. In another case, Sarikcioglu and Sindel [4] reported some multiple vessel variations in the retro pubic region of a male cadaver. In this case, the obturator artery had its origin from the external iliac artery, and the inferior epigastric artery originated from the femoral artery. Additionally, an anastomosis between the obturator and inferior epigastric veins was observed [2]. Sanudo et al. [3] observed arterial variations of this region in two cadavers. In these cases, the obturator, inferior epigastric artery, and medial circumflex femoral artery arose from a common trunk from the external iliac artery [4]. Shanahan and Jordan [5] found an inferior epigastric artery originating from an anomalous medial circumflex femoral artery.

Due to its surgical relevance, the origin, course, distribution, and anomalies of the inferior epigastric

artery are of great importance during the transposition of the rectus abdominis myocutaneous flaps. The viability of these flaps is dependent on the integrity of their blood supply following transposition or transplantation [3, 4]. Secondly, the inferior epigastric artery may be damaged during inguinal hernia repair. Therefore, the distal origin of the inferior epigastric artery from the femoral artery and the lower drainage of the single inferior epigastric vein to the femoral vein must be taken into consideration by surgeons.

## REFERENCES

1. Aygen E, Kirkil C (2006) Surgical anatomy of the inguinal region. *Turkiye Klinikleri J Surg Med Sci*, 2: 7–14.
2. Jakubowicz M, Czarniawska-Grzesińska M. (1996) Variability in origin and topography of the inferior epigastric and obturator arteries. *Folia Morphol*, 55: 121–126.
3. Sanudo JR, Roig M, Rodriguez A, Ferrerira B, Domech JM (1993) Rare origin of the obturator, inferior epigastric and medial circumflex femoral arteries from a common trunk. *J Anat*, 183: 161–163.
4. Sarikcioglu L, Sindel M (2002) Multiple vessel variations in retro pubic region. *Folia Morphol*, 61: 43–45.
5. Shanahan D, Jordan RK (1997) Rare origin of the inferior epigastric artery from an anomalous medial circumflex femoral artery. *J Anat*, 191: 611–613.
6. Tanyeli E, Yildirim M, Uzel M, Vural F (2006) Deep femoral artery with four variations: a case report. *Surg Radiol Anat*, 28: 211–212.