

Variations in hepatic vascularisation: lack of a proper hepatic artery. Two case reports

A.M. Gurgacz, A. Horbaczewska, W. Klimek-Piotrowska, J. Walocha

Department of Anatomy, Collegium Medicum, Jagiellonian University, Kraków, Poland

[Received 10 December 2010; Accepted 2 February 2011]

The blood supply of the liver and other abdominal organs plays a significant role during abdominal surgery. Knowledge of the most common patterns of vascularisation should be broadened and new anomalies of the celiac trunk and its branches dutifully reported. This paper presents two case reports which describe the lack of a proper hepatic artery. Case 1 describes the cadaver of a 64-year-old female in whom the right hepatic artery was observed to arise from the common hepatic artery and run behind the portal vein. The common hepatic artery was observed to be divided into three terminal vessels: the left hepatic artery, the gastroduodenal artery, and the right gastric artery. Case 2 describes the cadaver of a 75-year-old male with a liver that was supplied from 3 different sources: the left hepatic artery from the left gastric artery (which arose directly from the aorta), the right hepatic artery from the superior mesenteric artery, and the middle hepatic artery from the common hepatic artery — (branch of the hepato-splenic trunk). Moreover, the left inferior phrenic artery arose from the left hepatic artery. (Folia Morphol 2011; 70, 2: 130–134)

Key words: accessory hepatic artery, middle hepatic artery, liver blood supply

INTRODUCTION

Knowledge of anatomical variants in hepatic vascular structures is of great importance in general surgery, especially hepatic surgery. This knowledge is also of great importance with regard to liver transplantations, laparoscopic surgeries, radiological procedures, and the treatment of penetrating injuries involving the peri-hepatic area. In the most common pattern of vascularisation, the arterial supply of the liver comes from the common hepatic artery (CHA), originating from the celiac trunk (CTr). The CHA divides into the gastroduodenal artery (GDA) and the proper hepatic artery (PHA). The PHA then branches into the left and right hepatic branches. Variations in this dominant scheme occur in 25% to 75% of cases [6]. The lobes of the liver may receive their blood supply from the superior mesenteric artery (SMA), left gastric artery (LGA),

aorta, or from other visceral branches. These vessels may be replaced, functioning as the primary arterial supply to the lobe, or if they perform an accessory function, constitute an addition to the normal blood supply. They are often smaller but functionally essential and have a specific distribution in every case. An international classification describing the principal variations in the vascular anatomy of the liver was proposed by many authors, among them: Adachi (1928) [2], Michels (1966) [9], Hiatt et al. (1994) [6], and Abdullah et al. (2006) [1]. Despite accurate studies based on large groups of subjects, there are still some rare hepatic variations which are not found in these classifications. They are the benchmark for all subsequent contributions in this area. Each and every description of anomalous hepatic blood supply is of great importance. For this reason, we decided to present two in-

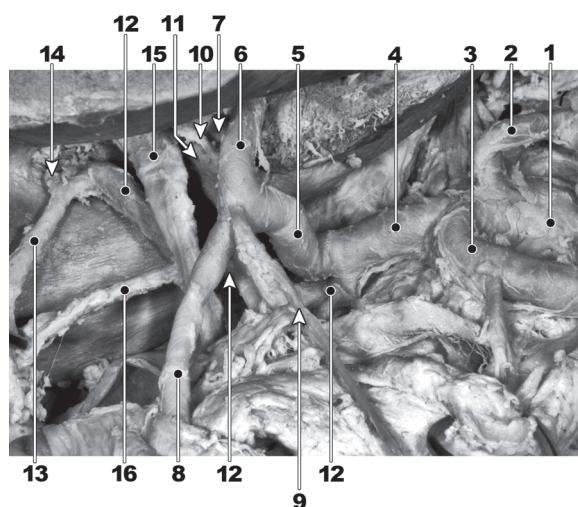
Address for correspondence: J. Walocha, Department of Anatomy, Collegium Medicum, Jagiellonian University, Kopernika 12, 31–034 Kraków, Poland, tel/fax: +48 12 422 95 11, e-mail: jwalocha@cm-uj.krakow.pl

interesting cases of hepatic vascularisation anomalies revealed during routine dissection and carried out at the Department of Anatomy, Jagiellonian University, Cracow. Both revealed a lack of the PHA, along with the presence of atypical right and left hepatic arteries.

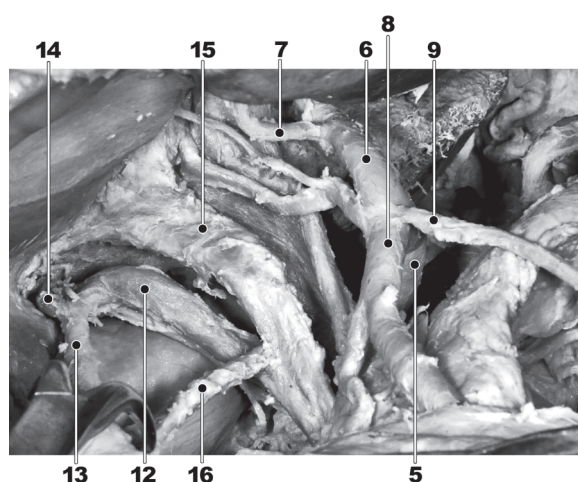
CASE REPORT

Case 1, concerning an anomalous origin of the right hepatic artery, was observed in the cadaver of a 64-year-old female. The CTr was typically divided into three branches: left gastric artery (LGA), splenic artery (SA), and common hepatic artery (CHA). The CHA passed towards the liver and after a course of about 1.5 cm gave rise to the right hepatic artery (RHA). It then bent ventrally, running approximately 3 cm, eventually trifurcating into the left hepatic artery (LHA), GDA, and right gastric artery (RGA). The RHA originated from the inferior circumference of the CHA and was directed to the right and upwards, dorsally with respect to the aforementioned trifurcation of the CHA and common hepatic duct. It then ran dorsally to the portal vein (PV). Just before entering the porta hepatis and supplying the right hepatic lobe, it gave rise to the cystic artery (CA), which supplied the gallbladder. The LHA gave rise to a short common stem of two weaker branches, running towards the quadrate lobe and porta hepatis and traversing on the left side of the common hepatic duct. Approximately 1.3 cm above this point there was another stronger branch of the LHA ascending to the left hepatic lobe. The LHA entered the porta hepatis on the ventral circumference of the portal vein (Fig. 1).

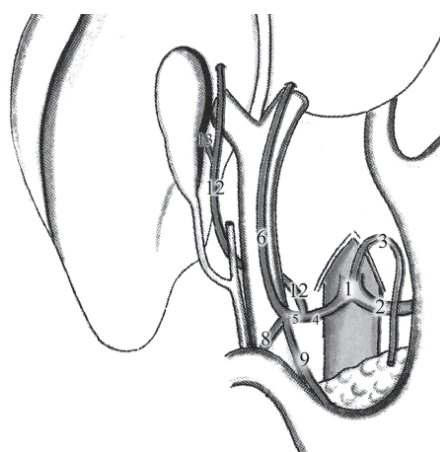
In case 2, during the anatomical dissection of the cadaver of an approximately 75-year-old male, a triple arterial blood supply of the liver was found. The hepatosplenic trunk (HST) and LGA arose from the aorta separately. The LGA gave off the LHA, which ran to the porta hepatis and left lobe of the liver (segments II, III). Three small arteries branched off the LHA: two of them ran to the lesser curvature and the fundus of the stomach, while one vessel ran under the left triangular ligament to the diaphragm. For this reason, it was called the left inferior phrenic artery (IPA). The HST, after a 2 cm course, divided into two arteries: the SA and the CHA. The CHA was directed upwards, approached the common hepatic duct and the PV, and divided into the GDA and middle hepatic artery (MHA). The MHA ran along and ventrally to the PV, then gave rise to the RGA and ran upwards, entering the porta hepatis on the right side of the PV before dividing into two branches — both proceeding to the quadrate lobe (segment IV). The RHA was observed to arise from the superior mesenteric artery (SMA). The RHA ran behind the PV and



A



B



C

Figure 1A, B, C. A photograph and a scheme of the liver vascularisation pattern; 1 — celiac trunk; 2 — left gastric artery; 3 — splenic artery; 4 — common hepatic artery; 5 — common stem of left hepatic artery (LHA), right gastric artery (RGA), and gastroduodenal artery (GDA); 6 — left hepatic artery; 7 — right branch of left hepatic artery; 8 — gastroduodenal artery; 9 — right gastric artery; 10 — branch of left hepatic artery to quadrate lobe; 11 — branch of left hepatic artery to porta hepatis; 12 — accessory right hepatic artery; 13 — cystic artery; 14 — branch of right hepatic artery; 15 — common hepatic duct; 16 — cystic duct.

bile duct, and then between the hepatic duct and cystic duct. It gave rise to the CA and entered the right lobe of the liver behind the gallbladder, supplying segments V–VIII (Figs. 2, 3)

DISCUSSION

Following Adachi's subdivision [2], we classified the variation observed in case 1 as type 1 group 7 — typical trifurcation of the CT, GDA arising from the CHA regardless of the presence of PHA. The anomalous RHA, combined with the lack of the PHA, made classification of this case ambiguous. Due to the fact that it runs on the dorsal circumference of the portal vein (which is not a common case) and then up to the liver, the vessel should be named "accessory RHA (aRHA)" [2]. However, this suggests the presence of a typical RHA — absent in this case. This is why we named the artery RHA, emphasizing its role in the vascularisation of the right segments of the liver, even though the RHA normally arises from the PHA. Cases in which the RHA arises from the CHA were not taken into consideration in Adachi's [2] criteria. In the classification established by Michels [9] and modified by Hiatt [6], this arterial pattern generally belongs to type 1, which is the most common pattern and is found in 55% [9] to 75% [6] of cases. This category describes the CHA arising from the CTr and giving rise to the GDA. However, there is a dissimilarity concerning the further course of the CHA. We cannot name it the "proper hepatic artery" due to the presence of the RHA arising from the CHA and giving rise to the cystic artery, which usually arises from the right branch of the PHA (RbPHA).

In the study by Yang et al. [14] replaced or accessory RHAs originating from the CTr, CHA, or GDA constituted 1.54% of cases (where "replaced" means that the PHA was absent, while "accessory" means that the PHA coexisted, according to Wang and Fröber [13]).

Abdullah et al. [1] based their classification on the source of hepatic arterial supply. Taking this into consideration, the presented case 1 pertains to group 1, which shows variations of the CHA and its branches. A more detailed classification is not possible because of the lack of criteria matching this anomaly. However, one case described in that study draws comparison to case 1, as it describes a trifurcation of the CHA into the PHA, GDA, and RGA. The report of case 1 describes a trifurcation of the CHA into the GDA and RGA, but not the PHA (because 3 cm before, the CHA gave off the RHA), meaning that the third branch of this trifurcation is labelled as the LHA. This is why we cannot place this variation into Abdullah's classification. A very similar case report was presented by Polguy




Figure 2. A photograph of the liver vascularisation pattern; 1 — left gastric artery; 2 — left hepatic artery; 3 — gastric branch; 4 — left inferior phrenic artery; 5 — hepatosplenic trunk; 6 — splenic artery; 7 — common hepatic artery; 8 — gastroduodenal artery; 9 — middle hepatic artery; 10 — right hepatic artery; 11 — common hepatic duct; 12 — cystic duct; 13 — common bile duct; 14 — portal vein.

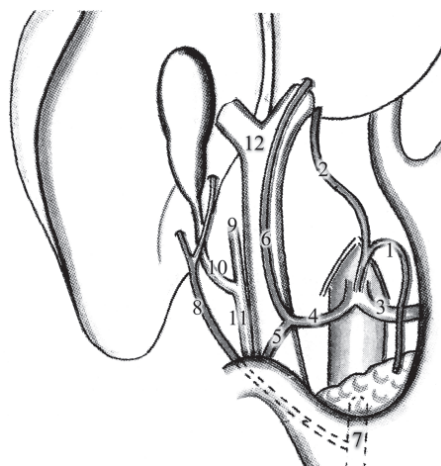


Figure 3. A scheme of the liver vascularisation during embryological development; 1 — left gastric artery; 2 — left hepatic artery; 3 — splenic artery; 4 — common hepatic artery; 5 — gastroduodenal artery; 6 — proper hepatic artery; 7 — superior mesenteric artery; 8 — right hepatic artery; 9 — common hepatic duct; 10 — cystic duct; 11 — bile duct; 12 — portal vein.

et al. [11]. In this case report, the CHA passed in the direction of the liver and after a 9 mm course gave rise to the aRHA. Then, after 3.2 cm and in front of hepatic portal vein, it divided into the PHA and GDA. The aRHA ran behind the portal vein and then entered the right lobe of the liver, similarly to the RHA in case 1. It is not possible to describe the differences between these cases, since in that study the RGA was not observed.

Considering Adachi's classification [2], case 2 can be assigned to the second type of vascularisation.

Table 1. Types of hepatic arterial variation by Michels and Hiatt, frequency of hepatic arterial variation

No.	Type/research	Michels types	Michels (1966) n = 200	De Cecco et al. (2009) n = 250	Hiatts types	Hiatt et al. (1994) n = 1000	Arjhansiri et al. (2006) n = 200	Koops et al. (2004) n = 604
1	Normal	I	55%	66%	1	75.7%	80.5%	79.1%
2	Replaced LHA (from LGA)	II	10%	5.2%	2	9.7%	5.5%	3%
3	Accessory LHA (from LGA)	V	8%	5.2%				
4	Replaced RHA (from SMA)	III	11%	9.2%	3	10.6%	11.5%	11.9%
5	Accessory RHA (from SMA)	VI	7%	4%				
6	Replaced LHA and RHA	IV	1%	2%	4	2.3%	0.5%	1.4%
7	Accessory LHA and RHA	VII	1%	2%				
8	Replaced LHA & accessory RHA							
9	Replaced RHA & accessory LHA	VIII	2%	0.6%				
10	CHA from SMA	IX	3%	2%	5	1.5%	0.5%	2.8%
11	CHA from LGA	X	3%					
12	CHA from aorta				6	0.2%		
13	Unclassified			3.3%			1.5%	4.6%

CHA — common hepatic artery; LGA — left gastric artery; LHA — left hepatic artery; RHA — the right hepatic artery; SMA — superior mesenteric artery

The second type of vascularisation means that the HST and LGA arise from the aorta. It was hard to assign this case to any group defined by Adachi; however, case 2 has the most in common with group 17. This group describes the existence of an aLHA (in case 2: replaced LHA) and an aRHA arising from the SMA. Such an anomaly was present in 0.4% of cadavers dissected by Adachi.

In case 2, the LHA seemed to be stronger than the LGA, which was also described by Adachi.

A replaced LHA and RHA was classified by Michels [9] as type IV, and as type 4 by Hiatt [6]. This was found in 0.5%, 0.83%, 1%, 1.4%, 2%, 2.3%, and 6.4% of cases in the research of Arjhansiri et al. (2006) [3], Yang et al. (2007) [14], Michels (1966) [9], Koops et al. (2004) [7], De Cecco et al. (2009) [5], Hiatt (1994) [6], and Abdullah et al. (2006) [1], respectively.

The classifications developed by Michels and Hiatt, along with the percentages of each case in different studies, are given in Table 1 (Fig. 4). The described case 2 presented with a lack of the PHA, as the CHA, after giving rise to the GDA, gave off the right gastric artery and supplied only the quadrate lobe (segment IV). An artery which supplies only segment IV and arises from its parent artery within the hepatoduodenal ligament was defined by Michels as the middle hepatic artery (MHA). According to the classification proposed by Abdullah et al. [1], the observed case 2 belongs to type G2 III. A similar scheme of hepatic blood supply originating from three different sources was reported

by Wang and Fröber [13]. The main difference between case 2 and the case report presented by Wang is that in case 2, trifurcation of the CTr is lacking.

Hepatic artery anomalies have their origins in embryological development. Stem vessels involved in the angiogenesis of the celiac-mesenteric arterial system include the ventral splanchnic arteries, which arise from the aorta. They generate four roots, connected to each other through longitudinal anastomoses at different levels. Afterwards, two of them (the second and the third) are obliterated, leaving the first and the fourth united by a ventral longitudinal anastomosis. The first root, also called the primitive celiac axis, gives rise to the CHA, LGA, and SA. The fourth root gives rise to the SMA. The CHA, LGA, and SMA give off arteries which supply the liver (Fig. 3). The observed case looks like complete persistence of the foetal pattern.

The IPA is usually a paired vessel that arises from the aorta above the CTr on both sides. Multiplications of this artery are common, as well as variations in regards to its origin. An IPA arising from the celiac trunk was also observed by Cavdar et al. [4]. The frequency of each case was described by Piao et al. [10] and Loukas et al. [8] and is given in Table 2. Detailed research provided by Tanaka et al. [12] showed that the left IPA rarely arises from the LHA (0.5%) and LGA (0.65%), as well as from the aLHA (0.4%) and aLGA (0.1%). This knowledge is essential to avoid postoperative complications, with par-

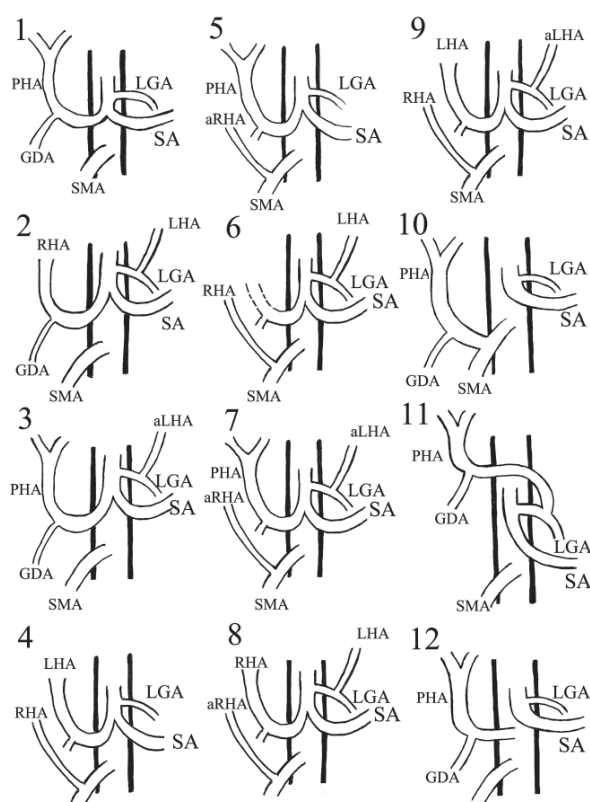


Figure 4. A schematic view of variants of arterial liver vascularisation; 1 — normal; 2 — replaced left hepatic artery (LHA) (from left gastric artery [LGA]); 3 — accessory left hepatic artery (aLHA) (from left gastric artery); 4 — replaced right hepatic artery (RHA) (from superior mesenteric artery [SMA]); 5 — accessory right hepatic artery (from SMA); 6 — replaced left hepatic artery and right hepatic artery; 7 — accessory left hepatic artery and right hepatic artery; 8 — replaced left hepatic artery and accessory right hepatic artery (aRHA); 9 — replaced right hepatic artery and accessory left hepatic artery; 10 — common hepatic artery from superior mesenteric artery; 11 — common hepatic artery from left gastric artery; 12 — common hepatic artery from aorta; PHA — proper hepatic artery; GDA — gastroduodenal artery; SA — splenic artery.

Table 2. The frequency of the inferior phrenic artery arising from different arteries

	Piao et al. (1998) n = 138	Loukas et al. (2005) n = 330	
		Right	Left
Aorta	61.6%	38%	45%
Celiac trunk	28.2%	40%	47%
Renal artery	4.3%	17%	5%
Adrenal artery	2.9%		
Left gastric artery		3%	2%
Left hepatic artery		2%	1%

tial paralysis of the diaphragm amongst known complications.

We report on some rare variations that have never been described before. Knowledge of the arterial variation in this area is very important during surgical and radiological procedures.

REFERENCES

1. Abdullah SS, Mabrut JY, Garbit V, De La Roche E, Olgne E, Rode A, Morin A, Berthezene Y, Baulieux J, Ducerf C (2006) Anatomical variations of the hepatic artery: study of 932 cases in liver transplantation. *Surg Radiol Anat*, 28: 468–473.
2. Adachi B (1928) *Das Arteriensystem der Japaner*. Kyoto: Verlag der kaiserlich-japanischen Universität zu Kyoto, pp. 18–71.
3. Arjhansiri K, Charoenrat P, Kitsukjit W (2006) Anatomic variations of the hepatic arteries in 200 patients done by angiography. *J Med Assoc Thai*, 89 (suppl. 3): S161–S168.
4. Cavdar S, Gurbuz J, Zeybek A, Sehirlı U, Abik L, Ozdogmus O (1998) A variation of coeliac trunk. *Kaibogaku Zasshi*, 73: 505–508.
5. De Cecco CN, Ferrari R, Rengo M, Paolantonio P, Vecchiotti F, Laghi A (2009) Anatomic variations of the hepatic arteries in 250 patients studied with 64-row CT angiography. *Eur Radiol*, 19: 2765–2770.
6. Hiatt JR, Gabbay J, Busutil RW (1994) Surgical anatomy of the hepatic arteries in 1000 cases. *Ann Surg*, 220: 50–52.
7. Koops A, Wojciechowski B, Broering DC, Adam G, Krupski-Berdién G (2004) Anatomic variations of the hepatic arteries in 604 selective celiac and superior mesenteric angiographies. *Surg Radiol Anat*, 26: 239–244.
8. Loukas M, Hullett J, Wagner T (2005) Clinical anatomy of the inferior phrenic artery. *Clin Anat*, 18: 357–365.
9. Michels NA (1966) Newer anatomy of the liver and variant blood supply and collateral circulation. *Am J Surg*, 112: 337–347.
10. Piao DX, Ohtsuka A, Murakami T (1998) Typology of abdominal arteries, with special reference to inferior phrenic arteries and their esophageal branches. *Acta Med Okayama*, 52: 189–196.
11. Polguy M, Gabrysiak T, Topol M (2010) The right accessory hepatic artery; a case report and review of the literature. *Surg Radiol Anat*, 32: 175–179.
12. Tanaka R, Ikebukuro K, Akita K (2008) The left inferior phrenic artery arising from left hepatic artery or left gastric artery: radiological and anatomical correlation in clinical cases and cadaver dissection. *Abdom Imag*, 33: 328–333.
13. Wang BG, Fröber R (2009) Accessory extrahepatic arteries: Blood supply of a human liver by three arteries. A case report with brief literature review. *Ann Anat*, 191: 477–484.
14. Yang Y, Jiang N, Lu MQ, Xu C, Cai CJ, Li H, Yi SH, Wang GS, Zhang J, Zhang JF, Chen GH (2007) Anatomical variation of the donor hepatic arteries: analysis of 843 cases. *Nan Fang Yi Ke Da Xue Xue Bao*, 27: 1164–1166.