

Anatomical variants of the emissary veins: unilateral aplasia of both the sigmoid sinus and the internal jugular vein and development of the petrosquamosal sinus. A rare case report

O. Kiritsi¹, G. Noussios², K. Tsitas³, P. Chouridis⁴, D. Lappas⁵, K. Natsis⁶

¹"Hippocrates" Diagnostic Centre of Kozani, Greece

²Laboratory of Anatomy in Department of Physical Education and Sports Medicine at Serres,
"Aristotle" University of Thessaloniki, Greece

³Orthopaedic Department of General Hospital of Kozani, Greece

⁴Department of Otorhinolaryngology of "Hippokratation" General Hospital of Thessaloniki, Greece

⁵Department of Anatomy of Medical School of "National and Kapodistrian" University of Athens, Greece

⁶Department of Anatomy of the Medical School of "Aristotle" University of Thessaloniki, Greece

[Received 9 August 2011; Accepted 25 September 2011]

We report a case of hypoplasia of the right transverse sinus and aplasia of the ipsilateral sigmoid sinus and the internal jugular vein. In addition, development of the petrosquamosal sinus and the presence of a large middle meningeal sinus and sinus communicans were observed. A 53-year-old Caucasian woman was referred for magnetic resonance imaging (MRI) investigation due to chronic headache. On the MRI scan a solitary meningioma was observed. Finally MR 2D venography revealed this extremely rare variant. (Folia Morphol 2011; 70, 4: 305–308)

Key words: hypoplasia, right transverse sinus, aplasia, ipsilateral sigmoid sinus, petrosquamosal sinus, internal jugular vein

INTRODUCTION

Emissary veins participate in the extracranial venous drainage of the dural sinuses of the posterior fossa, complementary to the internal jugular vein (IJV). In case of aplasia or thrombosis of the IJV, emissary veins are responsible for draining the blood from the posterior fossa. Morphological changes in the aforementioned venous structures are related to brain development [14]. Our purpose is to present a case of petrosquamosal sinus (PSS) development and its embryogenesis. Furthermore, we discuss its potential role in the spread of external auditory canal infections and in middle-ear surgery complications.

CASE REPORT

A 53-year-old Caucasian woman was referred for magnetic resonance imaging (MRI) investigation due to chronic frontal headache complaints. MRI examination revealed a solitary meningioma along the posterior portion of the falx, measuring 2.67 × 3.5 × 1.75 cm (Fig. 1). MR 2D venography showed hypoplasia of the right transverse sinus and aplasia of both the ipsilateral sigmoid sinus and the IJV. In addition, we observed development of the PSS and its relationship with sinus communicans (Fig. 2). Furthermore, we noticed large posterior condylar and mastoid emissary veins on the contralateral side (Fig. 3). The meningioma was asymptomatic, so no other medical action was taken.

Address for correspondence: Ass. Prof. G. Noussios, MD, PhD, Laboratory of Anatomy in Department of Physical Education and Sports Medicine at Serres, "Aristotle" University of Thessaloniki, Vassileos Georgiou 34, 546 40-Thessaloniki, Greece, tel: +30 2310855012, fax: +30 2310830101, e-mail: geornous@hotmail.com

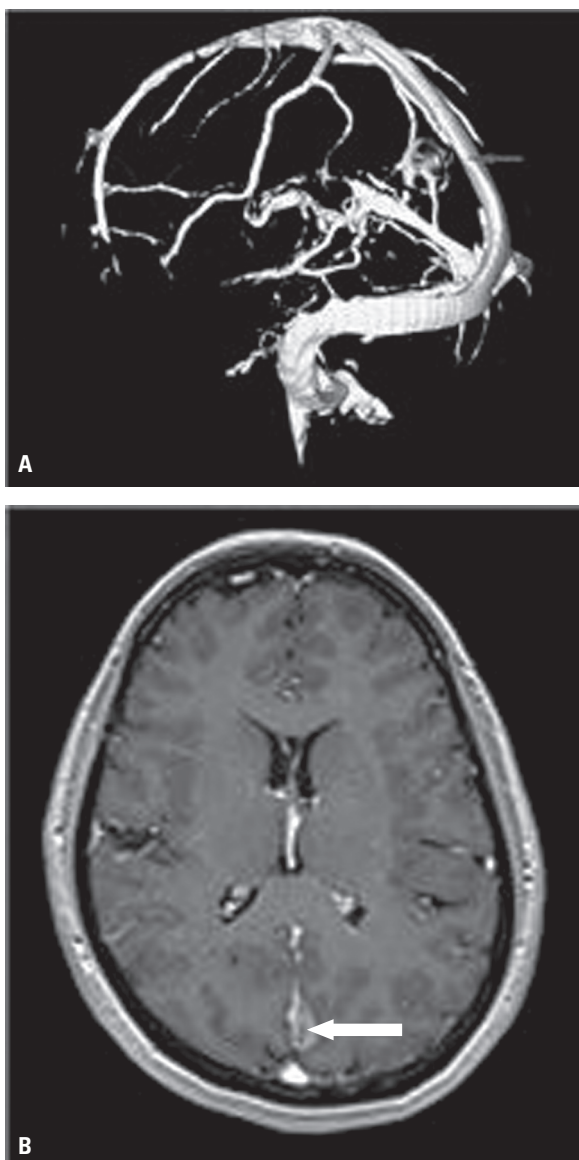

Figure 1. Meningioma along the posterior portion of the falx (arrow); **A.** Magnetic resonance 2D venography; **B.** T1 3D post gadolinium.

DISCUSSION

The development of cerebral venous drainage pathways has been well investigated in anatomical studies [6, 10]. However, only in recent years has the pathway of the PSS been cited in radiologic literature [5]. The IJV is the foremost vessel of cerebral venous drainage. It is shaped by the merging of the lateral sinus inion with the inferior petrous vein. The transverse sinus begins at the inion, passes lateralward and forward, in a slight curve which is convex upward, to the base of the petrous part of the temporal bone [13]. The sigmoid sinus drains from the transverse sinus and begins beneath the temporal bone and follows a tortuous course to the jugular

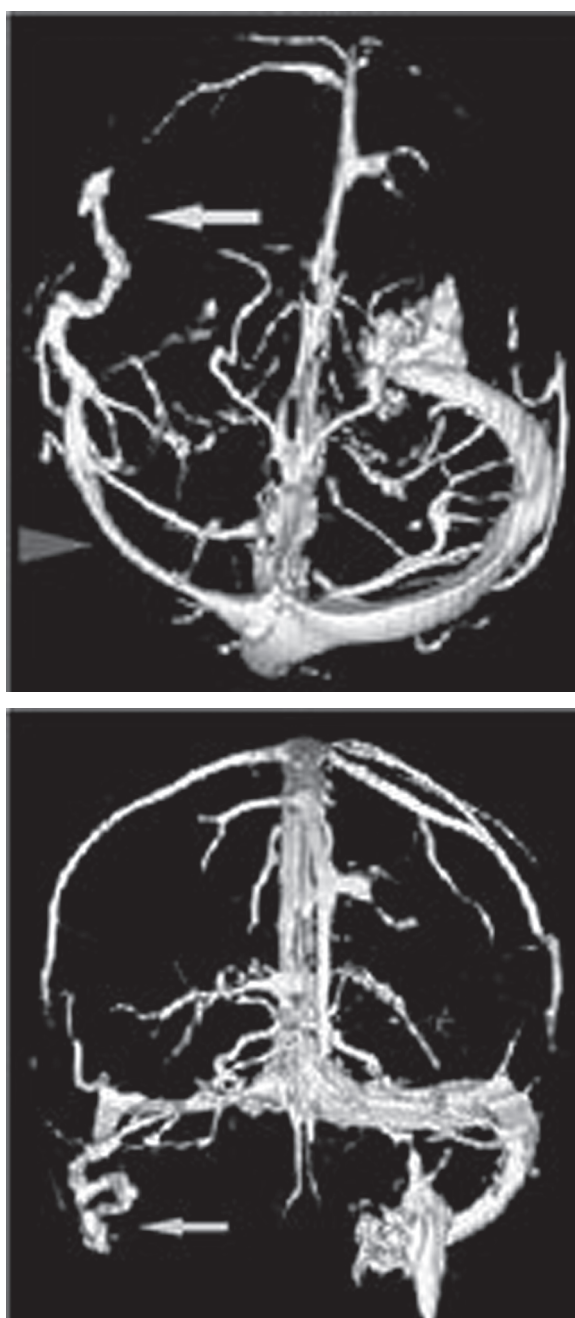


Figure 2. Magnetic resonance 2D venography. Hypoplasia of the transverse sinus (arrowhead). Presence of the petrosquamosal sinus and its relationship to the sinus communicans (arrow).

foramen, at which point the sinus becomes continuous with the IJV (Fig. 4). As mentioned by Marsot-Dupuch et al. [8], these sinuses are underdeveloped during early foetal life and maintain their small calibre until 2 years after birth. Variations in the course of the sigmoid sinus appear to arise during the 8th and 9th months of foetal life and are influenced by the development of the cerebellum.

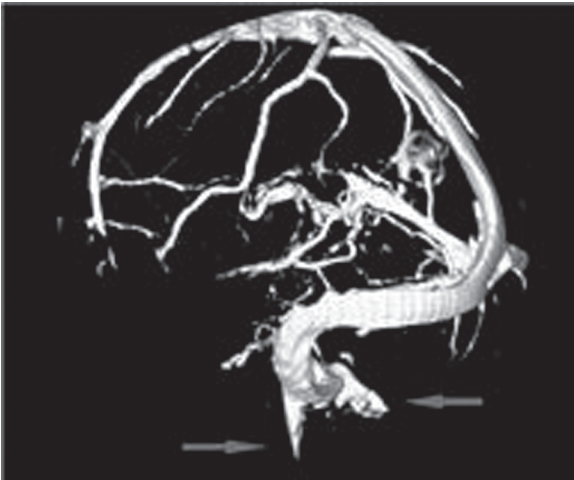


Figure 3. Magnetic resonance 2D venography revealing enlarged emissary veins (the posterior condylar and the mastoid) and a sigmoid sinus of normal calibre on the left side.

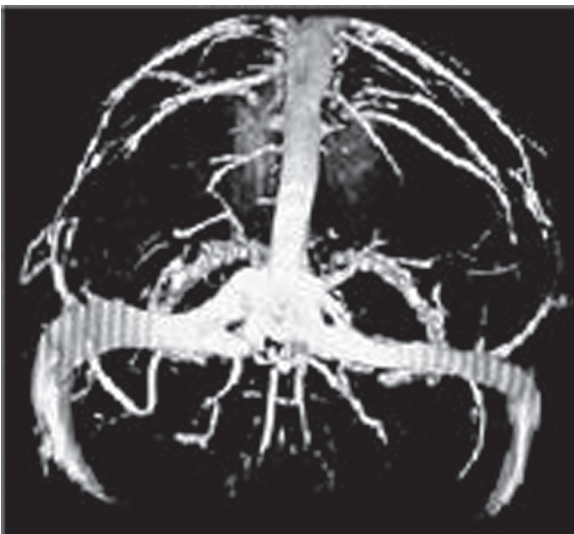

Figure 4. Normal appearance of the lateral sinus.

The evolvement of the encephalic veins and their extracranial drainage is Daedalean in humans [14]. The main vessel network of the early embryo advances in three layers. The superficial vessels drain into the external jugular vein as the middle and deep vessels derivate into the IJV. Emissary veins are composed of the remaining connections between the superficial and middle layers and may be crucial for the foetal circulation. They emanate from the sigmoid sinus and constantly on the left side, thus the emissary veins play a major role in the equalisation of the intracranial pressure and can act as safety

valves [12]. Large emissary veins drive to an underdeveloped sigmoid sinus. It is presumed that the horizontal and sigmoid portions of the lateral sinus advance at diverse times and if the sigmoid segment fails to develop, the horizontal portion would outgo the cranium through enlarged emissary veins. In our case, both enlarged emissary veins (the posterior condylar and the mastoid) and a sigmoid sinus of normal calibre were observed on the left side (Fig. 3). Additionally, aplasia of the sigmoid sinus and development of the PSS were revealed on the contralateral side (Fig. 2).

The leading emissary veins are elaborate on the supra, middle, and inferior thirds of the sigmoid sinus. Thus the triplets of these venous pathways are the lower or posterior condylar vein, which outgoes just above the jugular bulb, the middle or mastoid emissary vein, the most constant of which crosses the mastoid foramen and consolidates the sigmoid sinus with the posterior auricular or occipital vein, and a tiny vessel, the upper petrosquamosal emissary vein, initiating at the connection of the transverse and sigmoid sinus.

Emissary vein canals can become thickened in any case of abnormally vascular high-flow or in severe hypoplasia or even aplasia of the jugular veins, which may occur in abnormalities of the skull base such as craniosynostosis [7]. The thickened veins can also give a loud "venous" pulsatile bruit according to the degree of their expansion, characteristic in vascular tinnitus [9]. It is hypothesised that the vulnerability of these abnormal veins during middle ear surgery or translabyrinthine routes to the posterior fossa may cause uncontrollable surgical bleeding or postoperative thrombosis of the sigmoid sinus. Furthermore, retrograde spread of infection or tumours of the external auditory canal may be promoted by this developmental venous variant. Therefore, its description should be systematically included in temporal bone computed tomography (CT) and cerebral MR venography [11].

The diameter of these veins may occasionally be as large as 2 to 4 mm [8]. The PSS initiates at the unification point between the transverse and sigmoid sinuses, coursing horizontally above the petrosquamosal suture of the temporal bone, which is located at the union of the petrous and squamous bones and plays a major role in the variations of mastoidectomy [4]. One report has described a remaining vascular tract in the midportion of the petrosquamosal suture, arising from an ascending branch of the occipital artery and showing possible cessation of the embryologic develop-

ment causing the persistent PSS [3]. The PSS ends via the foramen retroarticulare, and through this the blood flowing in the PSS is directed into the retromandibular vein and then into the external jugular vein [2]. In our case a large PSS was noticed on one side in close relationship to the sinus communicans (Fig. 2).

In one study an abnormal vessel was found originating from the sigmoid sinus of each patient. The vessels coursed anteroinferiorly over the superior portion of the temporal bone and terminated near the posterior part of the temporomandibular joint [15].

Some results from various studies suggest that transverse sinus flow gaps or aplasias can be observed in approximately 24% of the normal population on MR imaging. The rate of these gaps in normal subjects must be kept in mind as it can be a source of misdiagnosis in cases of suspected dural sinus thrombosis [1]. It is also believed that in the deformities of the semicircular canals, the incidence of the PSS is quite high. The PSS presents a risk for cochlear implant surgery which can be detected by the neuroradiologist in advance. Venous CT angiography is advisable in certain cases. The previous assumption that persistent PSS is encountered more frequently in cases of skull base deformity can be affirmed in the special situation of complete aplasia of the semicircular canals. The study showed the coexistence of PSS development and complete aplasia of the semicircular canals at about 81% [5].

CONCLUSIONS

In conclusion, the PSS is a rare finding in humans, and parts of its embryological constituents may persist into adult life. More infrequently it may become a major outflow trail of the transverse sinus when the sigmoid sinus is underdeveloped or absent, converting the external jugular vein to the foremost encephalic outflow pathway in the affected side. Modern imaging techniques allow the exact recognition of the PSS, which, especially when oversized, may be of clinical importance as it may represent a haemorrhagic hazard during surgical procedures of the mastoid regions. Extreme care should also be taken during surgical procedures, as the sacrifice of this outflow pathway could lead to fatal venous ischaemic and haemorrhagic consequences. Knowledge of the anatomy of the PSS and its variations in adult humans is therefore significant for anatomists and clinicians.

REFERENCES

1. Alper F, Kantarci M, Dane S, Gumustekin K, Onbas O, Durur I (2004) Importance of anatomical asymmetries of transverse sinuses: an MR venographic study. *Cerebrovasc Dis*, 18: 236–239.
2. Berge JK, Bergman RA (2001) Variations in size and in symmetry of foramina of the human skull. *Clin Anat*, 14: 406–413.
3. Choudry R, Raheja S, Gaur V, Choudry S, Anand C (1996) Mastoid canals in adult human skulls. *J Anat*, 188: 217–219.
4. Deveze A, Rameh C, Puchol MS, Lafont B, Lavieille JP, Magnan J (2010) Rehabilitation of canal wall down mastoidectomy using a titanium ear canal implant. *Otol Neurotol*, 31: 220–224.
5. Gieseemann AM, Goetz GF, Neuburger J, Lenarz T, Lanfermann H (2011) Persistent petrosquamosal sinus: high incidence in cases of complete aplasia of the semicircular canals. *Radiology*, 259: 825–833.
6. Gisolf J, van Lieshout JJ, van Hausden K, Pott F, Stok WJ, Karemaker JM (2004) Human cerebral venous outflow pathway depends on posture and central venous pressure. *J Physiol*, 560: 317–327.
7. Jeevan DS, Anlsow P, Jayamohan J (2008) Abnormal venous drainage in syndromic craniosynostosis and the role of CT venography. *Childs Nerv Syst*, 24: 1413–1420.
8. Marsot-Dupuch K, Gayet-Delacroix M, Elmaleh-Bergès M, Bonneville F, Lasjaunias P (2001) The petrosquamosal sinus: CT and MR findings of a rare emissary vein. *Am J Neuroradiol*, 22: 1186–1193.
9. Mehanna R, Shaltoni H, Morsi H, Mawad M (2010) Endovascular treatment of sigmoid sinus aneurysm presenting as devastating pulsatile tinnitus. A case report and review of literature. *Interv Neuroradiol*, 16: 451–454.
10. Menegatti E, Zamboni P (2008) Doppler haemodynamics of cerebral venous return. *Curr Neurovasc Res*, 5: 260–265.
11. Quesnel S, Nguyen M, Pierrot S, Contencin P, Manach Y, Couloigner V (2010) Acute mastoiditis in children: a retrospective study of 188 patients. *Int J Pediatr Otorhinolaryngol*, 74: 1388–1392.
12. Rossi AC, Freire AR, Prado FB, Caria PHF, Botacin PR (2010) Morphological characteristics of foramen of Vesalius and its relationship with clinical implications. *J Morphol Sci*, 27: 26–29.
13. Strydom MA, Briers N, Bosman MC, Steyn S (2010) The anatomical basis of venographic filling defects of the transverse sinus. *Clin Anat*, 23: 153–159.
14. Tanoue S, Kiyosue H, Sagara Y, Hori Y, Okahara M, Kashiwagi J, Mori H (2010) Venous structures at the craniocervical junction: anatomical variations evaluated by multidetector row CT. *Br J Radiol*, 83: 831–840.
15. Yong-Hwi A, Jee Hye W, Kyu-Hee H, Young Ho K (2011) Two cases of petrosquamosal sinus in the temporal bone presented as perioperative finding. *Laryngoscope*, 121: 381–384.