

Bilateral superficial ulnar artery with high origin from the axillary artery: its anatomy and clinical significance

G. Gupta¹, K. Singh¹, S. Chhabra¹, V. Gupta², I. Kayalvizhi¹

¹Department of Anatomy, Pt. B.D. Sharma PGIMS, Haryana, India

²Department of Pathology, Pt. B.D. Sharma PGIMS, Haryana, India

[Received 22 November 2011; Accepted 15 December 2011]

The superficial ulnar artery (SUA) is a rare anatomical variant that usually arises either in the axilla or the arm and runs a superficial course in the forearm, enters the hand, and participates in the formation of superficial palmar arch. During the routine dissection of cadavers in the department of anatomy, whilst preparing the specimen for medical students, an unusual bilateral branch of the axillary artery was found in one of the cadavers: a rare variant of the artery known as SUA, which originates from the 2nd part of the axillary arteries of both sides. The SUA is a known anatomical variant, but the bilateral high origin from the 2nd part of the axillary artery is extremely unusual. Its occurrence is of great clinical importance to the surgical and radiological departments. (Folia Morphol 2012; 71, 1: 48-51)

Key words: anatomical variant, axillary artery, superficial ulnar artery

INTRODUCTION

The ulnar artery is the larger terminal branch of the brachial artery in the cubital fossa, which is formed near the neck of radius. The ulnar artery, along with the radial artery, supplies the structures of the forearm and the hand as well as the elbow and wrist joints. It mainly participates in the formation of superficial palmar arch but also contributes in the formation of deep palmar arch. Arterial variations of the upper limb have been well documented by Bergman et al. [3], Rodriguez et al. [14], and Tountas et al. [18]. The presence of superficial ulnar artery (SUA) seems to be a rarely encountered variation [2, 9, 15]. The incidence varies from 0.7% to 9.3% when originating from the axillary artery and running a superficial course in the forearm before entering the hand [4, 11]. In this case report we describe the bilateral presence of SUA which origi-

nated from the 2nd part of the axillary artery. It is clinically important because it may lead to accidental intra-arterial injection or misinterpretation of incomplete angiographic images during surgical procedures on the arm or forearm.

CASE REPORT

During routine dissection of a 35-year-old embalmed male cadaver, an unusual branch was seen on both sides of the upper limb, which arose from the axillary artery. They were dissected and traced on both sides up to their termination, and their course relations and branches were studied.

On the left side the SUA arose from the second part of the axillary artery 1.5 cm proximal to the origin of the subscapular artery between the medial and lateral roots of the median nerve (Fig. 1). The point of origin of SUA was such that the axillary vein

lay on the medial side and the lateral root of the median nerve lay on the lateral side. In the arm the artery ran superficially medial to the median nerve. In the lower part of arm it pierced the brachial fascia to enter the forearm. At the elbow it lay below the deep fascia covering the origin of the flexor muscles of the forearm. Here it was also crossed by some of the fibres of the pronator teres muscle of ulnar origin. The SUA in the forearm gave off a few branches to the muscles of the forearm. Here it was associated with the absence of the palmaris longus muscle of the forearm. In the hand the SUA had a normal course, which formed the superficial palmar arch with contributions from the superficial branch of the radial artery.

On the right side the SUA arose from the second part of the axillary artery 3.2 cm distal to the thoracoacromial artery and in common origin with the subscapular artery between the junction of the lateral and medial roots of the median nerve (Fig. 2). Then it ran anteromedially to the median nerve and brachial artery along with the cutaneous branches of the medial cord. In the arm it lay on the superficial fascia where it gave one or two small muscular branches to the biceps brachii muscle. Just before entering in the forearm it pierced the brachial fascia and reached into the cubital fossa where it was in close relation with the superficial veins of the fossa. In the forearm it accompanied the superficial veins. On the distal end of the forearm the SUA lied between the tendon of flexor carpi ulnaris and the ulnar nerve. Its further course was similar to that on the left side.

When the SUA is present the usual mode of termination of brachial artery is into the radial and common interosseous arteries, which was similarly seen on the left side in the present case [15]. But on the right side the brachial artery was divided into three arteries radial, anterior interosseous, and posterior interosseous arteries from a single point of origin.

DISCUSSION

SUA is described as a rare and reported anatomical variation of the upper limb. The total overall incidence was well documented by Natis et al. [11], ranging from 0.7% to 9.38%. The origin of SUA from the brachial artery was reported to be 4.2% [15]. However, the frequency of SUA originating from the axillary artery is reported in the literature as varying from 0.17% to 2.0% [11]. The SUA more commonly arose from the brachial artery as compared to the

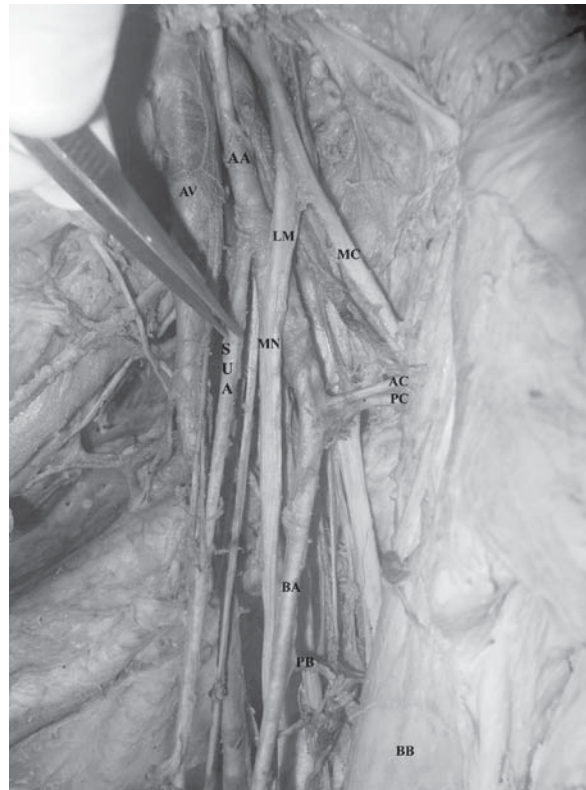


Figure 1. The left superficial ulnar artery (SUA) arising from the 2nd part of the axillary artery; AC — anterior circumflex; AA — axillary artery; AV — axillary vein; BB — biceps brachii; BA — brachial artery; LM — lateral root of median nerve; MN — median nerve; MC — musculocutaneous; PC — posterior circumflex; PB — profunda brachii.

axillary artery, as reported by Rodriguez et al. [15] and was also found in our study.

The ulnar artery is found to be sometimes deviated from the normal course of origin and frequently arises from the lower part of the brachial artery above the elbow [12] and is rarely found to be originating from the axillary artery [11]. Among these, there are certain reports of bilateral origin of SUA [7, 16, 19].

In the present case, on both sides the SUA arose from the second part of the axillary artery proximal to the join of the medial and lateral roots of the median nerve, which was different from the case reported by Shankar et al. in 2009 [16]; in this case it was arising from the axillary artery on the right side, but on the left side the SUA arose from the junction of the upper and middle third of the brachial artery in the front of the arm.

Various authors have reported that SUA lies superficial to the median nerve, which was also a finding in the present case [11, 15, 19], but different from the case reported by Shankar et al.

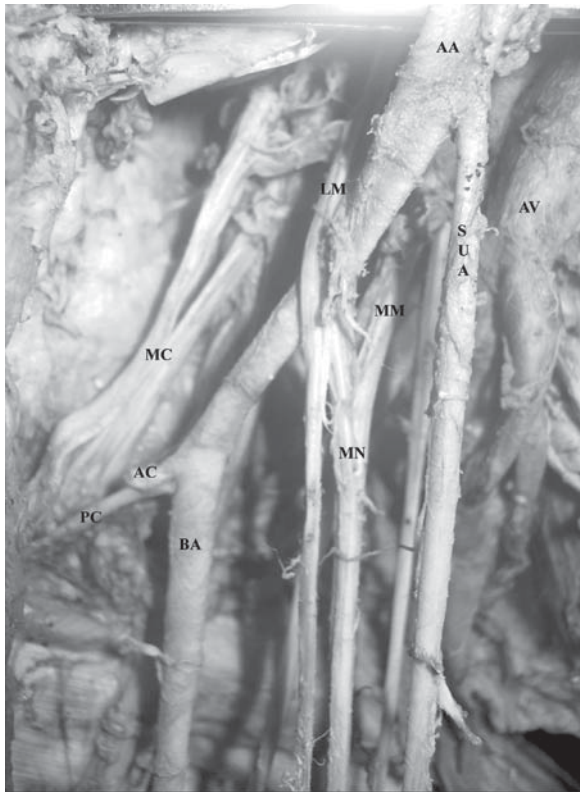

Figure 2. The right superficial ulnar artery (SUA) arising from the axillary artery along with the subscapular artery; AC — anterior circumflex; AA — axillary artery; AV — axillary vein; BA — brachial artery; MM — median root of median nerve; LM — lateral root of median nerve; MN — median nerve; MC — musculocutaneous; PC — posterior circumflex.

[16] in which on the left side the SUA passed deep to the median nerve. In the present case the SUA ran in the subcutaneous plane in the forearm that was superficial to the forearm flexor muscles. Some authors [15] described it as the sub-fascial or subcutaneous plane out of which the sub-fascial course is more common. On the distal end of the forearm on both sides the SUA lay between the flexor carpi ulnaris and ulnar nerve and entered the hand deep into the flexor retinaculum. In the hand the SUA participated in the formation of superficial palmar arch deep into the palmar aponeurosis, which was the usual course of the artery. This sub-fascial plane of the artery was found on the left side, but on the right side it was found below the sub-fascial plane.

In the present case the SUA on both sides gave branches to the biceps brachii, which was also reported by other authors [7, 11, 19]. There were no other branches, such as the superior ulnar collateral artery, inferior ulnar collateral artery, or arterial arch, in the forearm connecting the SUA and radial

artery as seen in the case reported by Shankar et al. [16]. In the present study SUA was associated with the bilateral absence of the palmaris longus, which was also reported previously in a few studies [10, 16].

The SUA anomalies have clinical implications for vascular surgeons and radiologists. They should be aware of possible arterial variations in order to prevent complications during operative and diagnostic procedures. Due to its superficial course in the whole of the upper limb, there is a risk of bleeding during trauma and reconstructive surgical procedures for skin flap transplantation [6, 7]. The persistence of SUA is usually accompanied by a pair of subcutaneous veins, so it may be mistaken for superficial veins, resulting in incorrect intra-arterial drug infusion or venopuncture, which may in turn lead to amputation. The SUA also complicates percutaneous brachial catheterisation. Furthermore, preparation of the free forearm flap with neurosensory potential and radial artery grafting for coronary bypass-like surgical procedure can also be complicated due to the presence of SUA, as cited in the study carried out by Natsis et al. [11].

The diagnosis of SUA should always be carried out by careful palpation of the anti-cubital fossa and forearm during routine preoperative clinical examination. Additionally, confirmative diagnosis should be made by Doppler studies before doing any surgical procedure on the upper limb [8]. If this anatomical variation is diagnosed preoperatively, a reliable skin flap replacement can be made using plastic surgical procedures without any complications. It is also clinically significant in arterial anastomosis performed for haemodialysis [5].

EMBRYOLOGICAL BASIS

For vascular supply of the limb buds, primitive axis arteries are developed. For upper limbs the 7th intersegmental artery forms the basis, which gives rise to the axillary, brachial, and interosseous arteries. Other branches are added subsequently to the axis arteries, out of which the median artery arises first, and then the radial and ulnar arteries are added. The older sprouting theory was initially proposed by Singer in 1933 [17] and was widely accepted until recently.

Poteat [13] modified this sprouting theory in 1986; he reported that all the vascular arteries arise from branching, anastomosis, and selective regression of the axis artery. The theory laid by Poteat [13] was greatly challenged by the study

of Rodriguez et al. [15], according to which the arterial pattern of the upper limb develops from an initial capillary plexus by proximal and distal differentiation due to maintenance, enlargement, and differentiation of certain capillary vessels and regression of others.

However, the reasons for modified arterial development have not yet been clarified. The presence of SUA may be due to haemodynamic forces, chemical factors, and the position of the foetus in the uterus. The genetic predisposition, initial limb movements, and arrest in development during the early embryonic stages are also possible reasons, as cited in the study carried out by Natsis et al. [11].

CONCLUSIONS

The presence of bilateral SUA taking its origin from the axillary artery is a rare variation, and its presence is of great clinical importance. The knowledge of such a variation is important for medical persons especially nursing staff, surgeons, and radiologists. We recommend that preoperative diagnosis of SUA should always be ruled out before performing any surgical or intravenous cannulation, which can be diagnosed by Doppler flow meter. This prior diagnosis enables minimisation of the risk of damaging an artery while performing any surgical or intravenous cannulation.

REFERENCES

1. Adachi B (1928) *Das Arteriensystem der Japaner*. Vol. 1, Kyoto Maruzen Press.
2. Anil A, Turgut HB, Peber TV (1996) A variation of the superficial ulnar artery. *Surg Radiol Anat*, 18: 237–240.
3. Bergman RA, Thomson SA, Afifi AK, Saadeh FA (1988) *Compendium of human anatomic variations*. Urban and Schwarzenberg. Baltimore Munich.
4. Fadel RA, Amonoo-Kuofi HS (1996) The superficial ulnar artery: development and surgical significance. *Clin Anat*, 9: 128–132.
5. Fonseka WR, Rajamantri SD, Sherifdeen AH (2002) Ulnar basilic arteriovenous fistula: an alternative. *Transplant Proc*, 34: 2412.
6. Gormus G, Ozcelik M, Hamdi Celik H, Cekirge S (1998) Variant origin of the ulnar artery. *Clin Anat*, 11: 62–64.
7. Jacquemin G, Lemaire V, Medot M (2001) Bilateral case of superficial ulnar artery originating from axillary artery. *Surg Radiol Anat*, 23: 139–143.
8. McWilliams RG, Sodha I (2000) Doppler ultrasound diagnosis of a superficial ulnar artery. *Eur J Ultrasound*, 12: 155–157.
9. Nakatani T, Tanaka S, Mizubami S, Shiraishi Y, Nakamura T (1996) The superficial ulnar artery originating from the axillary artery. *Anat Anz*, 178: 277–279.
10. Nakatani T, Tanaka S, Mizukami S (1998) Superficial ulnar artery originating from the brachial artery and its clinical importance. *Surg Radiol Anat*, 20: 383–385.
11. Natsis K, Papadopoulou AL, Paraskevas G, Totlis T, Tsikaras P. High origin of a superficial ulnar artery arising from the axillary artery: anatomy, embryology, clinical significance and a review of the literature. *Folia Morphol*, 65: 400–405.
12. Panicker JB, Thilakan A, Chandi G (2003) Ulnar artery: a case report of unusual origin and course. *J Anat Soc India*, 52: 177–179.
13. Poleat WL (1986) Report of rare human variation: absence of the radial artery. *Anat Rec*, 214: 89–95.
14. Rodriguez-Baeza A, Nebot J, Ferreira B, Reina F, Perez J, Sanudo JR, Roig M (1995) An anatomical study and ontogenic explanation of 23 cases with variations in the main pattern of the human brachio-antebrachial arteries. *J Anat* 187; 473–479.
15. Rodriguez-Niedenfuhr M, Vazquez T, Nearn L, Ferreira B, Parkin I, Sanudo JR (2001) Variations of the arterial pattern in the upper limb revisited: a morphological and statistical study, with a review of the literature. *J Anat*, 199: 547–566.
16. Shankar N, Veeramani R (2009) Bilateral superficial ulnar arteries with an unusual arterial arch in the forearm. *IJAV*, 2: 24–26.
17. Singer E (1933) Embryological pattern persisting in the arteries of the arm. *Anatom Record*, 55: 403–409.
18. Tountas CHP, Bergman RA (1993) *Anatomic variations of the upper extremity*. Churchill Livingstone, New York.
19. Yazar F, Kirici Y and Ozan H (1999) An unusual variation of the superficial ulnar artery. *Surg Radiol Anat*, 21: 155–157.