

Thoracic ectopic kidney in adults. A report of 2 cases

Andrzej Drop¹, Elżbieta Czekajska-Chehab¹, Ryszard Maciejewski²,
Grzegorz J. Staśkiewicz², Kamil Torres²

¹Department of Radiology, Medical University of Lublin, Poland

²Department of Human Anatomy, Medical University of Lublin, Poland

[Received 23 June 2003; Accepted 9 July 2003]

Thoracic kidney is the rarest, usually asymptomatic type of kidney ectopia. 2 cases of thoracic kidney discovered incidentally through chest radiography are reported. In both patients renal function tests were normal and no further treatment was necessary. Ultrasonography and computed tomography studies performed for confirmation of the diagnosis are presented. An embryonic background of this abnormality is discussed.

key words: ectopic kidney, thoracic kidney, congenital anomalies

INTRODUCTION

Congenital anomalies of the urinary system affect approximately 10% of the population. Thoracic kidney is the rarest form of renal ectopia. Furthermore, it is usually asymptomatic and discovered incidentally. Some cases of acquired post-traumatic thoracic kidney are published. In the majority of the cases thoracic kidney is detected as a mass on a chest radiograph. Although extremely rare, thoracic kidney should always be considered as a diagnosis of abnormal intrathoracic shadow. Ultrasonography, excretory urography, computed tomography, with or without contrast enhancement, and magnetic resonance imaging are helpful in differential diagnosis. We present 2 cases of this rare anomaly, both discovered by chance through chest radiography and with no history of trauma. The ultrasonography and computed tomography findings are presented.

CASES REPORT

G.D., a 42-year-old female was admitted to the Thoracic Surgery Department for diagnosis of a mass at the base of the left lung discovered on a chest radiograph (Fig. 1, 2) performed at a periodical medical examination. Clinical examination showed no

major abnormalities. In differential diagnosis pericardial cyst, mediastinal tumor and neoplastic infiltration were considered. On computed tomography images (Fig. 3, 4) the thoracic mass was identified as the left kidney situated completely above the diaphragm. The kidney size and structure showed no abnormalities. The renal artery supplying the thoracic kidney originated at the normal level. The adrenal gland was situated typically. As renal function parameters were normal, no further procedures were performed.

P.H., a 48-year-old female appeared for consultation at the Pulmonary Department because of a mild respiratory disorder. A chest radiograph showed the presence of an abnormal intrathoracic mass just above the left diaphragm (Fig. 5, 6). Ultrasonography (Fig. 7) and computed tomography (Fig. 8) was performed for the diagnosis. The thoracic kidney showed no structural abnormalities. The adrenal gland was situated typically. As in the previous case, no additional procedures were necessary.

DISCUSSION

Thoracic kidney is an extremely rare renal ectopia, with about 200 cases published [5]. Most cases

Address for correspondence: Prof. Ryszard Maciejewski, Department of Normal Human Anatomy, Medical University, ul. Spokojna 1, Lublin, Poland, tel. +48 81 53 221 18

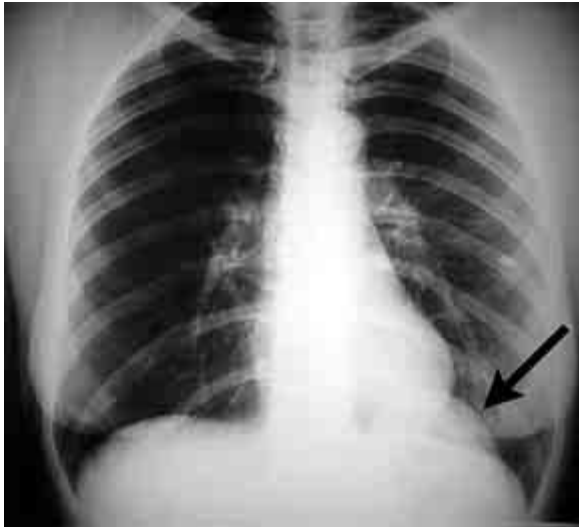


Figure 1. Patient GD, posteroanterior chest radiograph. Round solid mass visible at the left lung base.

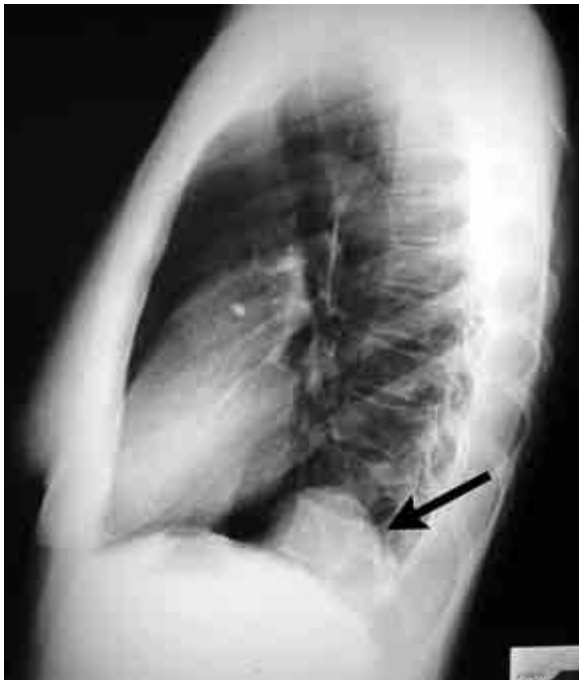

Figure 2. Patient GD, lateral chest radiograph. Round mass visible above the back part of the diaphragm.

are congenital, and diagnosed by chance during chest radiography, as, unlike other renal ectopias, no symptoms are usually reported by the patient, and the kidney function is normal. Acquired thoracic kidney is usually related to diaphragmatic rupture [3] and usually detected by post-traumatic diagnostic procedures, although it might be observed as a delayed trauma complication [9]. The thoracic kid-

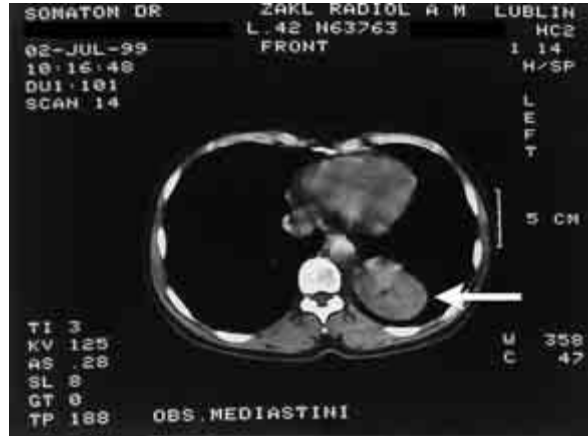

Figure 3. Patient GD, CT scan at Th8 level shows the left kidney situated in the left posterior inferior thorax.

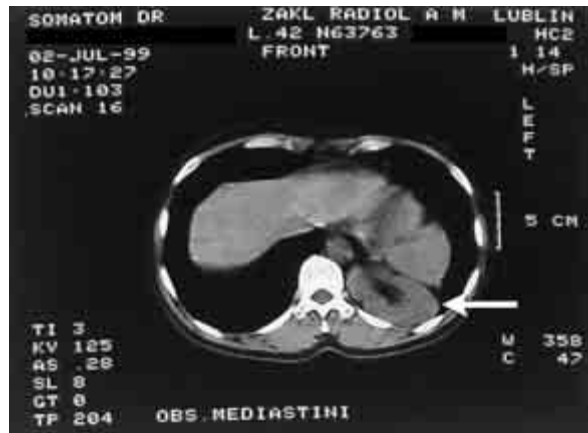

Figure 4. Patient GD, CT scan at Th9 level. Cortex and medulla of the left kidney visible.

ney is always accompanied by an elongated ureter, while the presence of other abnormalities is not constant. In most cases the adrenal gland is located typically, as it develops from different foetal structures [7]. The renal artery might be elongated unless it originates at a higher level than in a normal kidney [11]. The most common congenital anomalies of the kidneys include renal agenesis, bifid renal pelvis and ureter, retrocaval ureter, horseshoe kidney, S-shaped kidney and ectopic kidney. The duplication of the ureter results from division of the metanephric diverticulum. The anomalies of kidney shape are caused by renal pole fusion. Ectopic kidneys result from disturbances of kidney migration [4]. Congenital thoracic kidney may be caused by accelerated cranial migration of the embryonic kidney or delayed diaphragm formation [2]. A few cases of thoracic kidney accompanied by superior ectopic spleen have

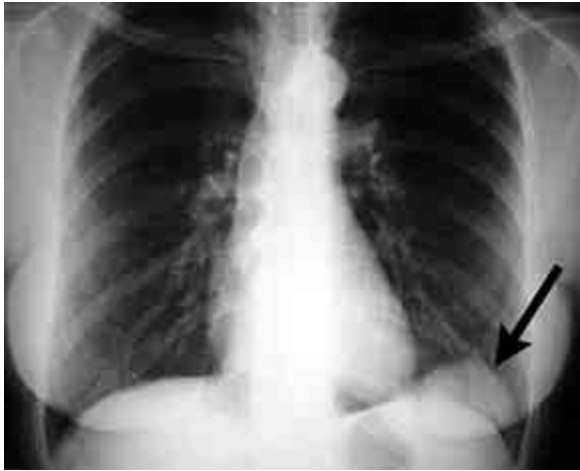


Figure 5. Patient PH, posteroanterior chest radiograph shows solid mass above left hemidiaphragm.

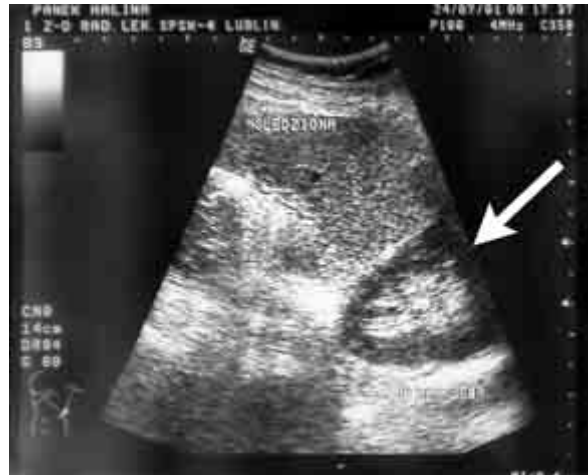

Figure 7. Patient PH, spleen and left kidney ultrasonograph. Left kidney visible in the bottom part of the image, spleen visible above.

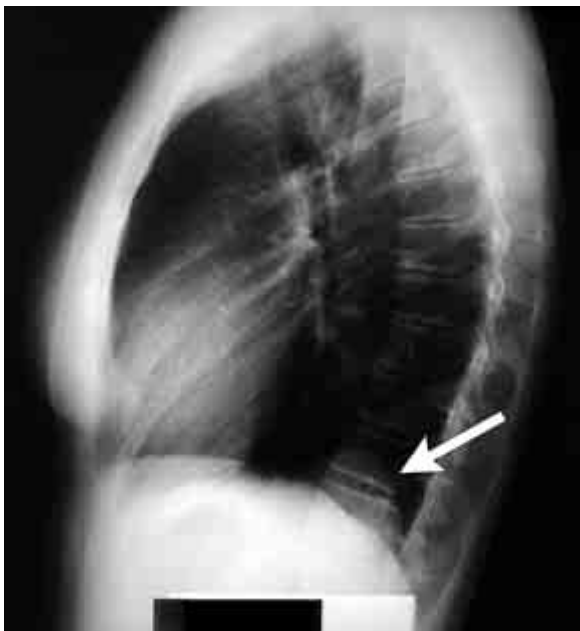

Figure 6. Patient PH, lateral chest radiograph. round solid mass visible above diaphragm, lateral to the spinal column.

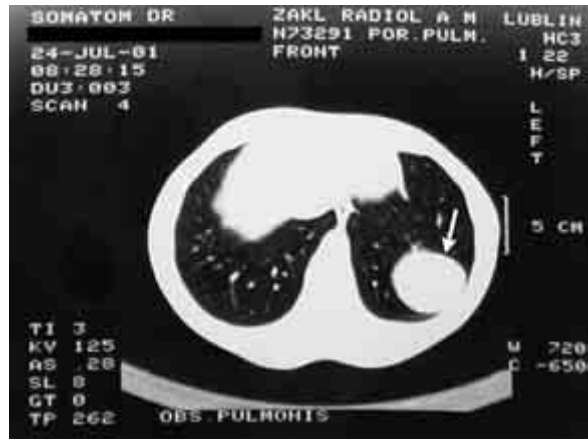

Figure 8. Patient PH, CT pulmonary window scan at Th9 level shows left kidney in the left posterior inferior thorax.

been published [1, 8]. Thoracic kidney, although extremely rare, must always be considered in patients with an intrathoracic mass on a chest radiograph, even if this was not present in a previous examination [6, 10]. Ultrasonography, computed tomography, pyelography and angiography may be helpful in the identification of this anomaly. As an intrathoracic location of a kidney typically does not affect renal function or cause symptoms, it requires no intervention.

REFERENCES

1. Demirpolat G, Guney G, Savas R, Alper H (2003) Thoracic kidney associated with partially intrathoracic spleen: CT and MRI Findings. *Clin Radiol Ex*, 58: 10–12.
2. Fleischner FG, Robins SA, Abrams M (1950) High renal ectopia and congenital diaphragmatic hernia. *Radiology*, 55: 24–26.
3. Karusseit VO (1987) Thoracic kidney. A report of 2 cases. *S Afr Med J* 1987; 727: 505–506.
4. Kemper MJ, Muller-Wiefel DE (2001) Renal function in congenital anomalies of the kidney and urinary tract. *Curr Opin Urol*, 11 (6): 571–575.
5. Lacasta Garcia JD, Sanz Velez JI, Abad Roger J (1999) Ectopia renal toracica. *Actas Urol Esp*, 23(6): 536–538.
6. Liddell RM, Rosenbaum DM, Blumhagen JD (1989) Delayed radiologic appearance of bilateral thoracic

- ectopic kidneys. *AJR Am J Roentgenol*, 152: 120–122.
7. Shimura S, Yoshida K, Kadowaki K et al. (1990) Right thoracic kidney with simple renal cyst: report of a case. *Hinyokika Kyo*, 36: 1321–1324.
 8. Sirikci A, Sarica K, Bayram M (2000) Thoracic kidney associated with superior ectopic spleen. *J Urol*, 163: 1901.
 9. Suarez S, de Jesus Y (1998) Acquired intrathoracic kidney. *P R Health Sci J*, 17(3): 289-291
 10. Usta HY, Rizk F (1984) Delayed appearance of an intra-thoracic kidney. *Ped Radiol*, 14 (6): 449–450.
 11. Yalcinbas YK, Sasmaz H, Canbaz S (2001) Thoracic left kidney: a differential diagnostic dilemma for thoracic surgeons. *Ann Thorac Surg*, 72: 281–283.