

# A case of an anomalous cricothyroid artery

Marios Loukas<sup>1</sup>, Robert G. Louis Jr.<sup>1</sup>, Giovanna Santoni Cruz<sup>1</sup>

<sup>1</sup>Department of Anatomy, American University of the Caribbean, Sint Maarten, Nederland Antilles

[Received 6 April 2004; Accepted 14 May 2004]

*The cricothyroid artery typically originates as a branch of the superior thyroid artery and courses medially to reach the median cricothyroid ligament. Anatomical variations of this pattern are not well documented in the literature. We present a case in which the left cricothyroid artery originated from the left superior thyroid artery near the superior border of the thyroid cartilage and coursed medially to pierce the thyroid lamina. This variation was found during a routine anatomy dissection at the American University of the Caribbean School of Medicine. The possible clinical implications and their relevance to emergency airway management procedures are discussed.*

**Key words:** cricothyroid artery, thyroid lamina, cricothyroid membrane, median cricothyroid ligament, cricothyroidostomy, cricothyroidectomy

## INTRODUCTION

The cricothyroid artery is, at most, briefly mentioned in anatomical literature. Most sources agree that the cricothyroid artery usually arises from the superior thyroid artery and commonly has rich anastomoses with the superior laryngeal artery deep to the lamina of the thyroid cartilage [1, 9, 19]. In approximately 93% of cases, a transverse cricothyroid artery can be found to originate from the superior thyroid artery [5]. In 1996, Dover et al. [5] found that in patients where a transverse cricothyroid artery was present, 93% of these were seen coursing across the upper one third of the cricothyroid membrane, while the remaining 7% cross the lower portion of the membrane. This study also identified collateral anastomoses between the transverse cricothyroid arteries at the level of the cricothyroid membrane.

The elective use of cricothyroidotomy for emergency airway management has been a topic of debate since Chevalier Jackson's [8] paper on high tracheotomies. Jackson condemned the procedure stating that "no end of cases of laryngeal stenosis is the result of these operations.". However, Brantigan

and Grow's [3] study of 655 patients revived the use of this procedure by recommending routine use of cricothyroidotomy in patients whose management requires tracheotomy. Since then numerous studies have been published advocating cricothyroidotomies as a safe and effective option for emergency airway management. The position of the cricothyroid artery should be remembered as it is prone to injury and haemorrhage during surgical procedures in this region. Knowledge of the anatomy of the region is invaluable for the safe execution of emergency cricothyroidotomy. We present a case in which the left transverse cricothyroid artery arises from the left superior thyroid artery and pierces the lamina of the thyroid cartilage.

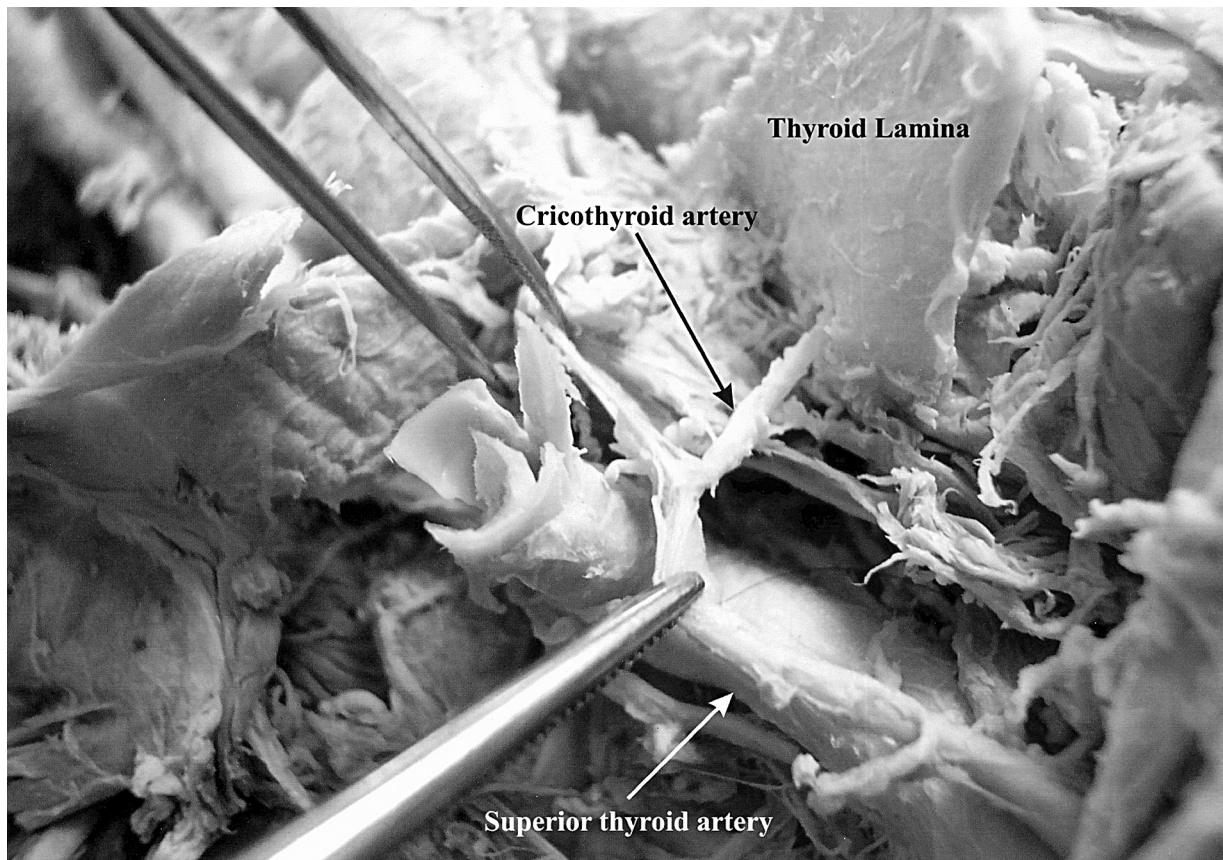
## CASE REPORT

Discovery of the case presented here was made during a routine anatomical dissection of the anterior cervical triangle at the American University of the Caribbean School of Medicine in Sint Maarten, N.A. The specimen was found in a 75-year-old female cadaver who had died of metastatic lung cancer.

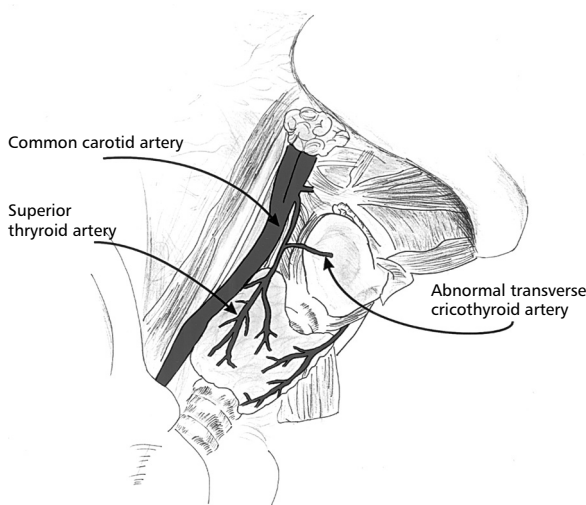
Address for correspondence: Dr. Marios Loukas MD, PhD, Assistant Professor, Department of Anatomy, American University of the Caribbean, Jordan Road, Cupecoy, Lowlands, Sint Maarten, Netherlands Antilles, tel: 0599 545 2298 ext 224, fax: 0599 545 2440, e-mail: edsg2000@yahoo.com

No other vascular anomalies were found within the area in question. The dissection involved reflection of the skin and superficial fascia with a midline incision extending from the mental protuberance to the level of the jugular notch. After isolation of the carotid sheath, the branches of the external carotid were traced distally. The left superior thyroid artery originated as the first anterior branch of the left external carotid artery, slightly superior to the bifurcation of the common carotid artery. After curving inferomedially, the superior thyroid artery immediately gave rise to 3 branches. The infra-hyoid artery was found coursing superomedially along the inferior border of the hyoid bone. The superior laryngeal artery was found coursing anteriorly to join with the internal laryngeal nerve before piercing the thyrohyoid membrane. The artery to the sternocleidomastoid (superficial descending) was found coursing posteroinferiorly across the carotid sheath to supply the anterior border of the sternocleidomastoid muscle. After giving rise to these branches, the superior thyroid artery continued its descent along the lateral

border of the left thyroid lamina. The artery presented was found at approximately one third of the distance between the superior and inferior borders of the thyroid cartilage (Fig. 1, 2). No other branches were found before the terminating branches localised to the superior pole of the thyroid gland. The local musculature was then carefully reflected to reveal the course of the artery. After reflection of the sternohyoid, omohyoid and thyrohyoid muscles, it was found that the artery continued medially for approximately 1 cm, where it then pierced the thyroid cartilage. An orifice of approximately 5 mm was found in the thyroid lamina, which transmitted this artery to the internal surface. A vertical incision was made down the midline of the thyroid cartilage to allow inspection of the distribution of the artery from the interior surface of the thyroid lamina. The artery was found to give several small branches which continued on to supply the underlying tissue. Similar inspection of the contralateral superior thyroid artery revealed that the anomaly was unilateral and typical branching patterns were observed on the right side of the specimen.



**Figure 1.** The cricothyroid artery is penetrating the thyroid lamina instead of the thyroid membrane.



**Figure 2.** Schematic representation of the neck area with the anomalous cricothyroid artery.

## DISCUSSION

To the best of our knowledge, this is the first case of an artery which pierces the thyroid cartilage. On the basis of accepted standards of nomenclature, an artery is named according to its termination. Following these guidelines, we decided to name this a transverse cricothyroid artery, despite its anomalous origin and course.

The embryological development of the head and neck is marked by the emergence of 6 paired pharyngeal arches, which appear as condensations of mesenchyme during the Week 5 of development. The laryngeal cartilage, which includes the thyroid, cricoid, arytenoid, corniculate and cuneiform cartilages, arises from a fusion of the cartilaginous components of the 4<sup>th</sup> and 6<sup>th</sup> pharyngeal arches [12]. Blood vessel formation begins during Week 3 in the embryo. Early vessels form from the coalescence of isolated cavities of condensed mesenchyme, which are lined internally by angioblasts. These cells are eventually differentiated into the endothelial cells which line the vasculature [14]. The pharyngeal arch arteries are derivatives of the paired ventral aorta which arise as distal extensions of the *truncus arteriosus* [6]. The precise timing and co-ordination of these events is still a topic of much investigation, making the origin of this variation difficult to discern. It is possible that in this patient the arterial development progressed prior to the fusion of the 4<sup>th</sup> and 6<sup>th</sup> pharyngeal arches, leaving an ostium in the thyroid lamina, through which the transverse cricothyroid artery could travel. Another possibility is that this ar-

tery arose as a nutrient branch to the thyroid cartilage during development and subsequently became enlarged and replaced the typical cricothyroid artery.

Since the discovery of this variation was made post mortem, it is unknown whether the existence of this branching pattern had any clinical consequences. However, the existence of this branching pattern, in addition to its aberrant course, uncovers several possible surgical implications. The use of cricothyroidotomy for emergency airway management has been the topic of much investigation and controversy. The major controversy has generally focused on the development of subglottic stenosis [2, 7, 11, 16–18]. Other complications include local haemorrhage caused by injury to the transverse cricothyroid artery. Insertion of the tracheotomy tube before ligation of the damaged vessels could lead to aspiration of blood by the patient and resulting suffocation [15]. Despite these possible complications, there are many studies which advocate cricothyroidotomy as a viable option for establishing an airway in patients for whom oral or nasotracheal intubation is contraindicated. Indications for cricothyroidotomy include facial, neck or potential cervical spine injury combined with airway compromise [10]. In addition, cricothyroidotomy can be performed more quickly and easily than tracheotomy because the cricothyroid membrane is located immediately beneath the skin and its landmarks are more easily localised [13]. Methods are described using both horizontal and vertical incision techniques [4]. Advantages and disadvantages exist for both methods. A vertical incision will facilitate subsequent extension of the incision caudally for classic tracheotomy. The disadvantages of this technique include an increased risk of damage to the cricoid cartilage as well as haemorrhage from the cricothyroid artery [4]. A horizontal incision along the lower portion of the cricothyroid membrane decreases the risk of vascular injury but may cause the cannula to tilt and scrape against the tracheal wall. Execution of this procedure using either technique requires knowledge of local anatomy in order to minimise the chance of complications.

During the course of routine dissections in the medical anatomy laboratory, students are not typically instructed to observe or document anatomical variations. The purpose of these dissections is to provide the students with detailed instruction of typical anatomical structures along with any common variations. It has not escaped our attention that this

variation could have been overlooked due to the in-structive rather than investigative nature of most classroom dissections. An anatomical study involving many cadavers which systematically documents the origin and course of the cricothyroid artery would be needed in order to determine the prevalence of this anomaly. Such a study would serve to clarify the patterns of anatomical variation in the superior thyroid and cricothyroid arteries and provide a more accurate base of knowledge for the guidelines for emergency airway management procedures.

### REFERENCES

1. Bergmann RA, Thompson SA, Afifi AK, Saadeh FA (1988) Compendium of human anatomic variation. Urban and Schwarzenberg, Baltimore, pp. 353–367.
2. Boyd AD, Romita MC, Conlan AA, Fink SD, Spencer FC (1979) A clinical evaluation of cricothyroidotomy. *Surg Gynecol Obstet*, 149: 365–368.
3. Brantigan CO, Grow Sr JB (1978) Cricothyroidotomy: Elective use in respiratory problems requiring tracheotomy. *J Thor Card Surg*, 71: 72–80.
4. Cole RR, Aguilar EA (1988) Cricothyroidotomy versus tracheotomy: an otolaryngologists perspective. *Laryngoscope*, 98: 131–135.
5. Dover K, Howdieshell, TR, Colborn GL (1996) The dimensions and vascular anatomy of the cricothyroid membrane: relevance to emergent surgical airway access. *Clin Anat*, 9: 291–295.
6. Drews U (1995) Color atlas of embryology. Thieme Medical. New York, pp. 174–175.
7. Esses BA, Jafek BW (1987) Cricothyroidotomy: a decade of experience in Denver. *Ann Otol Rhinol Laryngol*, 96: 519–524.
8. Jackson C (1921) High tracheostomy and other errors the chief causes of chronic laryngeal stenosis. *Surg Gynecol Obstet*, 32: 392–398.
9. Lippert H, Pabst R (1985) Arterial variations in man: classification and frequency. JF Bergman. Munich, pp. 83–84.
10. McGill J, Clinton JE, Ruiz E, (1982) Cricothyroidotomy in the Emergency Department. *Ann Emerg Med*, 11: 361–364.
11. O'Connor JV, Reddy K, Ergin MA, Griep RB (1985) Cricothyroidotomy for prolonged ventilatory support after cardiac operations. *Ann Thorac Surg*, 39: 353–354.
12. Sadler TW (1995) Langman's Medical Embryology. Williams and Wilkins. Chapel Hill N.C., p. 317.
13. Safar P, Penninckx J (1967) Cricothyroid membrane puncture with special cannula. *Anesthesiology*, 28: 943–948.
14. Sweeney LJ (1998) Basic concepts in embryology. McGraw-Hill. Pennsylvania, pp. 270–271.
15. Unger KM, Moser KM (1973) Fatal complication of transtracheal aspiration. *Arch Intern Med*, 132: 437–439.
16. van Hasselt EJ, Bruining HA, Hoeve LJ (1985) Elective cricothyroidotomy. *Intensive Care Med*, 11: 207–209.
17. Walls RM (1988) Cricothyroidotomy. *Emer Med Clin of North Am*, 6: 725–736.
18. Weymuller EA (1982) Cricothyroidotomy controversy. *Ann Otol Rhinol Laryngol*, 9: 670.
19. Williams PL, Warrick M, Dyson M, Bannister LH (eds.). (1989) Gray's anatomy. Churchill Livingstone. New York, pp. 1253–1254.