

A case of an accessory testicular artery

Marios Loukas^{1, 2}, Doug Stewart¹

¹Department of Anatomy, American University of the Caribbean, Sint Maarten, Netherlands Antilles

²Harvard Medical School, Boston, MA, USA

[Received 6 April 2004; Accepted 30 April 2004]

Dissection of an adult male cadaver revealed the presence of an accessory left testicular artery in addition to the normal right and left testicular arteries. In this case the accessory left testicular artery originated from the ventrolateral wall of the descending aorta. The origin was located between the superior mesenteric artery and the left renal vein. The accessory artery continued to course from the aorta laterally toward the superior ventral portion of the left kidney and then passed ventrally to the kidney on its course inferiorly to the pelvic region. Communication was observed between the accessory left testicular artery and the left renal artery. This variation of gonadal vasculature is of interest from the point of view of its embryogenesis, and possible clinical significance.

Key words: left testicular artery, left accessory testicular artery, testicular arterial vasculature, renal artery

INTRODUCTION

The testicular artery usually arises from the anterolateral aspect of the abdominal aorta at the level of the second lumbar vertebra, 2.5 to 5 cm caudal to the renal artery [4]. It may originate from the renal artery or as a branch from a suprarenal or lumbar artery [2]. The testicular artery courses obliquely downwards and laterally behind the peritoneum into the pelvic cavity. During its descent into the pelvic cavity, it does not normally give off any branches [7].

According to Williams et al. [11], the lateral splanchnic arteries, which are branches of the dorsal aorta at the embryonic stage, persist bilaterally as one testicular and 3 suprarenal arteries. These findings are obviously indicative of different developmental patterns of origin, course and branching. Certain vascular and developmental anomalies of the kidneys can be associated with variations in the course of the gonadal arteries [6, 9]. These anomalies can be explained by the embryological development of both of these organs from the intermediate

mesoderm of the mesonephric crest and the vascularisation of both the kidneys and the gonads from the lateral mesonephric branches of the dorsal aorta [1, 3, 5].

There have been many reports of accessory testicular arteries [10], bilateral accessory renal and testicular arteries [3], doubling of renal and testicular arteries [2] and variations in the origin of testicular vasculature [10]. However, we present here a case of an accessory renal artery that, to the best of our knowledge, has not previously been reported in the literature. To the clinician any unusual course or location of the testicular artery may be of importance in pursuing a course of specific surgical procedures or in diagnostic pathology associated with testicular anatomy.

CASE REPORT

During routine dissection of the abdominal region of a male adult Caucasian cadaver during the Human Body Course at Harvard Medical School, an

Address for correspondence: Dr. Marios Loukas MD, PhD, Assistant Professor, Department of Anatomy, American University of the Caribbean, Jordan Road, Cupecoy, Lowlands, Sint Maarten, Netherlands Antilles, tel: 0599 545 2298 ext. 224, fax: 0599 545 2440, e-mail: edsg2000@yahoo.com

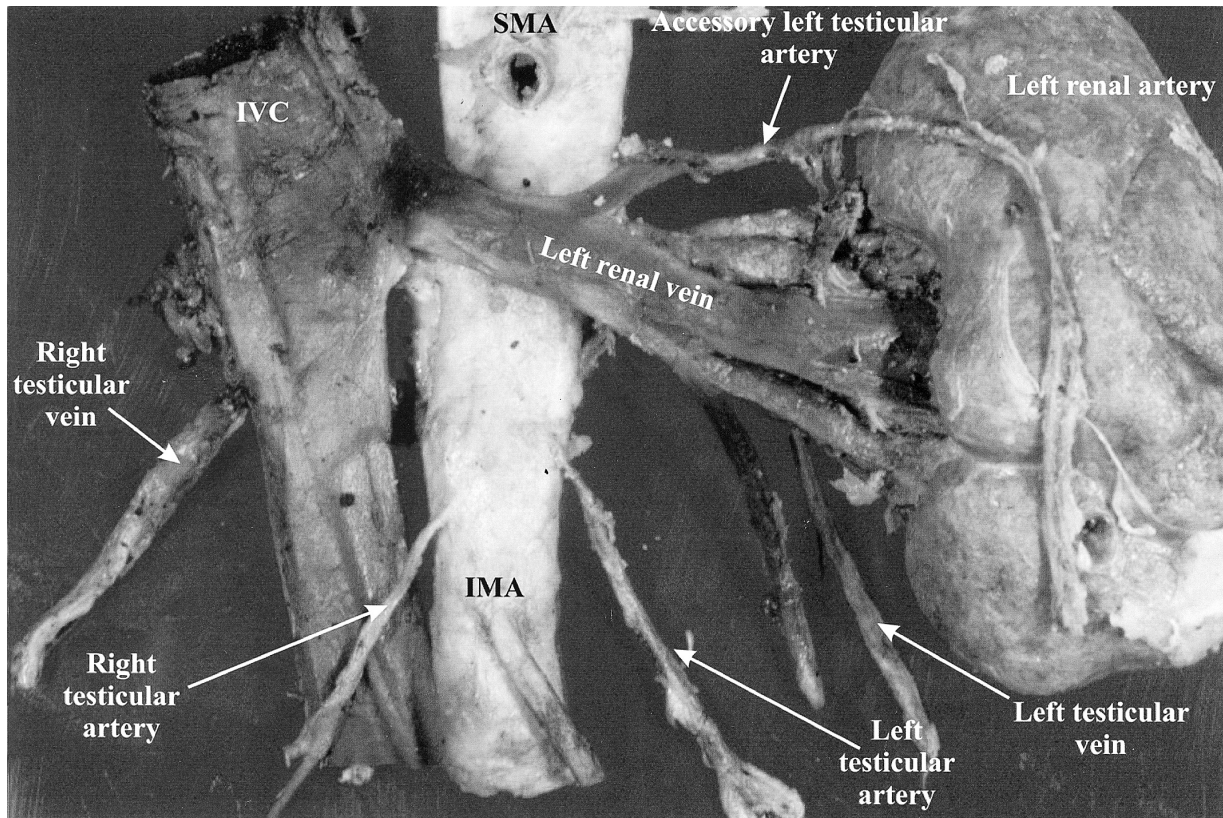


Figure 1. An accessory left testicular artery is revealed arising at the inferior left edge below the superior mesenteric artery and above the left renal vein. SMA — superior mesenteric artery, IMA — inferior mesenteric artery, IVC — inferior vena cava.

accessory left testicular artery was observed (Fig. 1). In this case the accessory left testicular artery originated from the ventrolateral wall of the descending aorta. The origin was located approximately 2 cm inferior to the superior mesenteric artery and 1 cm superior to the left renal vein. The accessory artery continued laterally from the aorta toward the superior ventral portion of the left kidney and then passed ventral to the kidney inferiorly toward the pelvic region. Communication was observed between the accessory left testicular artery and the left renal artery. In all other respects regional vasculature in the cadaver appeared anatomically normal. The left renal vein passed anterior to the descending aorta to reach the left anatomically typical kidney. The right and left testicular arteries originated from the descending aorta, superior to the inferior mesenteric artery, with the origin of the left testicular artery positioned slightly cranial to that of the right testicular artery.

DISCUSSION

Cases have been reported previously of accessory testicular arteries, bilateral accessory renal and

testicular arteries, doubling of renal and testicular arteries and variations in the origin of testicular vasculature. This is the first documented case of a singular accessory left testicular artery originating from the descending aorta between the superior mesenteric artery and the left renal artery and vein. Specific variations, including a high origin of the gonadal arteries, have been reported in several cases [2, 4, 7, 8]. Shinohara et al. [10] reported the most highly positioned testicular artery ever documented. In a Japanese male the left testicular artery originated from the aorta 1 cm cranial to the origin of the left inferior phrenic artery. The high origin of the accessory artery in the present case is unique in that it occurred along with normal testicular arteries and communicated with the ipsilateral renal artery.

The structures that arise from the region encompassing the mesonephros, reproductive gland and the metanephros and suprarenal glands are supplied by lateral mesonephric arteries arising from the dorsal aorta [1]. The 9 pairs of the lateral mesonephric arteries are divided into 3 groups as follows: the cranial group, consisting of the 1st and 2nd arteries located cranial to the coeliac trunk that run dorsal to

the suprarenal body; the middle group, consisting of 3rd–5th arteries passing through the suprarenal body, and the caudal group consisting of the 6th–9th arteries passing over the ventral side of the suprarenal body and forming the rete arteriosus urogenitale [5]. Felix reported that although one of the 9 arteries develops into the testicular artery, it usually stems from the rete arteriosus urogenitale [5]. He also stated that if the testicular artery is derived from the cranial group, it will pass dorsal to the renal artery, which is derived from the middle group [5]. In the present case, the accessory testicular artery originated dorsal to the renal artery. It is therefore believed to have been derived from the cranial group.

Ozan et al. [8] reported two cases of gonadal arteries, together with accessory renal arteries, that originated from the abdominal aorta at a higher level. It is notable with reference to our case that the left testicular artery branched off from the abdominal aorta 5 mm inferior to the origin of the superior mesenteric artery and ran laterally anterior to the renal artery and vein. The continuation of the artery was normal. Our case was similar regarding the origin of the left testicular artery. However, it revealed not only a high origin of the artery, but also an unusual course anterior to the kidney, in addition to the fact that it was an accessory vessel.

In a study carried out by Onderoglu et al. [7] on a 58-year-old male cadaver, the right testicular artery originated from the anterior aspect of the abdominal aorta at nearly the same level as the renal artery. In the cadaver in our present case there was again similar variation in the origin of the testicular artery but significant differences involving the accessory vasculature.

This variation in our case is important, not only from a developmental standpoint, but also from a physiological perspective. Accessory arterial vasculature and an unusual origin and path of the testicular artery is worth reporting in efforts to educate clinicians involved in abdominal and urogenital surgical procedures.

REFERENCES

1. Arey LB (1971) *Developmental Anatomy*, 6th Ed. WB Saunders Co, Philadelphia, pp. 371–374.
2. Bergman RA, Cassell MD, Sahinoglu K, Heidger PM (1992) Human doubled renal and testicular arteries. *Ann Anat*, 174: 313–315.
3. Bremer JL (1915) The origin of the renal artery in mammals and its anomalies. *Am J Anat*, 18: 179–200.
4. Brohi RA, Sargon MF, Yener N (2001) High origin and unusual suprarenal branch of a testicular artery. *Surg Radiol Anat*, 23: 207–208.
5. Felix W (1912) Mesonephric arteries (aa. mesonephricae). In: Keibel F, Mall FP (eds.). *Manual of human embryology*. Vol. 2. J.B. Lippincott, Philadelphia, London, pp. 820–825.
6. Merklin RJ, Michels NA (1958) The variant renal and suprarenal blood supply with data on the inferior phrenic, ureteral and gonadal arteries. *J Int Coll Surg*, 29: 41–76.
7. Onderoglu S, Yuksel M, Arik Z (1993) Unusual branching and course of the testicular artery. *Anat Anz*, 175: 541–544.
8. Ozan H, Gumusalan Y, Onderoglu S, Simsek C (1995) High origin of gonadal arteries associated with other variations. *Anat Anz*, 177: 156–160.
9. Rahman HA, Dong K, Yamadori T (1993) Unique course of the ovarian artery associated with other variations. *J Anat*, 182: 287–290.
10. Shinhara H, Nakatani T, Yoshifumi F, Morisawa S, Matsuda T (1990) Case with a high-positioned origin of the testicular artery. *Anat Rec*, 226: 264–266.
11. Williams PL, Warwick R, Dyson M, Bannister LH (1989) *Gray's anatomy*. 37th Ed. Churchill Livingstone, Edinburgh, pp. 773–776.