

Arterial, neural and muscular variations in the upper limb

Nigar Coskun, Levent Sarikcioglu, Baris Ozgur Donmez, Muzaffer Sindel

Department of Anatomy, Faculty of Medicine, Akdeniz University, Antalya, Turkey

[Received 13 May 2005; Accepted 2 September 2005]

During our routine dissection studies we observed arterial, neural and muscular variations in the upper limbs of an adult male cadaver. In this case we observed the superficial brachial artery origination from the third part of the axillary artery, communications between the musculocutaneous and median nerves, variant formation of the brachial plexus, origination of the profunda brachii artery from the posterior circumflex humeral artery and supernumerary tendons of the abductor pollicis longus muscle. We think that such variations should be kept in mind during surgical and diagnostic procedures.

Key words: superficial brachial artery, axillary artery, musculocutaneous nerve, communication, median nerve, profunda brachii artery

INTRODUCTION

Variations of the arteries, nerves and muscles of the upper limb have both clinical and surgical importance. The superficial brachial artery origination from the third part of the axillary artery, communications between the musculocutaneous and median nerves, variant formation of the brachial plexus, origination of the profunda brachii artery from the posterior circumflex humeral artery and supernumerary tendons of the abductor pollicis longus muscle have been well documented [3]. We describe here the co-existence of these variations in the upper limbs of a male cadaver.

CASE REPORT

During our routine dissection studies on a 50-year-old male cadaver we encountered variations in both upper limbs. These variations were as follows.

Left side observations

The axillary artery split into two branches; the first was the superficial brachial artery and the second was

a common trunk for the subscapular, brachial, posterior circumflex humeral and anterior circumflex humeral arteries (Figs. 1-3).

After giving nutrient branches to the muscles in the arm, the superficial brachial artery divided into the radial and ulnar arteries. The brachial artery continued as a common trunk for the inferior and superior ulnar collateral arteries (Figs. 1-3). The terminal parts of the inferior and superior ulnar collateral arteries were anastomosed just above the elbow joint. The profunda brachii artery originated from the posterior circumflex humeral artery and lay posterior to the teres major muscle concomitant to the radial nerve.

Two communicating branches were also observed between the musculocutaneous and median nerves. The first communicating branch was located before the splitting of the coracobrachialis muscle and the second after the splitting of the coracobrachialis muscle (Figs. 1, 2).

The abductor pollicis longus muscle had five tendon slips and was located in the first compartment (Fig. 4).

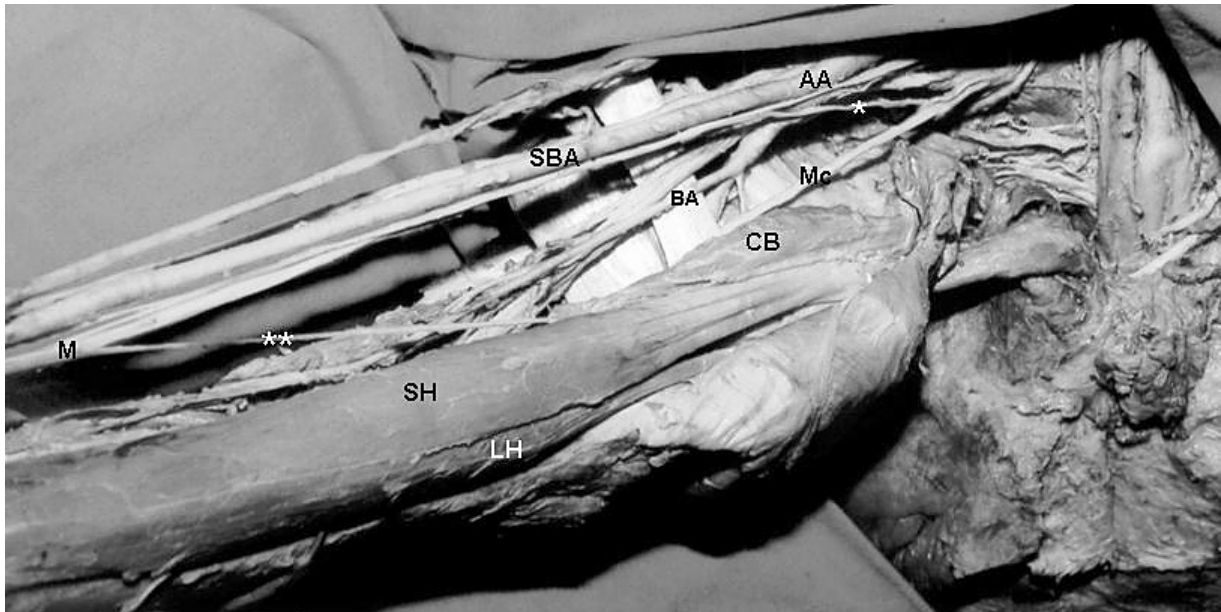


Figure 1. Photograph of the left upper limb showing the origination of the superficial brachial and brachial artery, and communicating branches between the median and musculocutaneous nerves. AA — axillary artery, BA — brachial artery, CB — coracobrachialis muscle, LH — long head of the biceps brachii muscle; M — median nerve, Mc — musculocutaneous nerve, SBA — superficial brachial artery, SH — short head of the biceps brachii muscle, * — first communicating branch, ** — second communicating branch.

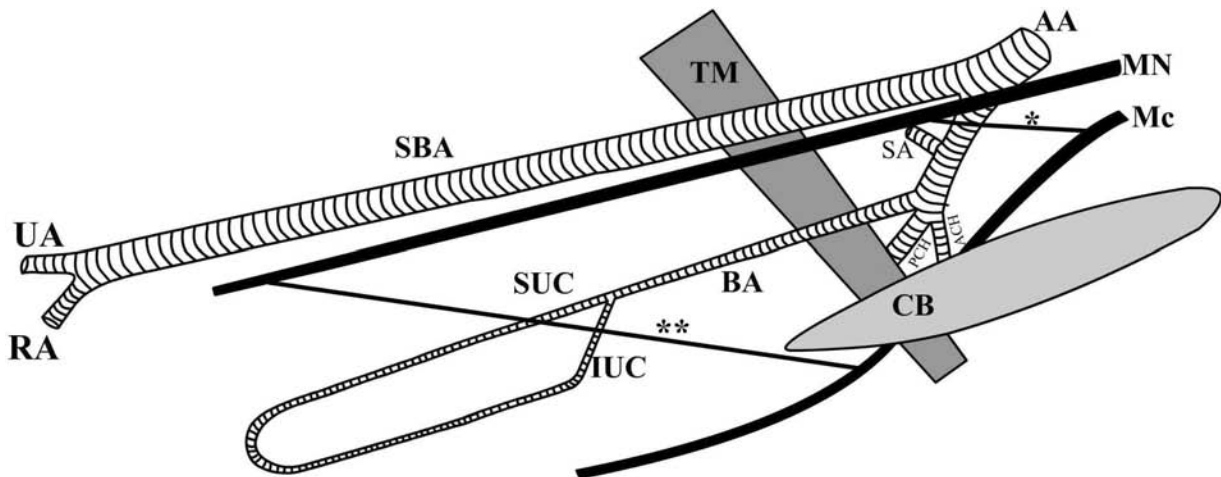


Figure 2. Schematic drawing of the variations illustrated in Figure 1. AA — axillary artery, ACH — posterior circumflex humeral artery, BA — brachial artery, CB — coracobrachialis muscle, IUC — inferior ulnar collateral artery, LH — long head of the biceps brachii muscle, M — median nerve, Mc — musculocutaneous nerve, PCH — posterior circumflex humeral artery, RA — radial artery, SA — subscapular artery, SBA — superficial brachial artery, SUC — superior ulnar collateral artery, SH — short head of the biceps brachii muscle, UA — ulnar artery, * — first communicating branch, ** — second communicating branch.

Right side observations

The musculocutaneous nerve originated from the lateral cord of the brachial plexus and split the coracobrachialis muscle. A communicating branch was then observed to originate from the musculocutaneous nerve and joined the median nerve at the level of the radial tuberosity (Fig. 5). Additionally, the lateral cord of the brachial plexus was not formed.

The anterior division of the middle trunk split into two branches, one of which joined the lateral root of the median nerve and the other the medial root of the median nerve (Fig. 6).

The abductor pollicis longus muscle had three tendon slips and was located in the first compartment, together with the extensor pollicis brevis muscle.

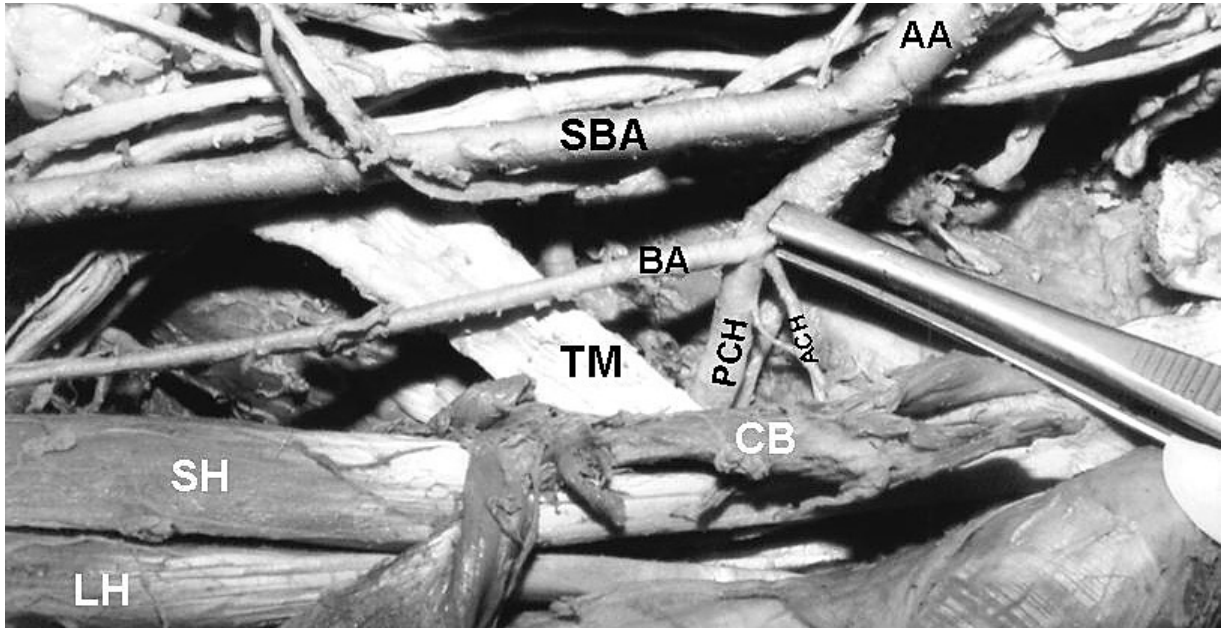


Figure 3. Photograph of the left upper limb showing the axillary artery distribution. AA — axillary artery, BA — brachial artery, CB — coracobrachialis muscle, LH — long head of the biceps brachii muscle, PCH — posterior circumflex humeral artery, ACH — anterior circumflex humeral artery, SBA — superficial brachial artery, SH — short head of the biceps brachii muscle, TM — teres major muscle.

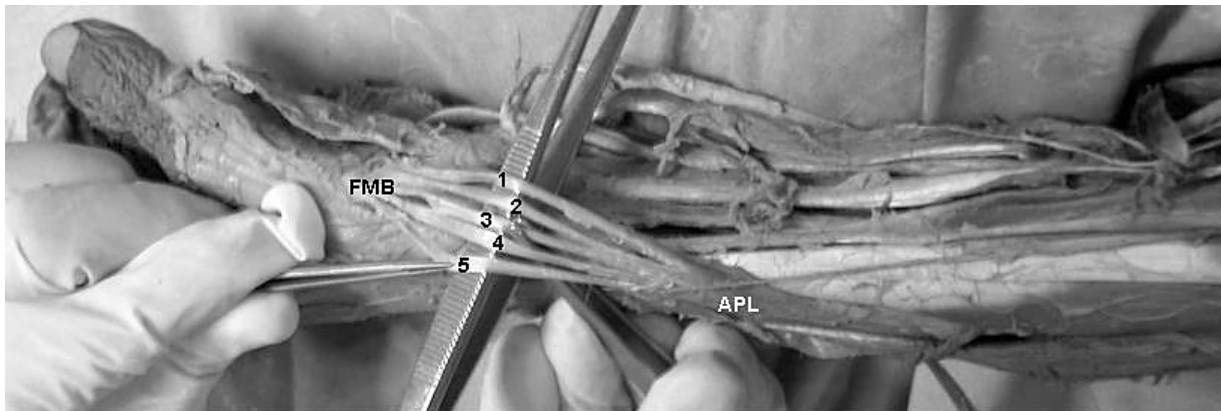


Figure 4. Photograph of the left side of the case showing the supernumerary tendons of the abductor pollicis longus muscle. APL — abductor pollicis muscle, FMB — base of the first metacarpal bone, 1, 2, 3, 4, 5 — tendon slips of the abductor pollicis longus muscle.

As is shown on the left side, the profunda brachii artery was a continuation of the posterior circumflex humeral artery in a downward-lying position concomitant to the radial nerve (Fig. 7).

DISCUSSION

Variations in the origin and course of the principal arteries of the upper limb have been well documented [1, 3, 14, 18]. The incidences of a superficial brachial artery originating from the axillary artery was reported as 3% (3/100 limbs) by Müller [17],

0.24% (1/410 limbs) by Adachi [1], 0.1% (1/960 limbs) by Miller [16], 0.1% (1/750 limbs) by McCormack et al. [14] and 4.5% (9/200 limbs) by Fuss et al. [9].

It has been suggested that variations in the arterial pattern of the upper limb are caused by deviations from the normal developmental process. According to Jurjus et al. [11], anomalous vessels may occur owing to the following: 1 — the choice of unusual paths in the primitive vascular plexuses; 2 — the persistence of vessels normally obliterated; 3 — the disappearance of vessels normally retained;

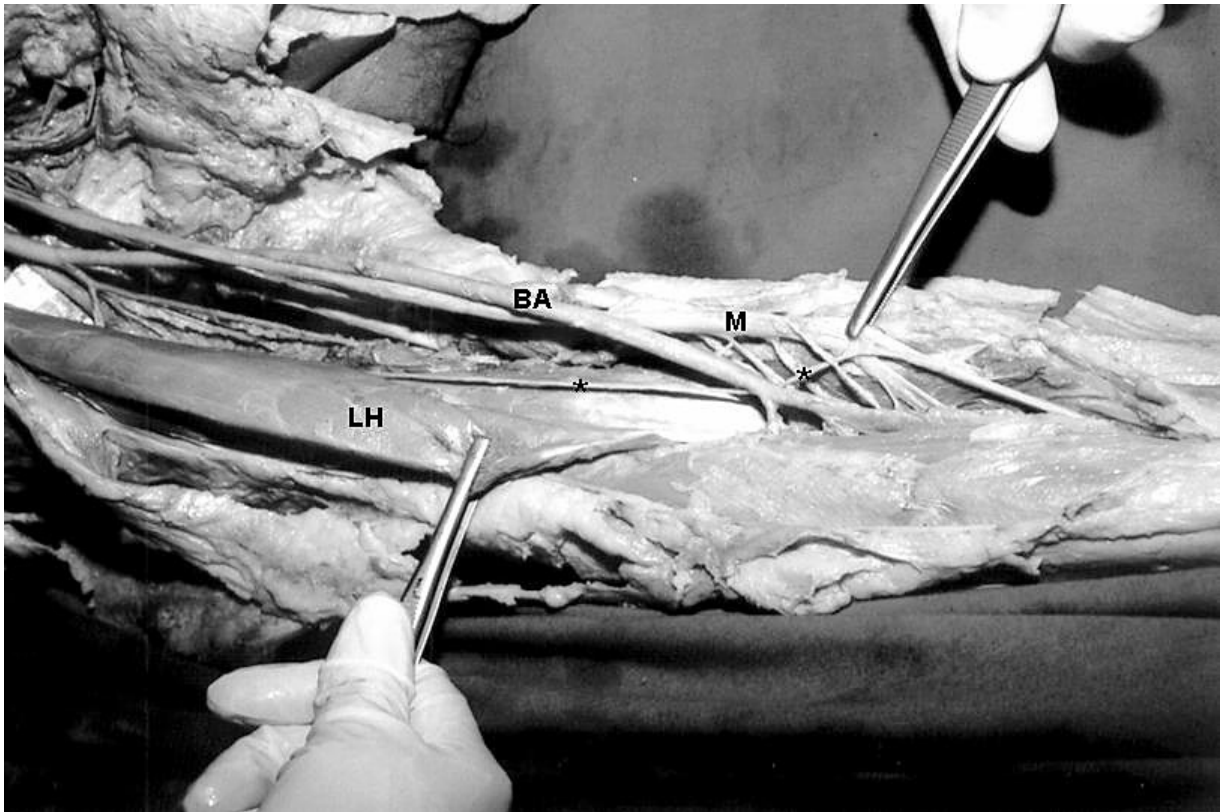


Figure 5. Photograph of the right upper limb of the case showing the communication between the musculocutaneous and median nerves at the level of radial tuberosity. BA — brachial artery, LH — long head of the biceps brachii muscle, M — median nerve, * — communicating branch.

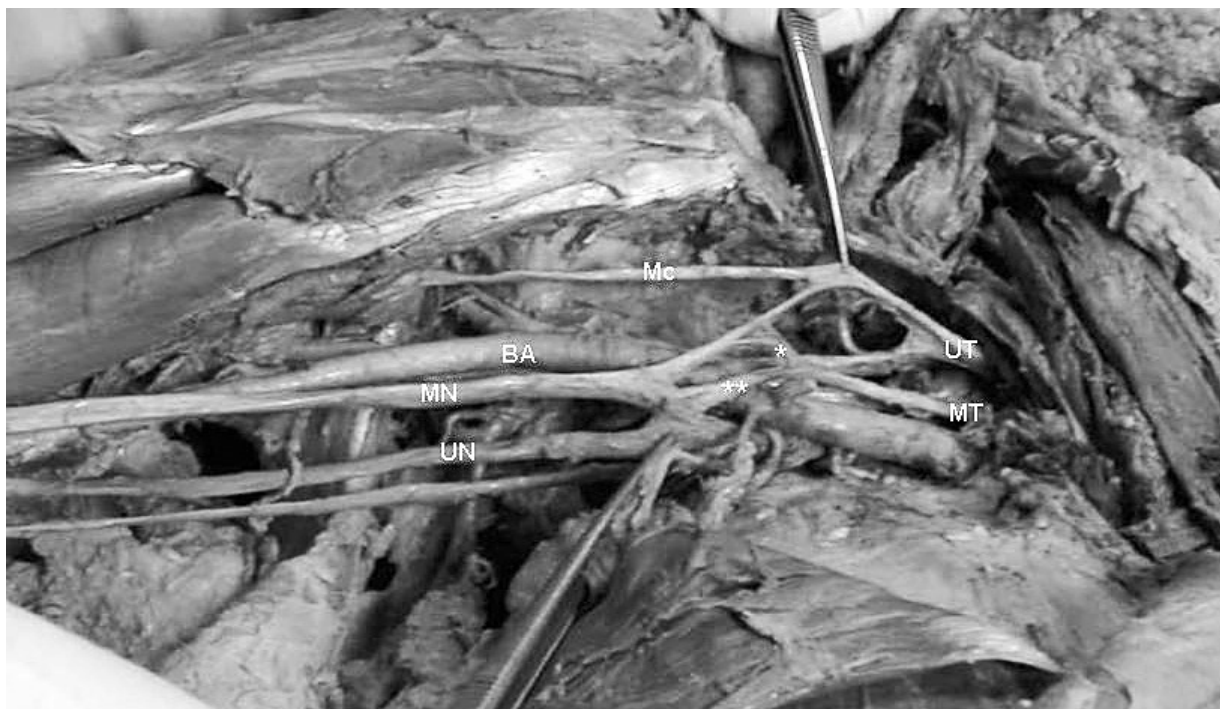

Figure 6. Photograph of the right upper limb of the case showing variant formation of the brachial plexus. BA — brachial artery, Mc — musculocutaneous nerve, MN — median nerve, UN — ulnar nerve, UT — upper trunk, * — a branch coming from the anterior division of the middle trunk to join the medial root of the median nerve, ** — a branch coming from the anterior division of the middle trunk to join the lateral root of the median nerve.

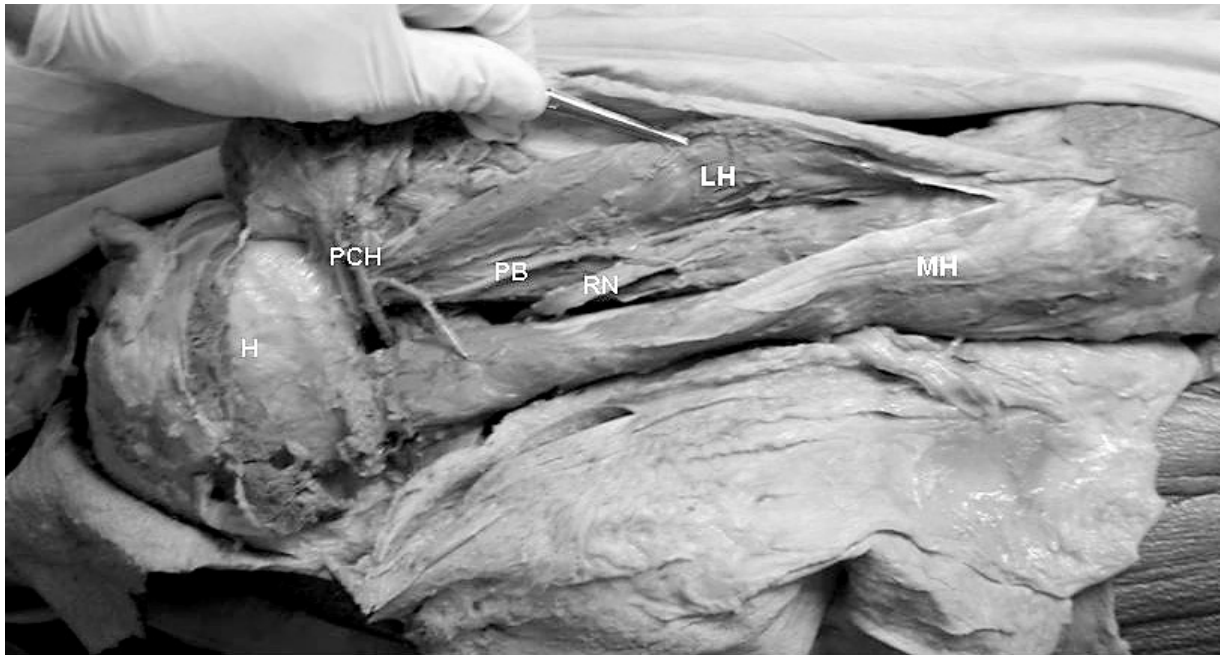


Figure 7. Photograph of the right upper limb of the case showing the profunda brachii artery origination from the posterior circumflex humeral artery. LH — long head of the triceps brachii muscle, H — head of the humerus, MH — medial head of the triceps brachii muscle, PB — profunda brachii artery, PCH — posterior circumflex humeral artery, RN — radial nerve.

4 — incomplete development; 5 — fusion and absorption of parts usually distinct. In the present case the superficial brachial artery was larger than the brachial artery. This may be attributed to the persistence of the vessels normally obliterated, as described by Jurjus et al. [11]. Persistent anastomotic vessels between the main arteries of the upper limb have been reported in the literature [6, 10, 18, 20]. In the present case no anastomotic vessel was observed in the cubital region in either upper limb.

It has been suggested that the arterial variation of the upper limb is associated with the presence of the surrounding neural variations [2, 19–21]. The present case corroborates these reports. Although many of these variations cause no disturbance in the function of the upper limb, they may be of considerable interest for surgeons and radiologists.

The origin of the profunda brachii artery is quite variable. It may arise from the third part of the axillary artery or in common with one or more branches of that vessel, the subscapular for example, arise as a common trunk with the superior ulnar collateral, anterior and/or posterior circumflex humeral arteries [3]. In the present case the profunda brachii artery originated bilaterally from the posterior circumflex humeral artery (Type V as classified by Charles et al. [7]).

The supernumerary tendons of the abductor pollicis longus muscle (APL) and the origin of the profunda

brachii artery have been well documented. In the left side of the present case division of the APL tendon was five slips, as previously described [5, 22, 23], and all tendon slips attached to the dorsal aspect of the base of the first metacarpal bone.

The literature consists of numerous communication types between the median and musculocutaneous nerves [3, 4, 8, 13, 20, 21, 25, 26]. Communications between the musculocutaneous and median nerves have been classified by many authors [8, 12, 26]. Comparative anatomical studies have shown that in amphibians and birds there is only one nerve trunk in the anterior aspect of the arm [15]. Similarly, in New World monkeys there is a partial fusion of both nerves and distally the musculocutaneous nerve separates from the median nerve. Embryological studies have revealed that this fusion may be explained as a failure in the differentiation of the brachial plexus, as in the early developmental stages all the spinal nerves unite to form a single neural plate [24]. This failure in development has been associated with variations in the anatomy of local muscle groups [13]. In our case there was no local muscle variation. Comparative anatomical studies have provided evidence for the existence of such connections in monkeys and in some apes; the connections may represent the primitive median nerve supply of the anterior

arm muscles [15]. On the right side of our case the median and musculocutaneous nerves communicated at the level of the radial tuberosity. We think that this communication level is an interesting finding and worth of note for the anatomist as well as for the surgeon.

Variation in the branching pattern between the median and musculocutaneous nerves might be of significance in diagnostic clinical neurophysiology. Knowledge of such variations is also important to those who use anterior surgical approaches to the shoulder, and in understanding dysfunction of the median and musculocutaneous nerves. Additionally, we think that the co-existence of such arterial, neural and muscular variations should not be overlooked in surgical and diagnostic procedures.

ACKNOWLEDGEMENTS

We thank Mr. Necati Sagiroglu, Mr. Huseyin Gezer and Mr. Hasan Savcili for their technical assistance.

REFERENCES

- Adachi B (1928) Das arteriensystem der Japaner. Maruzen Co, Kyoto, pp. 326–374.
- Anagnostopoulou S, Venieratos D (1999) An unusual branching pattern of the superficial brachial artery accompanied by an ulnar nerve with two roots. *J Anat*, 195: 471–476.
- Bergman R, Thompson SA, Afifi AK (1985) Catalog of human anatomical variation. Urban Schwarzenberg, Baltimore, pp. 108–114.
- Buch-Hansen K (1955) Über varietäten des nervus medianus und des nervus musculocutaneus und deren beziehungen. *Ann Anat*, 102: 187–203.
- Bunnell S (1948) *Surgery of the hand*. J.B. Lippincott, Philadelphia, pp. 455–457 (cited by Melling et al. 1998).
- Cavdar S, Zeybek A, Bayramicli M (2000) Rare variation of the axillary artery. *Clin Anat*, 13: 66–68.
- Charles CM, Penn L, Holden HF, Miller RA, Alvis EB (1931) The origin of the deep brachial artery in American white and American negro males. *Anat Rec*, 50: 299–302.
- Choi D, Rodriguez-Niedenfuhr M, Vazquez T, Parkin I, Sanudo JR (2002) Patterns of connections between the musculocutaneous and median nerves in the axilla and arm. *Clin Anat*, 15: 11–17.
- Fuss FK, Matula CW, Tschabitscher M (1985) Die arteria brachialis superficialis. *Anat Anz*, 160: 285–294.
- Gonzalez-Compta X (1991) Origin of the radial artery from the axillary artery and associated hand vascular anomalies. *J Hand Surg Am*, 16: 293–296.
- Jurjus AR, Correa-De-Aruaujo R, Bohn RC (1999) Bilateral double axillary artery: embryological basis and clinical implications. *Clin Anat*, 12: 135–140.
- Kosugi K, Morita T, Koda M, Yamashita H (1986) Branching pattern of musculocutaneous nerve: cases possessing supernumerary head of bicipital brachial muscle. *Jikeikai Med J*, 33: 195–208.
- Kosugi K, Shibata S, Yamashita H (1992) Supernumerary head of biceps brachii and branching pattern of the musculocutaneous nerve in Japanese. *Surg Radiol Anat*, 14: 175–185.
- McCormack LJ, Claudwell EW, Anson BJ (1953) Brachial and antebrachial arterial patterns. A study of 750 extremities. *Surg Gynecol Obstet*, 96: 43–54.
- Miller RA (1934) Comparative studies upon the morphology and distribution of the brachial plexus. *Am J Anat*, 54: 143–175.
- Miller RA (1939) Observations upon the arrangement of the axillary artery and brachial plexus. *J Am Anat Rec*, 64: 143–163.
- Müller E (1903) Beiträge zur morphologie des gefässsystems. *Anat Hafte*, 22: 379–574.
- Rodriguez-Niedenfuhr M, Vazquez T, Nearn L, Ferreira B, Parkin I, Sanudo JR (2001) Variations of the arterial pattern in the upper limb revisited: a morphological and statistical study, with a review of the literature. *J Anat*, 199: 547–566.
- Sahin B, Seelig LL (2000) Arterial, neural and muscular variations in the upper limbs of a single cadaver. *Surg Radiol Anat*, 22: 305–308.
- Sarikcioglu L, Coskun N, Ozkan O (2001) A case with multiple anomalies in the upper limb. *Surg Radiol Anat*, 23: 65–68.
- Sarikcioglu L, Yildirim FB (2003) High origin of the radial artery accompanied by muscular and neural anomalies. *Ann Anat*, 185: 179–182.
- Schmidt HM, Lahl J (1988) Untersuchungen an den Sehnenfächern der streckmuskeln am meschlingen handrücken und ihrer Sehnencheiden. *Gegenbaurs Morphol Jahrb*, 134: 155–173.
- Schulz CU, Anetzberger H, Pfahler M, Maier M, Refior HJ (2002) The relation between primary osteoarthritis of the trapeziometacarpal joint and supernumerary slips of the abductor pollicis longus tendon. *J Hand Surg Br*, 27: 238–241.
- Shinohara H, Naora H, Hashimoto R, Hatta T, Tanaka O (1990) Development of the innervation pattern in the upper limb of staged human embryos. *Acta Anat (Basel)*, 138: 265–269.
- Uzun A, Seelig LL Jr (2001) A variation in the formation of the median nerve: communicating branch between the musculocutaneous and median nerves in man. *Folia Morphol*, 60: 99–101.
- Venieratos D, Anagnostopoulou S (1998) Classification of communications between the musculocutaneous and median nerves. *Clin Anat*, 11: 327–331.