

# Split median nerve. A report of two cases

Aleksander Król, Artur Palczak, Kazimierz S. Jędrzejewski

Department of Normal Anatomy, Medical University of Łódź, Poland

[Received 13 May 2005; Revised 3 November 2005; Accepted 3 November 2005]

*Two variations of the median nerve described in the Lanz study as type 3 anomalies were found during dissection. In the first case the median nerve splits in the cubital fossa and descends through the carpal tunnel to the palm of the hand. In the second of the reported cases the median nerve splits 45 mm before entering the carpal tunnel and is accompanied by a persistent median artery. Surgeons should take such variations into consideration in order to plan surgical approaches judiciously.*

**Key words:** median nerve variations, split median nerve, persistent median artery, carpal syndrome

## INTRODUCTION

The median nerve (MN) is often involved in pathological states such as the carpal tunnel syndrome or various injuries of the palm and forearm. Anomalies of MN have been precisely described by Lanz [9] and can be classified into four types: motor branch variations, a distally arising accessory branch, a high division of MN and a proximally arising accessory branch. There have also been reports of a split MN accompanied by a persistent median artery (PMA). In this study two Lanz type 3 anomalies are presented.

## MATERIAL AND METHODS

The two variations were found during routine dissection of upper limbs in the Department of Normal Anatomy of the Medical University of Łódź. These specimens were fixed with a 4% solution of formaldehyde. The skin, the superficial fascia, the *retinaculum flexorum* and the *aponeurosis palmaris* were removed. In both cases observations were made of the limbs separated from the cadaver body.

## RESULTS

In the first of the cases presented MN originates from the brachial plexus in the typical manner as a connection between two branches of the lateral and medial cord. In the arm MN runs down

in the medial groove of the biceps muscle at first laterally and then posteriorly to the brachial artery (BA). The MN then crosses the brachial artery posteriorly before entering the cubital fossa. The arteries of this limb do not show any divergence from the pattern usually described in manuals and textbooks.

In the cubital fossa the common trunk of MN divides into two branches. The major branch, as we have termed it, which resembles a typical MN, passes between the heads of the *pronator teres* muscle and descends on the forearm under the *flexor digitorum superficialis* muscle (FDSM).

On exiting the carpal tunnel the major branch splits into common digital nerves and gives branches to the thenar, a *ramus palmaris* passing through the retinaculum and a communicating branch with the minor branch of MN (Fig. 1).

The minor branch, which could be considered a third common digital nerve of MN of very early origin, splits from MN, covered by the ulnar head of the *pronator teres* muscle, by which the minor branch is also pierced. At the distal third of the forearm the minor branch lies on the tendons of FDSM, covered only by the *palmaris longus* muscle.

The minor branch passes in the carpal tunnel centrally and superficially to the flexor tendons.



**Figure 1.** The bifurcation of the median nerve in the cubital fossa — first case; 1 — median nerve; 2 — major branch; 3 — minor branch; 4 — ulnar head of the SDFM (pulled away).

Before crossing the superficial palmar arch from below, the minor branch receives two connecting branches: one from the ulnar nerve and the second the afore-mentioned communicating branch from the major branch. Finally the minor branch divides into two proper digital nerves, which innervate the lateral part of the of the fourth finger and the medial part of the third finger (Fig. 2).

The second of the cases presented is an early division of MN accompanied by a persistent median artery (PMA). The MN described divides into two branches 45 mm before entering the carpal tunnel. In this case the minor branch does not receive any communicating branches. The minor branch, similarly to the minor branch of the first case, splits into two proper digital nerves at the level of the metacarpophalangeal joints. The major branch divides into two common digital nerves at the level of the thenar. In both cases only the major branch participates in the thenar muscle innervation (Fig. 3).

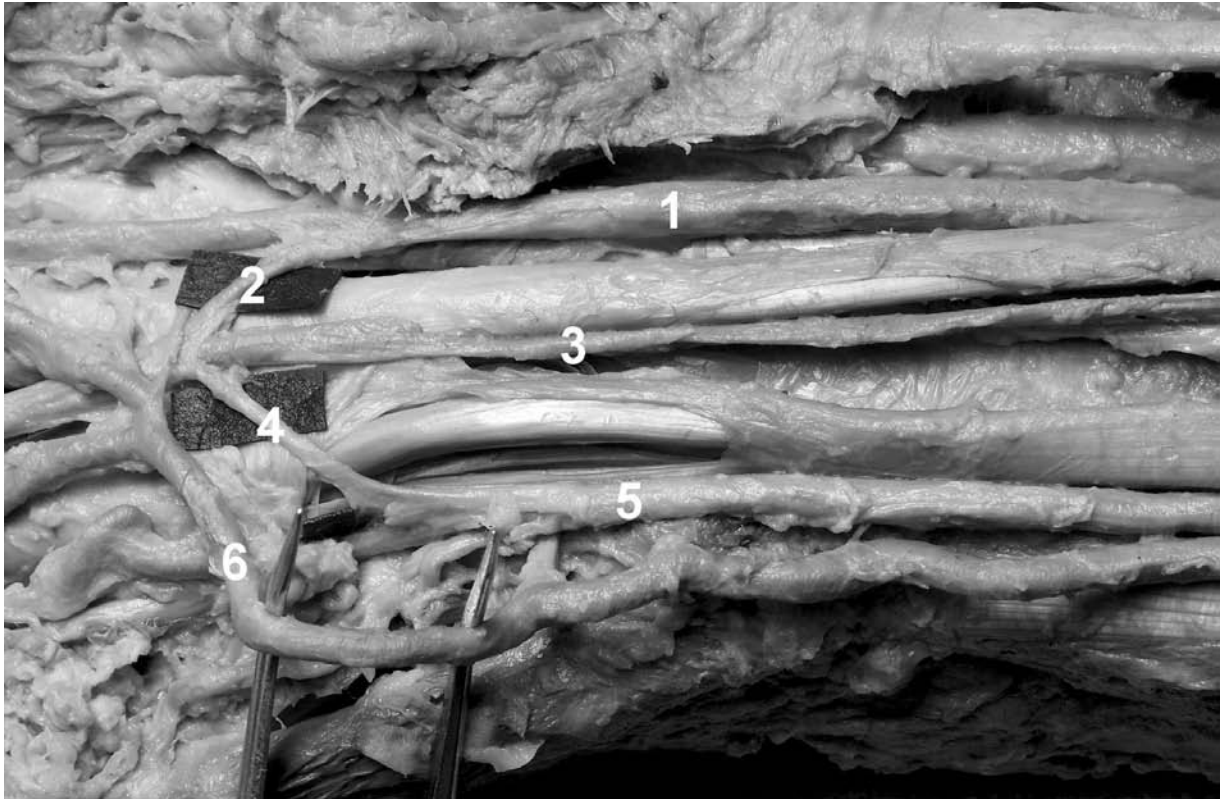
The PMA is a long but slender vessel which originates from the ulnar artery and descends with MN to the palm of the hand. In the carpal tunnel PMA is situated superficially to the branches of MN On the

palm under the aponeurosis PMA splits into two common digital arteries supplying the thumb, the second finger and the lateral part of the third finger. No connections were found with the ulnar artery or the superficial branch of the radial artery.

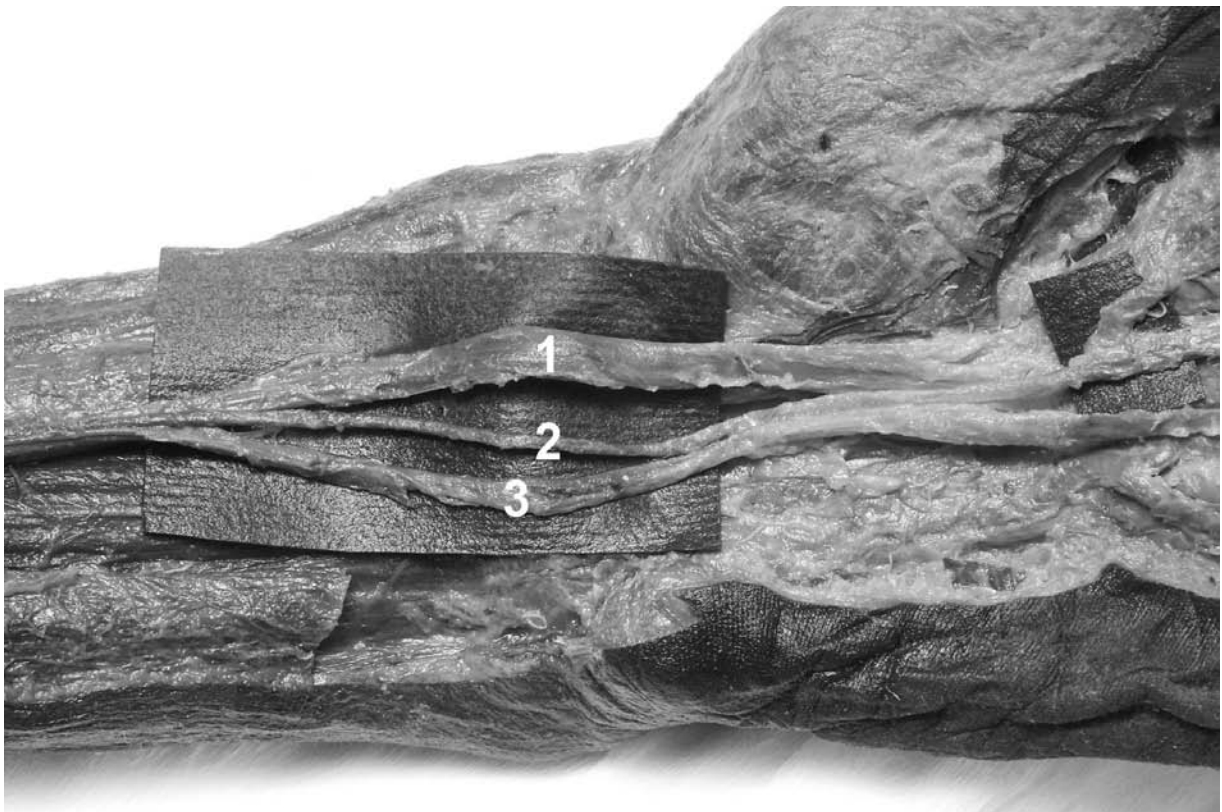
## DISCUSSION

Cases of a split MN are observed mostly during surgical interventions or anatomical dissection, more rarely during preoperative sonographic or MR imaging, and appear with a frequency range of 1–3% (2.8% according to the Lanz study [9]). The division occurs on different levels but most typically on the distal third of the forearm [1, 9]. The minor branch is usually situated more superficially on the forearm than the major branch and passes centrally through the carpal tunnel with the flexor tendons, making it more susceptible to compression and injury.

The coexistence of the split MN with other anomalies, such as an abnormal insertion of a muscle or PMA, appears to be quite frequent [1, 8]. Ebied [6] describes an improper insertion of the *palmaris longus* muscle which entraps the split MN. Sanudo et al. [11]



**Figure 2.** View of the distal forearm and carpus — first case; 1 — major branch; 2 — communicating branch from the major branch; 3 — minor branch; 4 — communicating branch from the ulnar nerve; 5 — ulnar nerve; 6 — superficial palmar arch.



**Figure 3.** Second case. 1 — major branch; 2 — PMA; 3 — minor branch.

present a highly dividing MN which forms a ring around PMA just below the distal margin of the *pronator teres* muscle.

The PMA has been described as originating from the ulnar, anterior interosseus, radial or brachial artery [1, 10] and either terminates on the forearm or descends to the palm of the hand. On the palm PMA may, according to Coleman and Anson's study [4], form an arch (medioulnar or radiomedioulnar) or divide into its terminal branches without forming any superficial arterial connections. The PMA presented originates from the ulnar artery and does not anastomose with any other superficial artery, making it resemble Coleman's type 1.

Variations of MN have, as some authors claim [3, 7, 13], significant clinical implications. The minor branch is more susceptible to injury than the typical MN [12]. Carpal tunnel syndrome is more likely to appear and presents more treatment problems. When a bifid MN is encountered during surgical release both branches should be decompressed [13]. In some cases a split MN has forced surgeons to convert endoscopic to open release [3]. The PMA, because of prolonged compression in the carpal tunnel, is more susceptible to thrombotic changes [2] and may also complicate treatment.

In conclusion, emphasis should be put on knowledge of the variations of MN in order to avoid accidental injuries and also to increase the effectiveness of surgical approaches.

## REFERENCES

1. Adachi B (1928) Das Arteriensystem der Japaner. Adachi B (ed.). Verlag der Kaiserlich-Japanischen Universität zu Kyoto, Kyoto.
2. Aulicino PI, Klavans SM, Dupuy TE (1984) Digital ischemia secondary to thrombosis of persistent median artery. *J Hand Surg*, 9: 820–823.
3. Cavallo AV, Slattery PG, Barton RJ (2003) Endoscopic carpal tunnel release and congenital anomalies of the median nerve. *Hand Surg*, 8: 265–270.
4. Coleman SS, Anson BJ (1961) Arterial patterns in the hand based upon a study of 650 specimens. *Surg Gynecol Obstet*, 113: 409–424.
5. Doyle J (2003) Surgical anatomy of the hand and upper extremity. Lippincott Williams and Wilkins.
6. Ebied AM (1999) Split median nerve. *Microsurgery*, 19: 404–405.
7. Ianniceli E, Chianta GA, Salvini V, Almerberger M, Monaceli G, Passariello R (2000) Evaluation of bifid median nerve with sonography and MR imaging. *J Ultrasound Med*, 19: 481–485.
8. Lacoste P, Dalle M (1966) Anomalie arterielle de l'avant-bras et de la main. Essais d'interprétation embryologique. *Compte rendus de l'Association des Anatomistes*, 132: 563–570.
9. Lanz U (1997) Anatomical variations of the median nerve in the carpal tunnel. *J Hand Surg*, 2: 44–53.
10. Lippert H, Pabst R (1985) Arterial variations in man. Springer, New York.
11. Sanudo JR, Chkwe J, Evans SE (1994) Anomalous median nerve associated with persistent median artery. *J Anat*, 185: 447–451.
12. Sunderland S (1978) Nerves and nerve injuries. 2<sup>nd</sup> ed. Churchill Livingstone, New York.
13. Takami H, Takahashi S, Ando M (2001) Bipartite median nerve with double compartment within the transverse carpal canal. *Arch Orthop Trauma Surg*, 121: 230–231.