

# The left sternalis muscle variation detected during mastectomy

Burhan Kabay<sup>1</sup>, Ilgaz Akdogan<sup>2</sup>, Bulent Ozdemir<sup>2</sup>, Esat Adiguzel<sup>2</sup>

<sup>1</sup>Pamukkale University Faculty of Medicine, Department of General Surgery, Denizli, Turkey

<sup>2</sup>Pamukkale University Faculty of Medicine, Department of Anatomy, Denizli, Turkey

[Received 27 September 2005; Accepted 27 October 2005]

*The sternalis muscle variation is a well-known anatomical situation. It is present in 8.7% of women and 6.4% of men, although the incidence varies according to sex, race and ethnicity. During a left modified radical mastectomy operation on a 46-year-old female patient a sternalis muscle was detected on the pectoralis major muscle in the superficial fascia. It was in craniocaudal position and was parallel to the body of the sternum. The cylindrical muscle was approximately 8 cm in length and 2 cm in diameter. Such variations are considered to have their origin in embryological development. Awareness of muscular variations and their identification is important both for procedure through the proper dissection planes during breast surgery and in radiological examination and follow-up.*

**Key words:** sternalis muscle, thorax, breast, mastectomy, variation

## INTRODUCTION

The sternalis muscle is a well-known anatomical variation [7]. It is located at the anterior wall of the thorax in the parasternal region [1]. According to Turner, it was named by Cabrolio in 1604 [1] and in 1926 the features of the muscle were described by Dupuy [1, 7].

Incidence of the muscle varies according to sex, race and ethnicity [1]. It is more common among women (8.7%) than among men (6.4%) [10]. It is present among white races in 2.9–6.4%, while among black races it is present in 11% [6]. Ethnic background is also important in view of the distribution of the sternalis muscle in certain population groups; the incidence is 4–8% in Indians [5], 13.1% in Japanese, 3.3% in Filipinos and 1% Chinese [6]. It is usually unilateral [2]. Anatomists use a number of different terms to refer to the sternalis muscle, such as the “parasternal”, “*pectoris rectus*” or “*praester-nalis*” muscle [1].

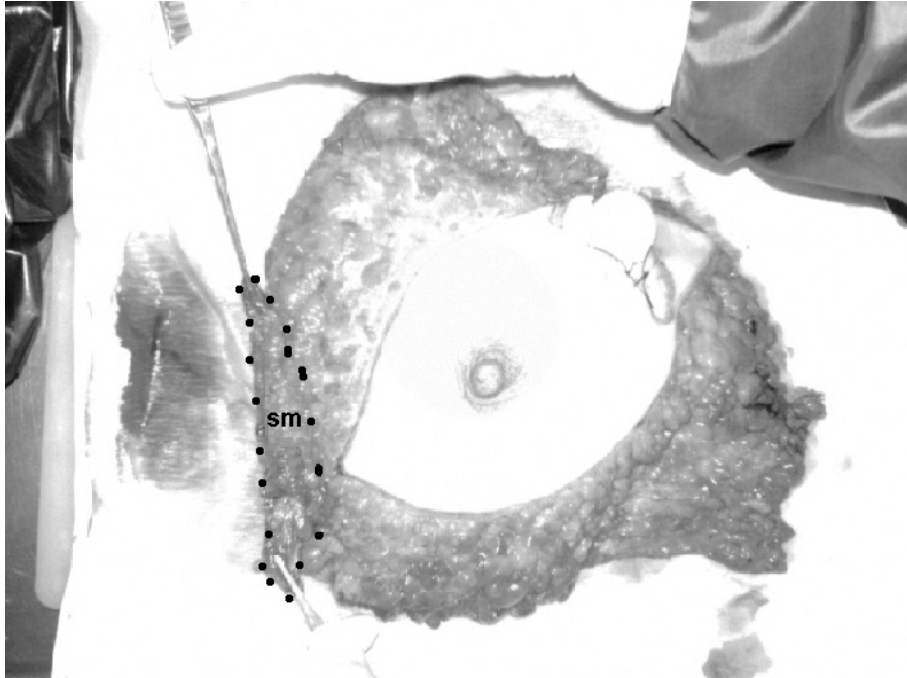
Even though, as has been remarked, the sternalis muscle variation is well known in the literature, information about it is inadequate with the exception that supplied by a few anatomy books [7]. It is defined as a muscle that begins from the lower part of the ribs and the rectus sheath and then courses upward, finally inserting the upper part of the sternum and ribs or the sternocleidomastoid [3]. The positioning of the sternalis muscle adjacent to the breast is of clinical importance.

## CASE REPORT

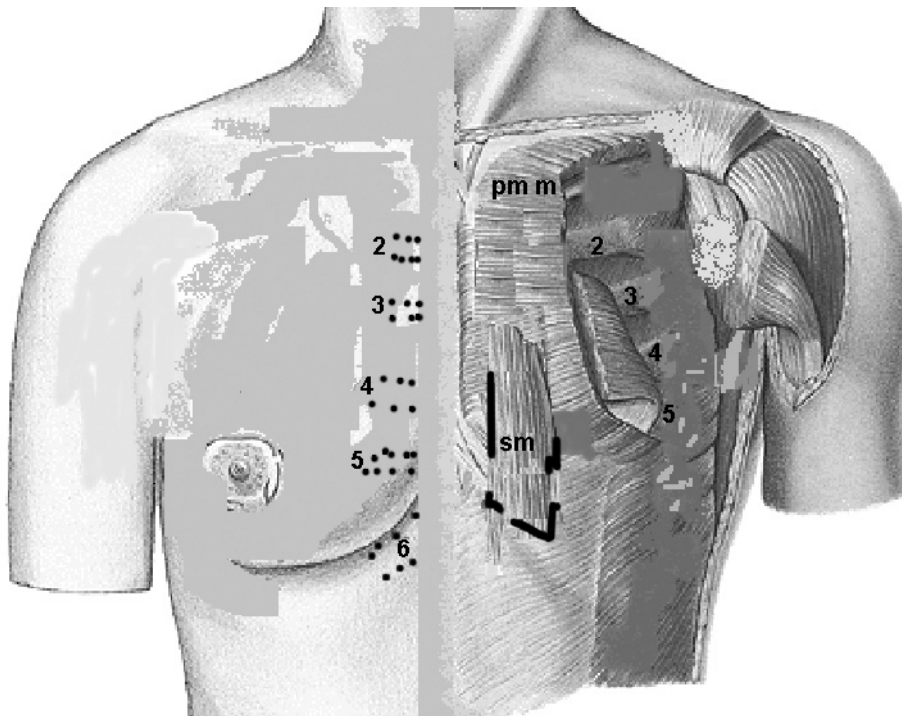
During a left modified radical mastectomy operation on a 46-year-old female patient for stage III invasive ductal carcinoma a left sternalis muscle was encountered after dissection of the skin flaps. The muscle was located anterior to the thorax and was detected between the superficial and deep sheath of the superficial fascia on the *pectoralis major* muscle and fascia parallel to the sternum in craniocaudal position.

It lay between the 3<sup>rd</sup> rib and 6-7<sup>th</sup> rib cartilage lateral to the insertion of the *pectoralis major* muscle (Figs. 1, 2). The sternalis muscle was removed with the breast and

was found to be a cylindrical muscle of approximately 8 cm in length and 2 cm in diameter. The muscle tissue was verified in histological examination.



**Figure 1.** Photograph showing the sternalis muscle during the modified radical mastectomy operation; sm — sternalis muscle.



**Figure 2.** The diagram showing the position of the sternalis muscle; sm — sternalis muscle; pmm — pectoralis major muscle; 2, 3, 4, 5, 6 — ribs 2, 3, 4, 5 and 6 (computer modified using the figures in the Netter Human Anatomy Atlas and the Sobotta Human Atlas).

## DISCUSSION

We report here the case of a sternalis muscle encountered during a left modified radical mastectomy and removed *en bloc* with the specimen. The muscle was removed because of its close proximity (although without macroscopic invasion) to the tumoral mass and the positioning of a thick layer of breast tissue under the muscle. Leaving this muscle in its place might have been detrimental to the oncological surgery of the breast. Firstly, the pectoral fascia and the entire breast tissue must be included in the specimen during modified radical mastectomy. Secondly, muscle tissue in close proximity to the tumoral mass may harbour tumoral nests within lymphatics penetrating the muscle. For dissection of the pectoral fascia and the breast tissue to be complete and to ensure that no tumour tissue is left in place, this muscle was included in the specimen. The decision to remove the muscle or not may be affected by its localisation, direct invasion with the tumour and the presence of breast tissue under the muscle. Removal of the muscle did not cause any functional or cosmetic loss and it was easy to dissect with the pectoral fascia under it.

Most skeletal muscle is derived from the myotome regions of the somites. Some head and neck muscles are derived from branchial or pharyngeal arch mesoderm. The limb muscles develop *in situ* from somatic mesoderm. Cardiac muscle and most smooth muscle is derived from splanchnic mesoderm. The sternalis appeared to be a continuation of the *rectus abdominis* muscle. However, it might be derived from a primitive ventral longitudinal muscle sheet which gives rise to the pectoralis, sternocleidomastoid, *rectus abdominis* and ventrolateral part of the diaphragm [9]. The sternalis is probably derived from the pectoral muscle group [7]. Turner suggests that the sternalis could be an upward prolongation of the *rectus abdominis* or a downward extension of the sternocleidomastoid. It is probably a vestigial remnant of muscle lost during evolution that is expressed in some individuals [5].

The origin and nerve supply of the sternalis muscle have, therefore, puzzled anatomists. Most authors, however, hold the view that it is derived from the *pectoralis major* muscle. Kida et al. [7] worked on 40 cases over 15 years and discovered that the sternalis muscle is supplied by the pectoralis nerves. Branches of the intercostal nerves may pierce the muscle to become cutaneous but do not directly supply the sternalis. No attempt was made in our study to demonstrate muscle innervation and vascularisation. The function of the

muscle is uncertain [5], although anomalies of the sternalis in association with abnormalities of the *pectoralis major* have been described [7, 8].

There is a need to record and discuss unusual anatomical variants with the use of complex diagnostic and therapeutic tools as these variants could present a challenge to the radiologist or surgeon in making a diagnosis. The sternalis muscle can be easily overlooked during breast surgery and may often cause a diagnostic dilemma on mammography or CT scans. In mammography the sternalis muscle can mimic a malignant breast mass [4]. Surgeons and radiologists must therefore be familiar with it and its location and orientation must be known in order to decide whether to remove the muscle or not. In our view the removal of this muscle helps complete dissection of the breast tissue and pectoral fascia, especially for tumours located in the inner upper and lower quadrants. We advise that the muscle be removed for this type of tumour. In the event of pre-operative confusion, a CT scan or MR imaging can aid in establishing the diagnosis.

A recent case report indicates that many surgeons are not familiar with the sternalis muscle [2]. However, awareness of the muscle and its early identification are necessary in order to proceed in an appropriate plane during surgical dissection. This case report puts forth the importance of the sternalis muscle for surgeons and radiologists.

## REFERENCES

1. Arraez-Aybar LA, Sobrado-Perez J, Merida-velasco JR (2003) Left musculus sternalis. *Clin Anat*, 16: 350–354.
2. Bailey PM, Tzarnas CD (1999) The sternalis muscle: a normal finding encountered during breast surgery. *Plast Reconstr Surg*, 103: 1189–1190.
3. Bannister LH, Berry M, Collins P, Dyson M, Dussek JE, Ferguson MWJ (1995) *Gray's anatomy*, 38<sup>th</sup> ed. Churchill Livingstone, Edingburg, p. 838.
4. Bradley FM, Hoover HC Jr, Hulka CA, Whitman GJ, McCarthy KA, Hall DA, Moore R, Kopans DB (1996) The sternalis muscle: an unusual normal finding seen on mammography. *Am J Roentgenol*, 166: 33–36.
5. Harish K, Gopinath KS (2003) Sternalis muscle: importance in surgery of the breast. *Surg Radiol Anat*, 25: 311–314.
6. Jeng H, Su SJ (1998) The sternalis muscle: an uncommon anatomical variant among Taiwanese. *J Anat*, 193: 287–288.
7. Kida MY, Izumi A, Tanaka S (2000) Sternalis muscle: topic for debate. *Clin Anat*, 13: 138–140.
8. O'Neill MN, Folan-Curran J (1998) Case report: bilateral sternalis muscles with a bilateral pectoralis major anomaly. *J Anat*, 193: 289–292.
9. Sadler TW (2004) *Langman's medical embryology*, 9<sup>th</sup> ed. Lippincott Williams and Wilkins, Baltimore, pp. 199–209.
10. Scott-Conner CEH, Al-Jurf AS (2002) The sternalis muscle. *Clin Anat*, 15: 67–69.