

Absence of the musculocutaneous nerve together with unusual innervation of the median nerve*

M.E. Aydin, A. Kale, M. Edizer, C. Kopuz, M.T. Demir, U. Çorumlu
Ondokuz Mayıs University, Medical Faculty, Department of Anatomy, Samsun, Turkey

[Received 21 October 2005; Revised 5 June 2006; Accepted 5 July 2006]

During routine anatomical dissections, absence of the musculocutaneous nerve was determined in a 58-year-old male cadaver. Moreover, the biceps brachii and brachialis muscles were innervated by two separate branches which divided from the median nerve instead of the musculocutaneous nerve. From a branch that divides from the main trunk of the median nerve at nearly the middle of the arm a motor branch again divided that innervated the brachialis muscle and a sensory branch that conveyed the sense of the lateral part of the forearm. Furthermore, it was found that the brachial artery divided into its terminal branches, the radial and ulnar arteries. We believe that this rare variation of the median nerve will shed light upon surgical procedures involving the median nerve.

Key words: musculocutaneous nerve, median nerve, unusual innervation

INTRODUCTION

Since the brachial plexus is a structure in which several spinal nerves unite and divide, variations its formation are common [1, 8, 9]. There are, however, few reports of the absence of the terminal branches of the brachial plexus [8].

Normally the lateral cord gives its first branch, the lateral pectoral nerve, to the pectoralis major muscle and then divides into the musculocutaneous nerve and the lateral root of the median nerve. The lateral root of the median nerve then joins the medial root from the medial cord to form the median nerve, which lies anterior to the third part of the axillary artery [9].

The anatomical abnormalities and variations of these nerves of the brachial plexus have recently become significant because of new imaging techniques such as computed tomography and magnetic resonance imaging. Moreover, investigation of these variants is important in order to define the anatomical features of each in relation to clinical diagnosis and for surgical procedures.

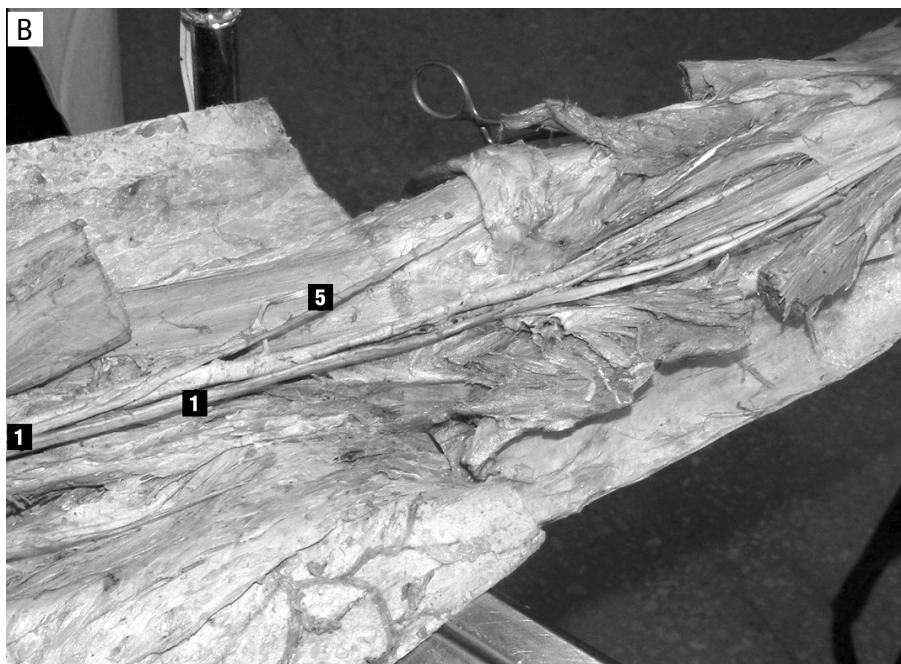
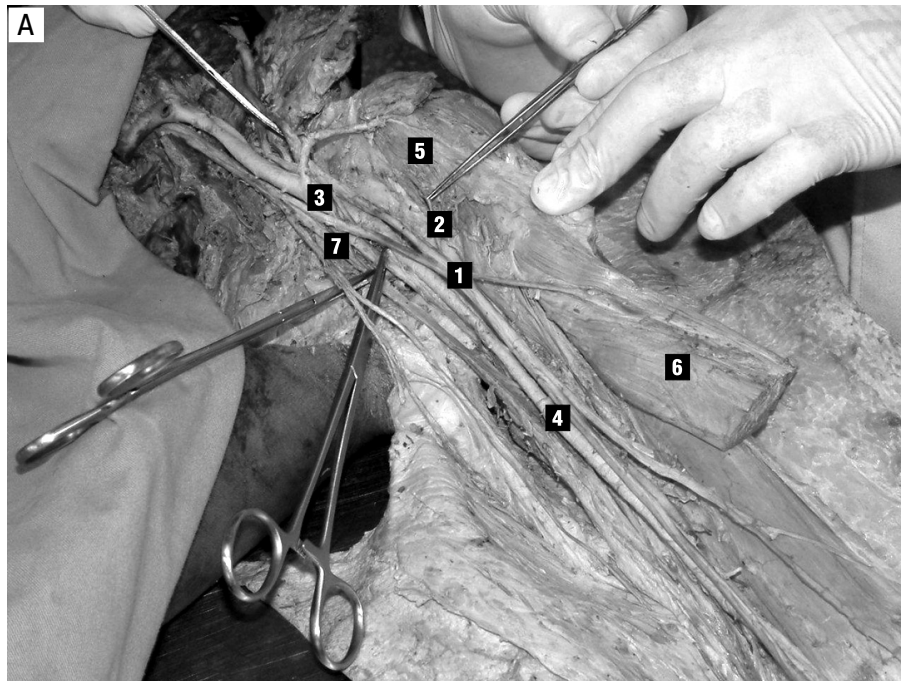
RESULTS

In our study it was established that the musculocutaneous nerve was absent from the left arm of a 58-year-old male formalin-fixed cadaver of the Anatomy Laboratory of Ondokuz Mayıs Medical Faculty. We first determined that the musculocutaneous nerve did not divide from the lateral cord and then that it was in fact absent. A nerve connection leaving the lateral cord divided in front of the brachial artery, uniting the lateral and medial cords and the lateral cord and ulnar nerve separately.

By hyperabducting the upper extremity it was found that the medial and lateral fascicles of the median nerve united 6 cm distal to a line passing from the coracoid process to the lower border of the second costa and that the point of convergence was at the level of the insertion of the pectoralis major muscle to the

Address for correspondence: Assist. Prof. Dr. M.E. Aydin, Yeni Mahalle, Giresun Sok., Kardelen Sitesi, D-Blok, No. 7, Atakent-Samsun, Turkey, Fax: 0 90 362 4576091; e-mail: mepaydin@yahoo.com

*Presented at the Sixth International Symposium of Clinical Anatomy, 8-10 October, Varna-Bulgaria



Figures 1A and B. Photograph showing the musculocutaneous nerve to be absent and an unusual innervation of the median nerve. 1 — median nerve; 2 — unusual innervation of the coracobrachialis muscle; 3 — nerve connection between the lateral and medial cords; 4 — brachial artery; 5 — an unusual innervation of the lateral part of the forearm; 6 — biceps brachii muscle; 7 — ulnar nerve.

humerus (Fig. 1A). At a distance 0.5 cm inferior to the point of union a branch left the median nerve which innervated the coracobrachialis muscle. Another branch of the median nerve, which divided from it 2 cm inferior to the point of union, was found to be innervating the biceps brachii muscle (Figs. 1B, 2).

The median nerve gave out a branch which divided from it 8 cm inferior to the junction of the cords and this branch coursed its way to the forearm. Two nerves that divided from this branch innervated the brachialis muscle. This branch became superficial just inferior to a line connecting the

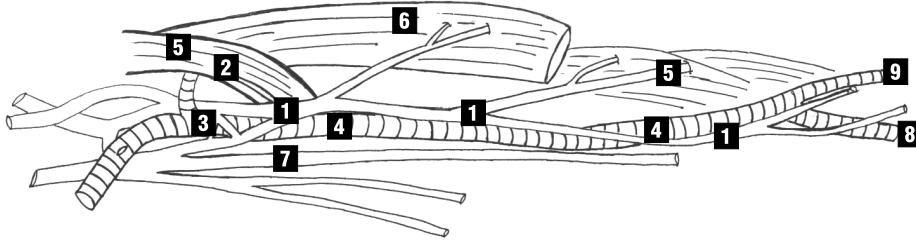


Figure 2. Drawing based on a photograph of dissected left arm and forearm. The axillary artery has been removed to show the nerves and axillary artery clearly. 1 — median nerve; 2 — the unusual innervation of the coracobrachialis muscle; 3 — the nerve connection between the lateral cord and medial cords; 4 — brachial artery; 5 — the unusual innervation of the lateral part of the forearm; 6 — biceps brachii muscle; 7 — ulnar nerve; 8 — ulnar artery; 9 — radial artery.

medial and lateral epicondyles, providing the lateral part of the skin innervation of the forearm.

The major terminal branch of the median nerve passed deep to the two heads of the pronator teres muscle at the cubital fossa and continued its way and the innervation at the forearm. At a distance 7.5 cm inferior to the line connecting the medial and lateral epicondyles the brachial artery, a neighbour of the median nerve, divided into its terminal branches, the radial and ulnar arteries. This differed from the usual point of division.

DISCUSSION

Normally the musculocutaneous nerve is given off opposite the lower border of the pectoralis minor muscle. It pierces the coracobrachialis muscle and descends laterally between the biceps and the brachialis muscles to the lateral side of the arm. Just below the elbow it pierces the deep fascia laterally to the tendon of the

biceps muscle and continues as the cutaneous nerve of the forearm [9]. Subsequently, in its course through the arm, it supplies the coracobrachialis, biceps brachii and the greater part of the brachialis muscles [6].

Bergman provided a list of variations in the course and distribution of the musculocutaneous nerve. He reported that this nerve arose from the lateral cord (90.5%), from the lateral and posterior cords (4%), from the median nerve (2%), as two separate bundles from the medial and lateral cords (1.4%) or from the posterior cord (1.4%). Moreover, he reported that it might be doubled, unusually short or absent [2].

In our case the musculocutaneous nerve was found to be absent. Absence of the nerve was also reported by Le Minor, Gumusburun and Adiguzel, Ihunwo et al., Bergman, Sud and Song [2–5, 8, 9]. Nakatani et al., [7] Le Minor [5], Gumusburun and Adiguzel [3] also reported the absence of the musculocutaneous nerve (Fig. 3). In particular Sud's case

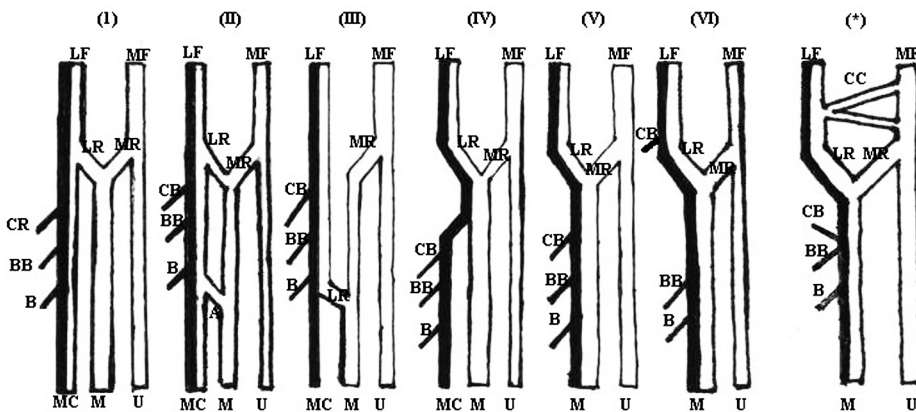


Figure 3. Illustration of six types of musculocutaneous and median nerve and our case showed with an asterisk (*). LF — lateral cord; MF, medial cord; MC — musculocutaneous nerve; U — ulnar nerve; M — median nerve; CB — coracobrachialis muscle; BB — biceps brachii muscle; B — brachialis muscle; CC — the nerve connection between the lateral cord and the medial cord; LR — lateral root of the median nerve; MR — medial root of the median nerve.

was similar to this present instance in that the motor nerve to the muscles of the anterior compartment of the arm arose from the median nerve.

Le Minor classified the variations of musculocutaneous and median nerves into five types [5] (Fig. 3). The present case, however, was of a specific type and did not fall within any of these five categories. In this case there is a nerve connection between the medial and lateral cords which originates from the lateral cord with two bundles and relies on the medial cord to unite them

Another finding in our case was that the cutaneous innervation of the lateral part of the forearm was procured by a thick nerve which divided from the median nerve. Our case differed from previous cases in two different features. One was the unusual innervation of the forearm muscles by the median nerve, while the other was the unusual cutaneous innervation of the lateral part of the forearm by the median nerve.

A further interesting finding was that the brachial artery, which is a neighbour of the median nerve, divided into its terminal branches, the radial and ulnar arteries, 7.5 cm inferior to the line connecting the medial and lateral epicondyles. Normally the brachial artery commences at the lower margin of the tendon of the teres major and passes down the arm, ending about 1 cm below the bend of the elbow, where it divides into the radial and ulnar arteries [6]. Our case introduced for us the notion of a genuine absence of the musculocutaneous nerve rather than that of a conjoined form with the course of the median and the musculocutaneous nerves uniting.

Knowledge of anatomical variations in the brachial plexus such as the absence of the musculocu-

taneous nerve and of muscles that are innervated by unusual nerves may help clinicians faced with indecipherable clinical signs. This kind of case may provide additional explanation for the unexpected clinical symptoms that depend on different nerve courses and origins. Our case includes not only rare nerve variations but also an arterial variation. We believe that these will be illuminating for surgical procedures.

REFERENCES

1. Bergman R, Afifi AK, Miyauchi (2004) Median nerve. Illustrated Encyclopedia of Human Anatomic Variation. Opus III: Nervous System: Plexuses.
2. Bergman R, Afifi AK, Miyauchi R (2004) Musculocutaneous nerve. Illustrated Encyclopedia of Human Anatomic Variation. Opus III: Nervous System: Plexuses.
3. Gumusburun E, Adiguzel E (2000) A variation of the brachial plexus characterized by the absence of the musculocutaneous nerve: a case report. *Surg Radiol Anat*, 22: 63–65.
4. Ihunwo AO, Osinde SP, Mukhtar AU (1997) Distribution of median nerve to muscles of the anterior compartment of the arm. *Cent Afr J Med*, 43: 359–360.
5. Le Minor JM (1990) A rare variation of the median and musculocutaneous nerves in man. *Arch Anat Histol Embryol*, 73: 33–42.
6. Lewis WH (ed.) (2000) *Anatomy of the human body* (written by Gray H). 20th Ed. New York: Bartleby.com. On-line edition, section 6b the anterior divisions paragraphs: 51,61, section 4b brachial artery paragraph 1.
7. Nakatani T, Shigenori T, Mizukami S (1997) Absence of the musculocutaneous nerve with innervation of coracobrachialis, biceps brachii, brachialis and the lateral border of the forearm by branches from the lateral cord of the brachial plexus. *J Anat*, 191: 459–460.
8. Song WC, Jung HS, Shin C, Lee BY, Koh KS (2003) A variation of the musculocutaneous nerve absent. *Yonsei Med J*, 44: 1110–1113.
9. Sud M (2000) Absence of the musculocutaneous nerve and innervation of coracobrachialis, biceps brachii and brachialis from the median nerve. *J Anat Soc India*, 49: 176–177.