

Malignant fibrous histiocytoma of the spermatic cord: a case report and review of the literature

M.M. Shoja¹, R.S. Tubbs^{2, 3}, I. Asvadi⁴, R.M. Farahani¹, F. Seyednejad⁵, W.J. Oakes³

¹Department of Anatomical Sciences, University of Medical Sciences, Tabriz, Iran

²Department of Cell Biology University of Alabama at Birmingham Children's Hospital, Alabama, USA

³Section of Pediatric Neurosurgery, University of Alabama at Birmingham Children's Hospital, Alabama, USA

⁴Department of Hematology/Oncology, University of Medical Sciences, Tabriz, Iran

⁵Department of Radiotherapy, University of Medical Sciences, Tabriz, Iran

[Received 27 July 2006; Revised 30 October 2006; Accepted 30 October 2006]

Malignant fibrous histiocytoma (MFH) is a morphologically ill-defined tumour of the soft tissues and may involve nearly every organ of the body. MFH of the spermatic cord represents an extremely rare entity and reports of it in the literature are limited. We report a 69-year-old man found to have a left spermatic cord MFH and retroperitoneal and mediastinal lymphadenopathy, who was treated with radical orchiectomy and adjuvant chemotherapy. The morphological findings of the spermatic tumour are presented and the literature is reviewed to clarify the potential diagnostic/therapeutic approaches and the prognosis related to spermatic cord MFH.

Key words: malignant fibrous histiocytoma, pleomorphic, spermatic cord

INTRODUCTION

Since it was described in 1964 by O'Brien and Stout [34], malignant fibrous histiocytoma (MFH) has represented an ill-defined entity, comprising five or six histological subtypes (pleomorphic-storiform, giant-cell, inflammatory, fibrous, myxoid and angiomatoid), which partially differ both clinically and prognostically [20, 35]. Although it has been hypothesised that these variants manifest the common morphological patterns of a heterogeneous group of poorly differentiated tumours, there are still controversies regarding the concept of MFH as a distinct tumour entity [1, 5, 11, 15, 20, 31]. The pleomorphic, giant-cell and inflammatory variants each represent heterogeneous diagnostic groups that are hard to defend as a cohesive entity, while the myxoid (myxofibrosarcoma) and angiomatoid types are rather reproducible tumour types. It is quite possible that a number of cases of MFH have been for-

merly classified as pleomorphic liposarcoma or pleomorphic rhabdomyosarcoma [40] because of their intracellular fat-laden lipoblast-like or large eosinophilic cells. Although a matter of debate, MFH is still widely accepted as a discrete clinicopathological entity. This supports the hypothesis that MFH is a morphological modulation in the tumoral progression of other sarcomas, particularly leiomyosarcomas.

The pleomorphic subtype of MFH is regarded as the most common soft tissue sarcoma of adulthood. However, there are currently no definable criteria for its diagnosis. In fact, several recent studies have expressed considerable doubts regarding MFH, or at least its pleomorphic type, as a distinct entity and have suggested that it represents a common morphology of a group of poorly differentiated sarcomas [15, 16] and, more rarely, other neoplasms. Features generally considered characteristic of pleomorphic MFH include cells arranged in a storiform pattern

with frequent giant cells and an area of pleomorphism and intense anisonucleosis [35]. While 70% of MFHs arise as a primary tumour, others are associated with pre-existing conditions such as radiation therapy or fracture [22, 40]. Malignant fibrous histiocytoma shows a distinct gender predilection with an approximate male to female ratio of 2 to 1. Its highest incidence is during the fifth decade of life [22]. Malignant fibrous histiocytoma has a high propensity for local recurrence (44%) and distant metastasis (42%) [51].

Here we report a patient with MFH of the spermatic cord. Known as a connective tissue neoplasia, MFH may occasionally involve such organs as the spleen, heart, colon, breast, ovary, testes, kidney (or its capsule), trachea, thyroid gland, vulva and glans penis [1, 12, 13, 19, 23–25, 33, 36, 38, 50, 52]. Spermatic cord MFH is an extremely rare tumour, first reported by Cole et al. [8]. We now review the literature on this rare finding.

CASE REPORT

A 69-year-old man with a history of hypertension and cigarette smoking (65 packs per year) since early childhood sought medical consultation because of left scrotal enlargement of one month's duration. Physical examination showed a painless mass surrounding the left spermatic cord, making it difficult to palpate.

A spermatic cord tumour being suspected, a left radical inguinal orchiectomy was performed. Grossly, the specimen consisted of a yellow elastic mass measuring 15 × 7 × 6 cm. Its cut section showed a solid mass of 7 cm in diameter filling and surrounding the spermatic cord. Microscopic inspection of the tumour revealed extensive necrotic areas involving the spermatic cord and a proliferation of spindle-type cells in a storiform pattern. These spindle cells were of an unusual morphology with severe nuclear pleomorphism and hyperchromasia as well as atypical mitotic figures (Fig. 1). Scattered mitoses were identified at 5–6 per 10× high-powered fields. A high-grade MFH (pleomorphic storiform subtype) of the spermatic cord was diagnosed. Post-operative abdominal computed tomography demonstrated retroperitoneal and mediastinal lymph-node enlargement. Subsequently the patient received two courses of chemotherapy, of four and twelve weeks respectively, following orchiectomy. Chemotherapy (mesna 500 mg/m²/day × 4 days, doxorubicin 20 mg/m²/day × 3 days, ifosfamide 2500 mg/m²/day × 3 days and dacarbazine 3000 mg/m²/day × 3 days) was

tolerated and the patient is currently doing well. At a follow-up of 18 months no signs of local recurrence or metastasis were identified.

DISCUSSION

Malignant fibrous histiocytoma is the most common soft-tissue tumour in adults [35] and, as mentioned before, can be found in nearly every organ of the body. However, its occurrence in the spermatic cord represents a very rare entity. Nearly 80% of spermatic cord MFHs occur in patients who are older than 50 years. Spermatic MFH usually presents as a slowly growing, painless, well-circumscribed solitary mass in the scrotum inguinal region and may distinctly encircle the spermatic cord [27, 30]. Reported sizes range from less than 1 cm to more than 20 cm at presentation [21, 27, 30]. The largest tumour of spermatic cord MFH, with a diameter of 27 cm, was reported in a holocaust survivor who had been subjected to unethical Nazi medical experimentation by intratesticular injection with an unknown substance [45]. The mass related to the spermatic MFH may present for weeks, months or years before coming to medical attention [46]. MFH may be painful, depending on the histological subtype (inflammatory or giant-cell MFH for example) [21].

Diagnosis

Currently, excisional biopsy and microscopic examination of tissue specimens are considered to be the gold-standard method for the diagnosis of MFH. Grossly, the specimen is frequently a well-circumscribed, yellowish solid tumour. Spermatic cord MFH may infiltrate the vas deferens, pampiniform plexus and adjacent adipose tissues [32]. The epididymis and testis are characteristically not infiltrated, with the exception of neglected cases and the giant-cell subtype of MFH [21, 32, 45, 47]. Approximately 25% of specimens demonstrate a satellite nodule at presentation, conveying a worse prognosis [17]. Histopathologically, 83% of spermatic cord MFH are of the pleomorphic subtype, 9% giant-cell and 6% of the inflammatory and, very rarely, myxoid subtypes [27]. Ultrastructural or immunohistochemical features have also been applied for diagnosing a MFH. Immunohistochemistry displays vimentin reactivity and negativity for keratins and leukocytic common antigen [4].

Recently, a combination of fine-needle aspiration (FNA) for cytological examination and immunohistochemistry was applied to examine a patient with

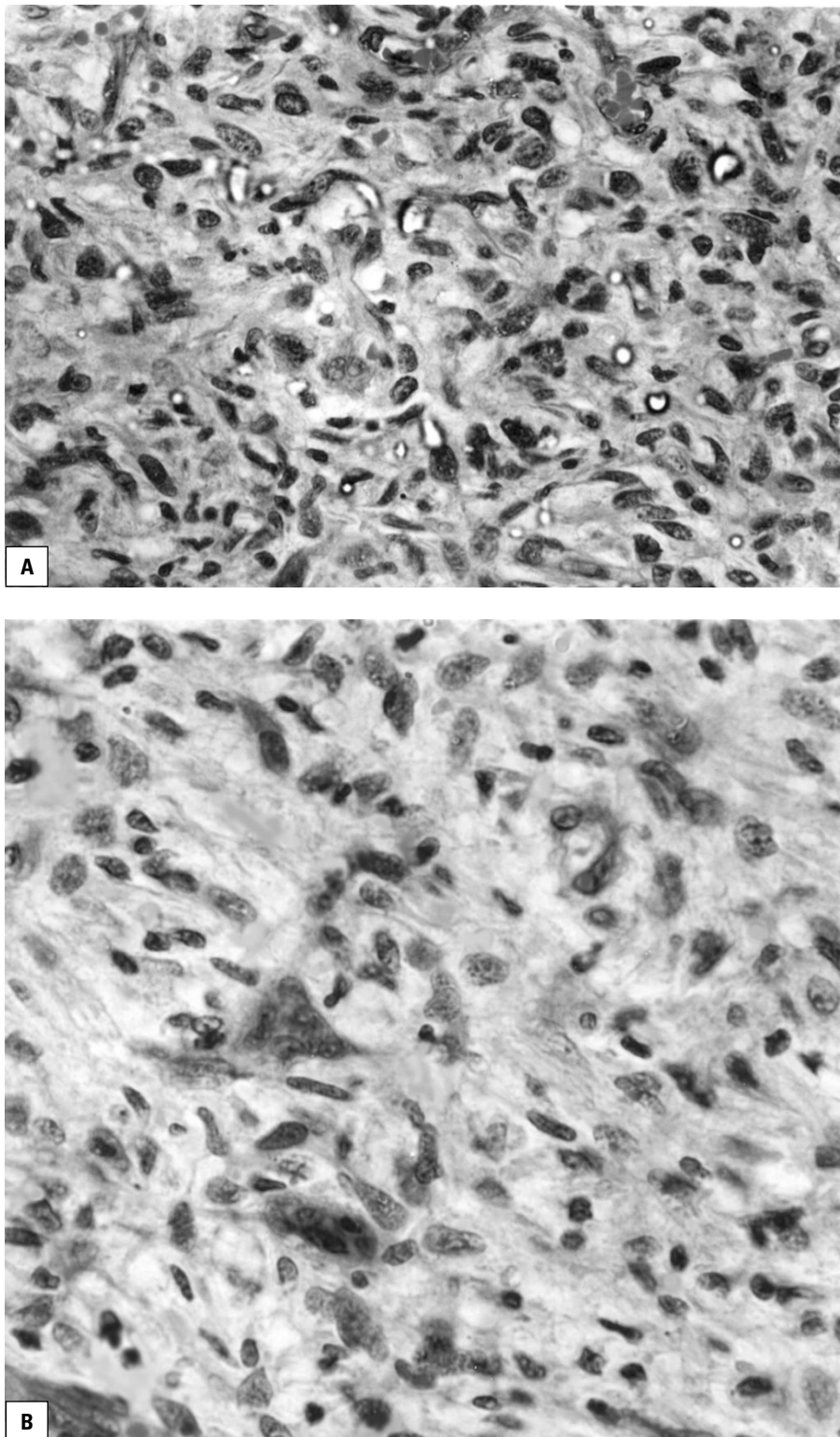


Figure 1. Micrographs of the spermatic malignant fibrous histiocytoma; storiform pattern spindle cells of unusual morphology, severe nuclear pleomorphism and hyperchromasia and atypical mitotic figures can be seen (A). Focal inflammatory infiltration and occasional giant cells (B) are found.

a spermatic cord mass and surprisingly demonstrated a pleomorphic subtype of MFH [4]. FNA of this lesion demonstrated bloody fluid with several small

tissue fragments. A pleomorphic appearance and marked anaplasia as well as vimentin reactivity were found on cytological examination of these fragments,

confirming the diagnosis of spermatic cord MFH of the storiform subtype. This finding, later confirmed by surgical excision and histological examination, confirmed the results obtained from FNA. The authors suggested that a FNA combined with immunohistochemical studies may replace the gold-standard open biopsy in the diagnosis of a spermatic cord MFH [4].

The ultrasonographic appearance of a spermatic cord MFH may closely resemble that of tumours elsewhere in the body as a lobulated and heterogeneous mass [17, 18, 21]. However, these signals are not specific for MFH. The MRI sensitivity and specificity for detecting a MFH are 96% and 83%, respectively [29, 30, 49].

Prognosis and treatment

Owing to its location, the prognosis and management of spermatic MFH appear to differ from that of a tumour of this type in other locations [17, 42, 48]. It seems that spermatic MFH has a more favourable prognosis even for larger lesions [17, 48], the prognosis being more related to histological subtype than tumour size. The rate of local recurrence and distant metastasis are 34.5% and 17.2%, respectively [30]. The five-year survival rate is about 20% [10].

Radical inguinal orchiectomy, along with a wide *en bloc* resection of adjacent soft tissue, has been used for spermatic MFH [17, 35]. Regional radiation therapy, said to be a useful adjuvant therapy, has also been used for the prevention of local recurrences [17, 35]. More conservative therapy, such as tumorectomy, has also been used for masses smaller than 8 cm [48]. Chemotherapy is infrequently used for spermatic cord MFH, as its benefits are unknown in view of the limited reports available. A combination of therapies has been used with a favourable outcome for the treatment of the inflammatory type of spermatic cord MFH [41]. In the present case there was retroperitoneal lymphadenopathy that led us to initiate systemic chemotherapy. Table 1 demonstrates reported cases of spermatic MFH with the emphasis on their treatment plan. The induction of autoimmune disease against tumour-specific „neoantigens“ seems to be another promising potential modality of treatment that could hypothetically be used for spermatic MFH and is currently under investigation.

As mentioned earlier, the prognosis of spermatic MFH differs from that of tumours of this kind in other locations [2, 6, 7, 26, 28, 37, 39, 43]. Metastases

Table 1. Various treatments for malignant fibrous histiocytoma of the spermatic cord

Coleman et al. 2003 [9]	Aggressive surgical strategies, including preoperative wide resection
Orio et al. 2002 [35]	Radical orchiectomy and radiation therapy
Urdiales-Viedma et al. 2002 [48]	Tumorectomy
Sekine et al. 2001 [41]	High orchiectomy plus postoperative chemoradiotherapy
Uchida et al. 1999 [47]	Radical orchiectomy with resection of the surrounding scrotal skin
Fagundes et al. 1996 [14]	Radical orchiectomy and local excision plus adjuvant radiation therapy
Staiman et al. 1996 [45]	Radical orchiectomy and partial scrotectomy
Glazier et al. 1996 [17]	Radical orchiectomy and localised radiotherapy
Mitsumori et al. 1993 [30]	Local tumour excision with subsequent radical inguinal orchidectomy
Hyouchi et al. 1996 [21]	Radical inguinal orchiectomy and regional postoperative irradiation
Sclama et al. 1983 [39]	Orchiectomy and wide local excision plus retroperitoneal lymphadenectomy

may develop late in the lungs or mesentery. Intra-abdominal lymphadenopathy and distant metastasis to the lung or mesentery could be assessed initially and followed with computed tomography, especially in patients with a worse prognosis and a higher risk of progression.

In conclusion, spermatic cord MFH, a rare tumour of this location, should be considered in the differential diagnosis of scrotal, inguinal and/or spermatic cord masses [3, 9, 14, 44]. Clinicians and surgeons should have a thorough knowledge of spermatic cord malignant fibrous histiocytoma.

REFERENCES

1. Akatsu Y, Saikawa Y, Kubota T, Kiyota T, Nakamura R, Akatsu T, Takahashi T, Yoshida M, Otani Y, Kumai K, Kitajima M (2006) Metastatic gastric cancer from malignant fibrous histiocytoma: report of a case. *Surg Today*, 36: 385–389.
2. Andreu Garcia A, Schiefenbusch Munne E, Brotons Marquez JL, Luque Moreno D, Llamazares Cacha G (1994) Malignant fibrohistiocytoma of the spermatic cord. Report of a case. *Arch Esp Urol*, 47: 525–528.
3. Ballo MT, Zagars GK, Pisters PW, Feig BW, Patel SR, von Eschenbach AC (2001) Spermatic cord sarcoma: outcome, patterns of failure and management. *J Urol*, 166: 1306–1310.

4. Bosch-Princep R, Martinez-Gonzalez S, Alvaro-Naranjo T, Castellano-Megias VM, Salvado-Usach MT, Marti-Mestre J (2000) Fine needle aspiration and touch imprint cytology of a malignant fibrous histiocytoma of the spermatic cord. Case report. *Acta Cytol*, 44: 423–428.
5. Brooks JJ (1986) The significance of double phenotypic patterns and markers in human sarcomas. A new model of mesenchymal differentiation. *Am J Pathol*, 125: 113–123.
6. Brown MD, Swanson NA (1989) Treatment of malignant fibrous histiocytoma and atypical fibrous xanthomas with micrographic surgery. *J Dermatol Surg Oncol*, 15: 1287–1292.
7. Lin BT, Harvey DA, Medeiros LG (2002) Malignant fibrous histiocytoma of the spermatic cord: report of two cases and review of the literature. *Mod Pathol*, 15: 59–65.
8. Cole AT, Straus FH, Gill WB (1972) Malignant fibrous histiocytoma: an unusual inguinal tumor. *J Urol*, 107: 1005–1007.
9. Coleman J, Brennan MF, Alektiar K, Russo P (2003) Adult spermatic cord sarcomas: management and results. *Ann Surg Oncol*, 10: 669–675.
10. de Bruin MJ, Pelger RC, Meijer WS, Giard RW (1989) Malignant fibrous histiocytoma of the spermatic cord. *J Urol*, 142: 131–133.
11. Derre J, Lagace R, Nicolas A, Mairal A, Chibon F, Coindre JM, Terrier P, Sastre X, Aurias A (2001) Leiomyosarcomas and most malignant fibrous histiocytomas share very similar comparative genomic hybridization imbalances: an analysis of a series of 27 leiomyosarcomas. *Lab Invest*, 81: 211–215.
12. Dilek TU, Dilek S, Pata O, Tataroglu C, Tok E (2006) Malignant fibrous histiocytoma of the ovary: a case report. *Int J Gynecol Cancer*, 16 (suppl 1): 352–356.
13. Eroglu M, Bakirtas H, Cimentepe E, Unsal A, Ataoglu O, Balbay MD (2005) Malignant fibrous histiocytoma arising from the renal capsule. *Urol Int*, 75: 368–370.
14. Fagundes MA, Zietman AL, Althausen AF, Coen JJ, Shipley WU. The management of spermatic cord sarcoma. *Cancer*, 1996; 77: 1873–1876.
15. Fletcher CD (1992) Pleomorphic malignant fibrous histiocytoma: fact or fiction? A critical reappraisal based on 159 tumors diagnosed as pleomorphic sarcoma. *Am J Surg Pathol*, 16: 213–228.
16. Fletcher CD (2006) The evolving classification of soft tissue tumours: an update based on the new WHO classification. *Histopathology* 48: 3–12.
17. Glazier DB, Vates TS, Cummings KB, Pickens RL (1996) Malignant fibrous histiocytoma of the spermatic cord. *J Urol*, 155: 955–957.
18. Gore RL, Auber AE. Ultrasonographic appearance of malignant fibrous histiocytoma of the spermatic cord: a case report. *Mil Med*, 1993; 158: 631–633.
19. Gupta C, Malani AK (2006) Primary malignant fibrous histiocytoma of the colon. *Clin Gastroenterol Hepatol* [Epub ahead of print].
20. Hollowood K, Fletcher CD (1995) Malignant fibrous histiocytoma: morphologic pattern or pathologic entity? *Semin Diagn Pathol*, 12: 210–220.
21. Hyouchi N, Yamada T, Takeuchi S, Machida T, Kanou H, Tanizawa A, Kamata S, Saitoh H, Itoyama S (1996) Malignant fibrous histiocytoma of spermatic cord: a case report. *Hinyokika Kiyo*, 42: 469–471.
22. Kanazawa H, Watanabe T, Kasamatsu A. Primary malignant fibrous histiocytoma of the mandible: review of literature and report of a case. *J Oral Maxillofac Sur*, 2003; 61: 1224–1227.
23. Katona TM, Shienbaum AJ, Wyatt LL, Brown GA, Cheng L (2006) Malignant fibrous histiocytoma of the glans penis: a case report. *Anal Quant Cytol Histol*, 28: 39–42.
24. Katsuura Y, Ishida H, Komatsuda T, Furukawa K, Yagisawa H, Yamada M, Ohno H, Kotanagi H, Miyauchi T, Saitoh K (2006) Malignant fibrous histiocytoma of the spleen: report of a case and literature review. *Abdom Imaging* [Epub ahead of print].
25. Kwak HS, Kim CS, Lee JM (2003) MR findings of renal malignant fibrous histiocytoma. *Eur Radiol*, 6 (suppl L): 245–246.
26. Le Doussal V, Coindre JM, Leroux A, Hacene K, Terrier P, Bui NB, Bonichon F, Collin F, Mandard AM, Contesso G (1996) Prognostic factors for patients with localized primary malignant fibrous histiocytoma: a multicenter study of 216 patients with multivariate analysis. *Cancer*, 77: 1823–1830.
27. Lin BT, Harvey DA, Medeiros LJ (2002) Malignant fibrous histiocytoma of the spermatic cord: report of two cases and review of the literature. *Mod Pathol*, 15: 59–65.
28. May M, Marusch F, Helke C, Gunia S, Gastinger I, Hoschke B (2004) Locally recurrent malignant fibrous histiocytoma of the kidney and spermatic cord. *Urologe A*, 43: 976–981.
29. Mahajan H, Kim EE, Wallace S, Abello R, Benjamin R, Evans HL (1989) Magnetic resonance imaging of malignant fibrous histiocytoma. *Magn Reson Imaging*, 7: 283–288.
30. Miller TT, Hermann G, Abdelwahab IF, Klein MJ, Kenan S, Lewis MM (1994) MRI of malignant fibrous histiocytoma of soft tissue: analysis of 13 cases with pathologic correlation. *Skeletal Radiol*, 23: 271–275.
31. Mitsumori K, Horii Y, Akao T, Nakagawa T, Ohbayashi T, Sawada S (1993) Malignant fibrous histiocytoma of the spermatic cord: a case report. *Hinyokika Kiyo*, 39: 1063–1066.
32. Nistal M, Regadera J, Jareno E, Paniagua R (1988) Inflammatory malignant fibrous histiocytoma of the spermatic cord. *Urol Int*, 43: 188–192.
33. Novelli L, Anichini C, Pedemonte E, Tozzini S, Gori F, Nesi G (2005) Malignant fibrous histiocytoma as a primary cardiac tumor. *Cardiovasc Pathol*, 14: 276–279.
34. O'Brien JE, Stout AP (1964) Malignant fibrous xanthomas. *Cancer*, 17: 1445–1448.
35. Orio PF 3rd, Dahiya R, Herman T, Thomas CR Jr, Eng TY (2002) Malignant fibrous histiocytoma of the spermatic cord: a case report. *Am J Clin Oncol*, 25: 227–229.
36. Pavlovsky Z, Jandakova E, Stratil D, Hotarkova S (2006) Malignant fibrous histiocytoma of the breast: report of two cases *Cesk Patol*, 42: 39–42.

37. Pezzi CM, Rawlings MS Jr, Esgro JJ, Pollock RE, Romsdahl MM (1992) Prognostic factors in 227 patients with malignant fibrous histiocytoma. *Cancer*, 69: 2098–2103.
38. Sakao Y, Tomimitsu S, Takeda Y, Natsuaki M, Itoh T (2005) Malignant fibrous histiocytoma of the trachea. *Jpn J Thorac Cardiovasc Surg*, 53: 276–279.
39. Sclama AO, Berger BW, Cherry JM, Young JD Jr (1983) Malignant fibrous histiocytoma of the spermatic cord: the role of retroperitoneal lymphadenectomy in management. *J Urol*, 130: 577–579.
40. Seidel C, Bartel F, Rastetter M, Bluemke K, Wurl P, Taubert H, Dammann R (1989) Alterations of cancer-related genes in soft tissue sarcomas: hypermethylation of RASSF1A is frequently detected in leiomyosarcoma and associated with poor prognosis in sarcoma. *Int J Cancer*, 114: 442–447.
41. Sekine Y, Ohki K, Okamoto K, Nomura M, Tomita H, Ohtake N, Suzuki K, Kurokawa K, Mashimo M, Saruki K, Morita T, Nakazato H, Yokoo H, Yamanaka H (2001) Malignant fibrous histiocytoma of the right spermatic cord: a case report. *Int J Urol*, 8: 581–584.
42. Sethi S, Ashok S (2003) Malignant fibrous histiocytoma of the spermatic cord. *J Indian Med Assoc*, 101: 599–600.
43. Smailowitz Z, Kaneti J, Sober I, Krugliak L, Sacks M (1983) Malignant fibrous histiocytoma of the spermatic cord. *J Urol*, 130: 150–151.
44. Sogani PC, Grabstald H, Whitmore WF Jr (1978) Spermatic cord sarcoma in adults. *J Urol*, 120: 301–305.
45. Staiman VR, O'Toole KM, Rubin MA, Lowe FC (1996) Giant malignant fibrous histiocytoma of the testis/spermatic cord: psychologic and possible etiologic complications of unethical Nazi medical experimentation. *Urology*, 48: 939–943.
46. Tanaka T, Akazawa N, Ozaki Y, Matsumura Y, Ohmori H (1984) Malignant fibrous histiocytoma originating in the left spermatic cord with a review of 14 cases in the literature. *Jpn J Clin Oncol*, 14: 437–443.
47. Uchida K, Oda T, Adachi H, Wakabayashi J, Hisasue S, Takagi Y (1999) Malignant fibrous histiocytoma of the spermatic cord: a case report. *Int J Urol*, 6: 630–632.
48. Urdiales-Viedma M, Fernandez-Rodriguez A, Martos-Padilla S, Pichardo Pichardo S (2002) Malignant fibrohistiocytoma of the spermatic cord. *Actas Urol Esp*, 26: 581–584.
49. Vilanova JC, Woertler K, Narvaez JA, Barcelo J, Martinez SJ, Villalon M, Miro J (2006) Soft-tissue tumors update: MR imaging features according to the WHO classification. *Eur Radiol* [Epub ahead of print].
50. Vural B, Ozkan S, Yildiz K, Corakci A, Gurbuz Y (2005) Malignant fibrous histiocytoma of the vulva: a case report. *Arch Gynecol Obstet*, 273: 122–125.
51. Weiss SW, Enzinger FM (1978) Malignant fibrous histiocytoma: an analysis of 200 cases. *Cancer*, 41: 2250–2266.
52. Yavuz AA, Cobanoglu U, Genc M, Yavuz MN, Kosucu P, Aslan MK (2005) Malignant fibrous histiocytoma of the thyroid gland: recurrence treated by radiotherapy. *J Otolaryngol*, 34: 216–220.