

Type I split cord malformation with an unusual bony morphology

G. Shokouhi, R.S. Tubbs, M.M. Shoja

Departments of Neurosurgery and Anatomy and Cell Biology, University of Tabriz, Tabriz, Iran, and University of Alabama at Birmingham, Birmingham, Alabama, USA

[Received 8 September 2006; Revised 23 November 2006; Accepted 23 November 2006]

Variations in the configuration of the bony septum found in patients with split cord malformations are rare. We report the seemingly rare occurrence of a mid-line bony septum that ended posteriorly as a fully formed bony spinous process. We speculate that this variation is due to misplaced mesodermal cells associated with the primitive endomesenchymal tract during approximately the third week of foetal life. The clinician that manages these patients may wish to consider this rare morphology and avoid excessive manipulation of such a process, which could potentially injure an underlying hemicord.

Key words: variation, spine, spinal cord, bone, spinous process

INTRODUCTION

Split cord malformation (SCM), the current term used to describe the entities known as diastematomyelia and diplomyelia, is of interest to both clinicians and embryologists. Although thought to be secondary to a single embryological error, the molecular aspects of this malformation remain to be determined. Apparently, the development of the spinal column and cord is a final consequence of a complex mesenchymal, ectodermal and endodermal interaction. Pang et al. [4] have proposed a unified theory of embryogenesis for SCM. This theory maintains that all types of SCM are caused by a single embryonic error occurring during the first month of intrauterine development and are due to an accessory neuroenteric canal. Several bony morphologies related to SCM have been reported. We report an unusual bony variation in a patient with Type I SCM that, to our knowledge, has not previously been discussed in the medical literature. The two dominant radiographic characteristics of a Type I lesion are double dural tubes and an osseous or osseocartilaginous midline septa. Rostrally, the hemicords stretch a variable distance before rejoining. The two dominant radiographic characteristics

of a Type II SCM are that a single thecal sac houses the full length of the split spinal cord segments and that these are separated by a non-rigid median septum. In general, the hemicords in a Type II lesion are much closer together and the split spinal cord segment much shorter than in a Type I lesion.

CASE REPORT

A 14-year-old girl presented to our clinic with a three-year history of increasing pain in her lower extremities together with urinary incontinence. Her physical examination revealed mild spastic paraparesis and atrophy of the right posterior leg. Deep tendon reflexes were found to be exaggerated. The Babinski sign was negative bilaterally. No sensory disturbances or gross lower extremity deformities were found. A 4 × 4 cm area of focal hirsutism was noted over the upper lumbar region. A CT scan of the lumbar spine was performed showing a bony septum originating from the posterior surface of the L1 vertebral body and extending posteriorly to become the spinous process (Fig. 1). The neural arch at this level was not completely formed in that the laminae failed to fuse medially with the spinous process (Fig. 1).

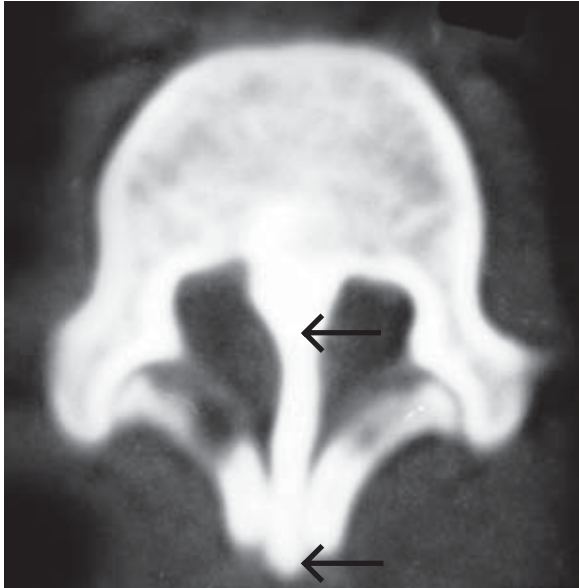


Figure 1. Axial CT image of our case illustration. Note the midline bony septum (arrow) extending posteriorly as the spinous process (arrow) of this vertebra.

No evidence of syringomyelia was found. With the diagnosis of SCM, the patient underwent an exploratory procedure where the midline bony septum was resected. At clinical follow-up six months later the patient had total recovery from her lower extremity symptoms with improved urinary bladder continence.

DISCUSSION

The current case represents a presumably rare bony variation in a patient with Type I SCM, in that the midline bony septum extended posteriorly, beyond the neural arch, to become the precursor of the adult bony spinous process. The laminae in this case did not fuse with the midline bony septum (i.e. there was an occult spina bifida). Involvement of the endomesenchymal tract in the formation of spinal structures posterior to the level of the dorsal dura has been noted by various authors and discussed by Pang et al. [4]. These discussions have postulated that the migration of neural crest cells dorsally into the extradural space may result in the formation of such entities as meningocele manqué and aberrant blood vessels attached to the dorsal dura. The unified theory proposes that SCM results when the notochord process duplicates. An endo-ectodermal adhesion then results in the formation of an acces-

sory neuroenteric fistula, into which mesodermal tissue may become incorporated. The doubled notochord and neural plate may then have the transformation of precursor cells within the endomesenchymal tract become various mesodermal elements. Mesenchymal cells may form midline bony or cartilaginous structures that result in a type I SCM. If the formation of the endomesenchymal tract precedes that of the meninx primitiva, then the midline mesenchyme may form no bony or cartilaginous septum, thus resulting in a type II SCM.

Pang (personal communication) believes any dysmorphism of posterior midline structures in patients with SCM may originate from the meninx primitiva at approximately the third week of foetal life, with the final form dependent on available regional growth factors. Chandra and Mahapatra [2] and Akay et al. [1] and Ersahin [3] collectively reported four cases of dorsally situated bony septum in SCM. These authors theorised that their unusual cases were due to the dorsoventral migration of meninx primitiva cells. However, none of the above cases was noted as having its septum continuing posteriorly as the spinous process, which is not normally seen at the level of bony septation in patients with SCM. The present case illustration demonstrates that the bony septum of SCM may extend even more posteriorly beyond the level of the neural arch and contribute independently to its formation via the spinous process. Knowledge of this bony variation may aid in the interpretation of imaging and in surgical planning.

ACKNOWLEDGEMENT

The authors are grateful to Dr. Dachling Pang for his comments on the present case.

REFERENCES

1. Akay KM, Izci Y, Baysefer A (2002) Dorsal bony septum: a split cord malformation variant. *Pediatr Neurosurg*, 36: 225–228.
2. Chandra PS, Mahapatra RK (1999) An unusual case of dorsally situated bony spur in a lumbar split cord malformation. *Pediatr Neurosurg*, 31: 49–52.
3. Ersahin Y (2000) An unusual split cord malformation. *Pediatr Neurosurg*, 32: 109.
4. Pang D, Dias MS, Ahab-Barmada M (1992) Split cord malformation. I. A unified theory of embryogenesis for double spinal cord malformations. *Neurosurgery*, 31: 451–480.