

Bilateral ossification of the stylohyoid ligament

J. Skrzat, I. Mróz, J. Walocha, J. Zawiliński, J.K. Jaworek

Department of Anatomy, Collegium Medicum, Jagiellonian University, Cracow, Poland

[Received 15 February 2007; Revised 22 June 2007; Accepted 27 June 2007]

This paper presents the case of an adult male skull with bilateral ossification of the stylohyoid complex. The total length of the stylohyoid complex amounts to 62 mm on the left side and 65 mm on the right side. Visual inspection of the stylohyoid revealed the presence of callosities that are located on both stylohyoid complexes at nearly the same level. These sites are regarded as the ossified attachments of the stylohyoid ligaments to the corresponding styloid processes. The skull studied is an example of extreme development of the stylohyoid complex, which could cause severe pain and a restriction of head and neck movement.

Key words: styloid process, hyoid bone, cranial ligaments, stylohyoid complex

INTRODUCTION

The stylohyoid ligament is a fibrous cord stretched between the tip of the styloid process of the temporal bone and the lesser horn of the hyoid bone. This process forms the background for the attachment of numerous muscles and ligaments that are connected to the throat and tongue. The styloid process together with the stylohyoid ligament is referred as the stylohyoid complex. The entire complex can be divided into several segments, including the tympanohyal, stylohyal, ceratohyal and hypohyal segments [9].

Many important anatomical structures are in close proximity to the styloid process and the stylohyoid ligament. It is therefore worth studying the variability of these structures and analysing the possible effects of an ossified stylohyoid complex. Just posterior to the process lies the stylomastoid foramen, through which the facial nerve exits to run anteriorly and medially to the styloid process. The internal carotid artery, the internal jugular vein and the accessory and vagus nerves lie medially. The external carotid artery runs laterally to the stylohyoid ligament. The glossopharyngeal nerve exists in close proximity under the styloid process, stylohyoid mus-

cle and the stylopharyngeal muscle. The elongated styloid process and the ossified stylohyoid ligament can compress some of these structures, leading to mild or severe clinical syndromes, such as sore throat, dysphagia, dysphasia, dysphoria of the throat, otalgia, the sensation of a foreign body in the throat, facial pain radiating to the ear or along the mandible and head and neck pain [3, 5, 11, 13].

The aim of this study is to describe the morphological appearance of the bilateral ossification of the stylohyoid ligament found in a dry human skull.

MATERIAL AND METHODS

A skull with bilateral ossified stylohyoid ligaments is housed in the Department of Anatomy of the Collegium Medicum of the Jagiellonian University. Unfortunately the exact dating and origin of the skull is unknown. Its morphological appearance suggests that it belongs to a recent population. The skull is well preserved, with no noticeable deformities. The marked muscular attachments, strongly developed temporal lines, prominent superciliary ridges, well-developed external occipital protuberance and the shape of the mandible are all indicative of a male skull (Fig. 1).

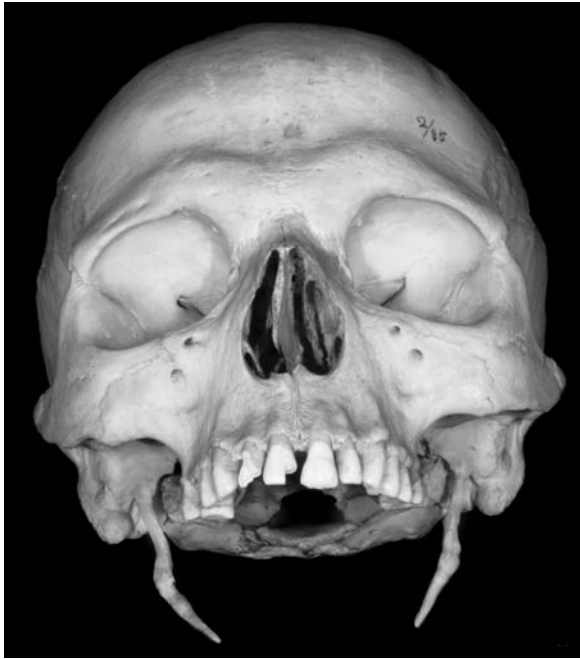

Figure 1. Anterior view of the skull with bilateral ossification of the stylohyoid ligaments (the mandible was removed).

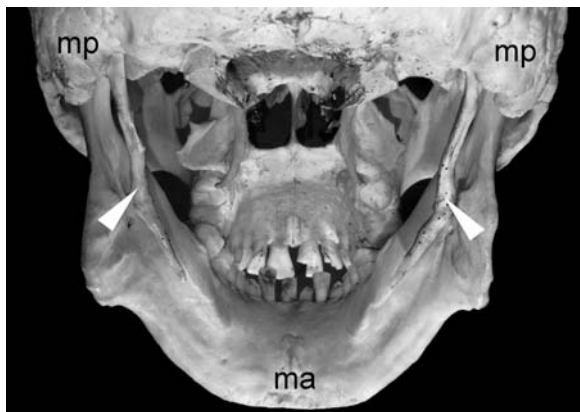

Figure 2. Posterior view of the ossified stylohyoid ligaments (indicated by arrows); ma — mandible, mp — mastoid process.

An anatomical study was performed on the ossified stylohyoid ligaments on both sides of the skull. The length of the osseous complex (the styloid process plus the ossified part of the stylohyoid ligament) was measured using a digital sliding calliper.

RESULTS

Visual inspection of the right and left stylohyoid complex revealed complete ossification of the styloid process and stylohyoid ligament. The ossified parts of the stylohyoid ligaments are clearly visible (Fig. 2, 3). Nevertheless, it is difficult to determine the exact border be-

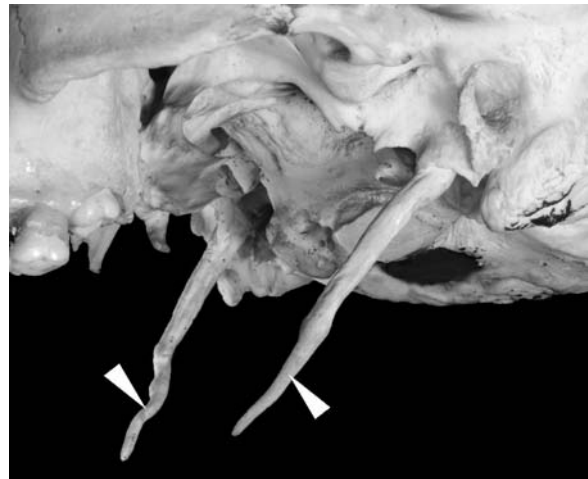

Figure 3. Lateral view of the ossified stylohyoid ligaments (indicated by arrows).

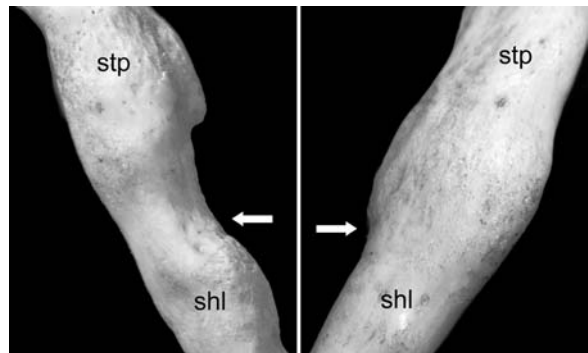


Figure 4. Close-up view of the callosities and apparent ossified attachment (indicated by arrow) of the right and left stylohyoid ligament to the styloid process; stp — styloid process, shl — ossified stylohyoid ligament.

tween the top of the styloid processes and the beginning of the stylohyoid ligaments on both sides. Close observation revealed a bulge of bony mass in the middle parts of the ossified complexes. Its presence may indicate the place of attachment of the ligament to the styloid process (Fig. 4). This place was therefore regarded as the end of the styloid process and served as a landmark for measuring the distance to the cranial base. This distance was treated as equivalent to the length of the styloid process and measured 28 mm on the left side and 31 mm on the right side. The remaining part of the left ossified stylohyoid complex, namely the ligament, measured 34 mm, while the right ossified stylohyoid ligament was 30 mm in length. Thus the total length of the stylohyoid complex amounts to 62 mm on the left side and 65 mm on the right side.

The callosities are located on both stylohyoid complexes at nearly the same level and at a distance

of 31–35 mm from the basicranium. From these places both osseous complexes bend medially. The distance between the bases of the right and left styloid processes was 91 mm while the distance between the ends of the ossified stylohyoid ligaments decreased to 51 mm. This difference between the origins and ends of the two stylohyoid complexes expresses a strong mutually convergent course towards the mid-sagittal plane.

DISCUSSION

The normal length of the styloid process usually varies between 25.0 and 30.0 mm [2]. However, Moffat et al. [14] regard the normal range of the length of the styloid process as between 15.2 mm and 47.7 mm. In human skulls elongation of the styloid process can occur. This condition is regarded as an anatomical anomaly. A styloid process is considered to be elongated when it is longer than 30.0 mm [8, 10, 18, 20]. However, some researchers regard the styloid process as elongated if its length exceeds 40 mm [7, 15]. This anomaly appears in adults with varying frequency, ranging from 2% to 30% [21]. The styloid process can be elongated bilaterally or unilaterally. According to Scaf et al. [18] unilateral elongation of the styloid process is the more frequent unilateral elongation of the styloid process (90.5%). Ossification of the stylohyoid ligament occurs with differing frequency and may be as low as 2–4% or as high as 84.4% but does not cause any symptoms [1, 4]. The incidence of ossification of the stylohyoid ligament or stylohyoid complex (including the styloid process) varies in the published literature and depends on different criteria in radiographic evaluation and patient selection [12].

The skull investigated is a case of extensive bilateral ossification of the stylohyoid ligament, which is firmly fused with the styloid process, forming a long bony trabecula. It is difficult to determine a clear border between the styloid process and part of the ossified ligament. If we accept that the present callosities are the sites of ossified attachments of the stylohyoid ligament to the tip of the styloid process, then its length remains within the normal anatomical range. Because the entire osseous stylohyoid complex is unusually long (more than 50 mm on both sides of the skull), there is no doubt that these structures have resulted from abnormal ossification and are not merely an elongation of the styloid processes. This must have taken

place during cranial development and could have continued during postnatal life.

The stylohyoid ligament derives from the second branchial arch. The cartilaginous element of the second arch (Reichert's cartilage) extends from the otic capsule to the midline in the each side. Thereafter the cartilage gives rise to the styloid process, stylohyoid ligament, the lesser cornu and probably the cranial rim of the body of the hyoid bone. During foetal development Reichert's cartilage links the styloid process to the hyoid bone. Probably owing to ossification of the styloid process the ligament may prolong the ossification, resulting in very long styloid processes. In adults the stylohyoid ligament may retain some of its embryonic cartilage and thus have the potential to become partially or completely ossified [16].

The elongated styloid process, which results from normal biological variation, is a slender smooth pointed process projecting downward and forward from the inferior surface of the temporal bone. When ossification of the stylohyoid ligament propagates along its course there may appear different callosities and the entire complex resembles an irregular bony trabecula, which is usually bent medially. In the case studied a swelling and narrowing on the ossified stylohyoid complexes of both sides of the skull may be perceived.

Abnormal length and anatomy of the stylohyoid complex may cause various clinical symptoms. One of these is Eagle's syndrome, in which the elongated styloid process or ossified stylohyoid ligament is a source of pain [3, 5, 13, 17, 18]. Eagle's syndrome is not frequently suspected in clinical practice, and only in a small percentage of the population does an ossified stylohyoid ligament manifest the clinical symptoms. The syndrome exists at about 28% of the population and is most commonly seen after the age of 30; there is no significant sex predilection [3, 6, 10, 19].

The following are also symptoms associated with ossified stylohyoid complex: a foreign-body sensation in the throat, difficulty in swallowing, dysphagia, headache, otalgia, pain on rotation of the neck, pain on extension of the tongue, a change in voice, facial pain, vertigo, syncope and a sensation of hypersalivation [3, 5, 11, 18].

The case studied is a good example of extreme development of the stylohyoid complex, which could cause severe pain and significantly restricted head and neck movement.

REFERENCES

1. Camarda AJ, Deschamps C, Forest D (1989) Stylohyoid chain ossification: a discussion of etiology. *Oral Surg Oral Med Oral Pathol*, 67: 512–520.
2. Eagle WW (1962) The symptoms, diagnosis and treatment of the elongated styloid process. *Am Surg*, 28: 1–5.
3. Feldman V (2003) Eagle's syndrome: a case of symptomatic calcification of the stylohyoid ligaments. *J Can Chiropr Assoc*, 47: 21–27.
4. Ferrario VF, Sigurta D, Daddona A, Dalloca L, Miani A, Tafuro F, Sforza C (1990) Calcification of the stylohyoid ligament: incidence and morphoquantitative evaluations. *Oral Surg Oral Med Oral Pathol*, 69: 524–529.
5. Godden DRP, Adam S, Woodward RTM (1999) Eagle's syndrome: an unusual cause of a clicking jaw. *Br Dent J*, 186: 489–490.
6. Gossman JR, Tarsitano JJ (1977) The styloid-stylohyoid syndrome. *J Oral Surg*, 35: 555–560.
7. Jung T, Tschernitschek H, Hippen H, Schneider B, Borchers L (2004) Elongated styloid process: when is it really elongated? *Dentomaxillofac Radiol*, 33: 119–124.
8. Kaufman SM, Elzay RP, Irish EF (1970) Styloid process variation: radiologic and clinical study. *Arch Otolaryngol*, 91: 460–463.
9. Keats TE (1992) An atlas of normal roentgen variants that may simulate disease. 5th ed. Mosby, St. Louis.
10. Keur JJ, Campbell JP, McCarthy JF, Ralph WJ (1986) The clinical significance of the elongated styloid process. *Oral Surg Oral Med Oral Pathol*, 61: 399–404.
11. Kirchhoff G, Kirchhoff C, Buhmann S, Lenz K, Vogel T, Kirchhoff RM (2006) A rare differential diagnosis to occupational neck pain bilateral stylohyoid syndrome. *J Occup Med Toxicol*, 1: 14–19.
12. Krennmair G, Piehslinger E (2003) Variants of ossification in the stylohyoid chain. *Cranio*, 21: 31–37.
13. Miller DB (1997) Eagle's syndrome and the trauma patient. *Funct Orthod*, 14: 30–35.
14. Moffat DA, Ramsden RT, Shaw HJ. The styloid process syndrome: aetiological factors and surgical management. *J Laryngol Otol*, 91: 279–294.
15. Monsour PA, Young WG (1986) Variability of the styloid process and stylohyoid ligament in panoramic radiographs. *Oral Surg Oral Med Oral Pathol*, 61: 522–526.
16. Moore KL, Persaud TVN (1998) *The Developmental Human. Clinically Oriented Embryology*. 6th ed. W.B. Saunders Company, Philadelphia, London, Toronto, Montreal, Sydney, Tokyo.
17. Murtagh RD, Caracciolo JT, Fernandez G (2001) CT findings associated with Eagle's syndrome. *Am J Neurol*, 22: 1401–1402.
18. Scaf G, de Freitas DQ, de Castro Monteiro Loffredo L (2003) Diagnostic reproducibility of the elongated styloid process. *J Appl Oral Sci*, 11: 120–124.
19. Silva HJ, Moraes SRA, Santos LCF, Albuquerque CI, Leonel T (2001) Dissection of the stylohyoid chain. A method of approach. *Rev Chil Anat*, 19: 145–148.
20. Sokler K, Sandev S (2001) New classification of the styloid process length — clinical application on the biological base. *Coll Antropol*, 25: 627–632.
21. Zaki HS, Greco CM, Rudy TE, Kubinski JA (1996) Elongated styloid process in a temporomandibular disorder sample: prevalence and treatment outcome. *J Prosthet Dent*, 75: 399–405.