

# A case of multiple abnormalities of the azygos venous system: a preaortic interazygos vein

J. Pyrzowski<sup>1</sup>, J.H. Spodnik<sup>2</sup>, A. Lewicka<sup>1</sup>, A. Popławska<sup>1</sup>, S. Wójcik<sup>2</sup>

<sup>1</sup>Student Research Group of the Department of Anatomy and Neurobiology, Medical University, Gdańsk, Poland

<sup>2</sup>Department of Anatomy and Neurobiology, Medical University, Gdańsk, Poland

[Received 12 September 2007; Accepted 17 October 2007]

*The posterior thoracic wall, an area drained by the azygos venous system, is a common site for surgical intervention. Since the venous part of the cardiovascular system is subject to most common variation, abnormalities in the azygos venous system are often reported. Some of the anatomical variants have significant clinical implications for computed tomography image assessment and mediastinal surgery.*

*During dissection of the posterior mediastinum in a 76 year-old Caucasian male cadaver we found a rare variation in the azygos venous system. The hemiazygos vein drained the left 9<sup>th</sup> to 11<sup>th</sup> left posterior intercostal veins. While passing ventrally to the aorta at the level of the body of the eighth thoracic vertebra it was joined by two separate vessels found to be the continuations of the 7<sup>th</sup> and 8<sup>th</sup> left posterior intercostal veins. The resultant dilated vessel, termed the "interazygos vein", then opened into the azygos vein on the right side of the vertebral column. Variation in the azygos venous system has often been reported, but the abnormality observed by us appears to be extremely rare. The interazygos vein passing ventrally to the aorta may mimic enlarged lymph nodes and cause misinterpretation of a computed tomography image or, if accidentally damaged during mediastinal surgery, may lead to intraoperative haemorrhage. To the best of our knowledge this report provides new data of potential clinical significance.*

**Key words:** azygos vein, interazygos vein, hemiazygos vein, para-aortic mass, anatomical variation

## INTRODUCTION

Venous abnormalities often complicate mediastinal surgery with intraoperative haemorrhage. Accidental damage to large vessels may have life-threatening consequences. Prior knowledge of possible anatomical variants may help the surgeon reduce the risk of such events. Pre-operative radiographic scanning may also be of benefit. It has also been suggested that large venous vessels in unusual locations following oblique courses may lead to misinterpretation of a computed tomography (CT) image by mimicking aneurysms, tumours or enlarged

lymph nodes [3, 13]. In patients with portal hypertension they also have to be differentiated from pre-aortic oesophageal veins [5]. Such venous abnormalities are therefore important in clinical practice.

The azygos vein, a major vessel in the venous system of the thoracic wall, arises from the right ascending lumbar vein on the level of the first or second lumbar vertebra and sometimes from an additional root derived from either the right renal vein or the inferior vena cava. After entering the thorax, most commonly through the right crus of the diaphragm, it ascends in the posterior mediastinum

Address for correspondence: S. Wójcik, MD, PhD, Department of Anatomy and Neurobiology, Medical University of Gdańsk, Dębinki 1, 80–211 Gdańsk, Poland, tel: +48 58 349 14 02, e-mail: [swoj@amg.gda.pl](mailto:swoj@amg.gda.pl)

along the right side of the vertebral column, where it receives its major tributaries. At the level of the fourth thoracic vertebra it arches over the root of the right lung to end in the superior vena cava. The azygos vein drains the right posterior thoracic wall directly, receiving the right subcostal and posterior intercostal veins.

On the left side the upper three or four posterior intercostal veins fall into the left superior intercostal vein, which drains directly into the left brachiocephalic vein.

The accessory hemiazygos vein, if present, drains three or four further left posterior intercostal veins and usually drains into the left superior intercostal vein. The hemiazygos vein arises from the left ascending lumbar vein, occasionally joined by an additional root from the left renal vein. It drains the four or five lowest left posterior intercostal veins as well as the left subcostal vein and, sometimes, the accessory hemiazygos vein. After passing dorsally to the aorta, the hemiazygos vein opens into the azygos vein on the right side of the vertebral column.

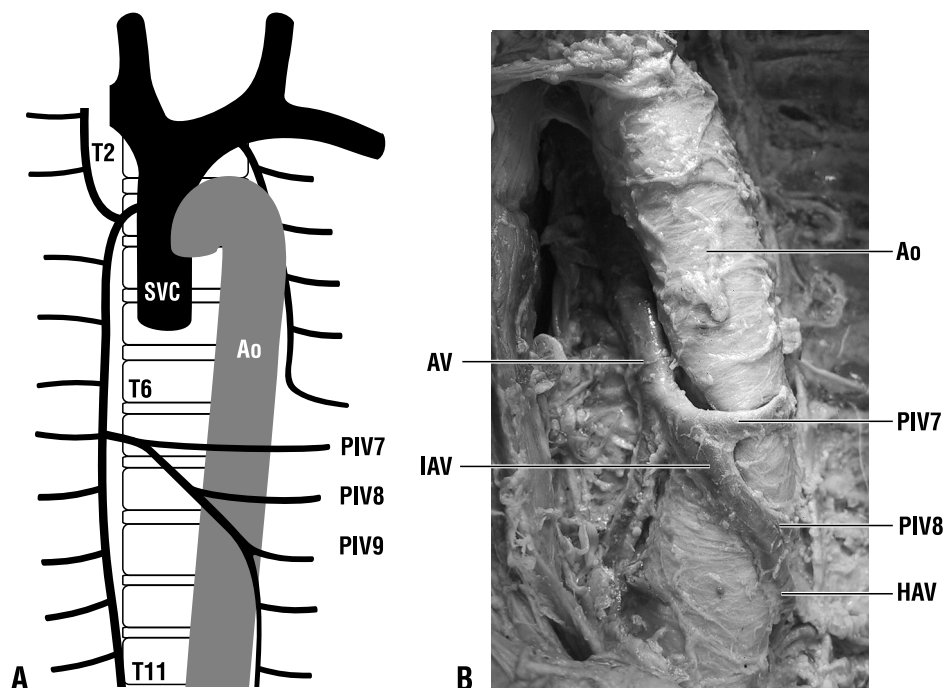
Variation in the azygos venous system has been reported [4, 6, 11]. The most common variants include left posterior intercostal veins or the accessory hemiazygos vein joining the azygos vein independently of the hemiazygos vein and anastomoses between

the accessory hemiazygos and the hemiazygos vein. A very rare abnormality, yet of significant clinical importance, is the presence of a communication between the hemiazygos or accessory hemiazygos and the azygos vein — an “interazygos vein,” passing ventrally to the aorta [12], cited after Gilkeson et al. [3].

### CASE REPORT

During a dissection of 12 cadavers we encountered significant abnormalities in the azygos venous system in a 76 year old Caucasian male cadaver. The results are illustrated in Figure 1.

The interazygos vein, passing ventrally to the aorta on the level of the T8/T9 intervertebral disc, was found to be the direct continuation of the hemiazygos vein, which drained the 9<sup>th</sup> to the 11<sup>th</sup> left posterior intercostal veins. On the ventral aspect of the aorta the interazygos vein received tributary from two independent vessels, found to be the continuations of the 8<sup>th</sup> and the 7<sup>th</sup> left posterior intercostal veins respectively. The common trunk passed the aorta obliquely and opened into the azygos vein on the level of the body of the 7<sup>th</sup> thoracic vertebra. The accessory hemiazygos vein drained into the left superior intercostal vein. We did not find any anastomoses between the hemiazygos vein and the accessory hemiazygos vein, nor did we find any



**Figure 1.** (A) Scheme and (B) photograph presenting the variant of the azygos venous system; Ao — descending aorta; AV — azygos vein; IAV — interazygos vein; HAV — hemiazygos vein; PIV 7 — 7<sup>th</sup> left posterior intercostal vein; PIV8 — 8<sup>th</sup> left posterior intercostal vein; PIV9 — 9<sup>th</sup> left posterior intercostal vein; SVC — superior vena cava; T2, T6, T11 — thoracic vertebrae 2, 6, 11.

abnormalities in the right part of the azygos venous system. The azygos vein followed its regular course and opened into the superior vena cava. All the remaining structures in the posterior mediastinum of the cadaver were normal.

## DISCUSSION

The occurrence of variations in the azygos venous system is fairly common and there are many possible variants. One study, based on over 60 bodies, demonstrated that such abnormalities are found in about 25% cases [4]. It appears, however, that a venous vessel passing ventrally to the aorta is a rare finding. Such anomalies are considered to originate during embryological development from abnormal connections between the left intersegmental veins and the right venous line without the usual involvement of retroaortic subcentral veins [2]. Early studies estimated the frequency of preaortic connections to be 2.5% [1] and 3.6% [11]. Several recent reports have demonstrated variable courses of the azygos venous system components with multiple anastomoses, including preaortic "interazygos veins" [2, 9, 10].

Since the posterior mediastinum is a common site of surgical intervention, accidental manipulation of an interazygos vein may lead to intraoperative bleeding. Because of the apparent absence of the commonly found hemiazygos — accessory hemiazygos anastomosis [4], the "interazygos vein" we identified appears to be the most important vessel directly draining the 7<sup>th</sup> to 11<sup>th</sup> left posterior intercostal spaces. This also contrasts our findings with the results of other reports, in which either anastomoses with the accessory interazygos vein were present [1, 8], or the interazygos vein was additionally accompanied by retroaortic anastomoses [1, 7–10].

In our study we identified as many as three vessels joining the ventral aspect of the aorta: a dilated vessel, which was the continuation of the hemiazygos vein, receiving tributaries from the 8<sup>th</sup> and 7<sup>th</sup> left posterior intercostal veins. As already mentioned, the oblique course and unusual localisation of these para-aortic vessels makes them easy to mistake for enlarged lymph nodes in CT images [13]. The results of our study may therefore help explain unusual radiographic findings like those described by Gilkeson et al. [3], in which CT imaging of a female patient suffering from breast cancer revealed an anomalous

azygos-hemiazygos anastomosis similar to the interazygos vein described in our study, which mimicked a para-aortic mass.

Our study demonstrates that awareness of the rare possible anatomical variants in the highly variable azygos venous system may be of importance in many clinical situations.

## ACKNOWLEDGEMENTS

The authors wish to thank to Ms Sylwia Scisłowska, MA, for the preparation of illustrations. This research was supported by funds from the Ministry of Science and Higher Education, Grant ST-11.

## REFERENCES

1. Butler H, Balankura K (1952) Preaortic thoracic duct and azygos veins. *Anat Rec*, 113: 409–419.
2. Das S, Paul S (2004) Preaortic interazygos vein: a case report. *Braz J Morphol Sci*, 21: 141–143.
3. Gilkeson RC, Goodman PC, McAdams HP (1997) Anomalous azygos-hemiazygos anastomosis: radiographic findings. *Am J Roentgenol*, 168: 285–286.
4. Grzybiak M, Szostakiewicz-Sawicka H, Treder A (1975) Remarks on pathways of venous drainage from the left upper intercostal spaces in man. *Folia Morphol*, 34: 301–313.
5. Ibukuro K, Tsukiyama T, Mori K, Inoue Y (1998) Preaortic esophageal veins: CT appearance. *Am J Roentgenol*, 170: 1535–1538.
6. Krakowiak-Sarnowska E, Wisniewski M, Szpinda M, Krakowiak H (2003) Variability of the azygos vein system in human fetuses. *Folia Morphol*, 62: 427–430.
7. Lindsay HC (1925) An abnormal vena hemiazygos. *J Anat*, 59: 438.
8. Morton W (1948) Pre-aortic drainage of the hemiazygos veins. Report of two cases. *Anatom Record*, 101: 187–191.
9. Ozbek A, Dalcik C, Colak T, Dalcik H (1999) Multiple variations of the azygos venous system. *Surg Radiol Anat*, 21: 83–85.
10. Ozdemir B, Aldur MM, Celik HH (2002) Multiple variations in the azygos venous system: a preaortic interazygos vein and the absence of hemiazygos vein. *Surg Radiol Anat*, 24: 68–70.
11. Seib GA (1934) The azygos system of veins in American whites and American negroes, including observations on the inferior caval venous system. *Am J Physical Anthropol*, 19: 39–163.
12. Smathers RL, Lee JK, Heiken JP (1983) Anomalous preaortic interazygos vein. *J Comput Assist Tomogr*, 7: 732–733.
13. Takasugi JE, Godwin JD (1990) CT appearance of the retroaortic anastomoses of the azygos system. *Am J Roentgenol*, 154: 41–44.