

# A case of May-Thurner syndrome

M. Loukas<sup>1</sup>, R. Shah<sup>1</sup>, E. Esmaeili<sup>1</sup>, A. Bangeholm<sup>1</sup>, R.S. Tubbs<sup>2</sup>, R. Jordan<sup>1</sup>

<sup>1</sup>Department of Anatomical Sciences, St. George's University, Grenada, West Indies

<sup>2</sup>Department of Cell Biology and Section of Pediatric Neurosurgery, University of Alabama at Birmingham, Birmingham, AL, USA

[Received 23 December 2007; Accepted 2 May 2008]

*May-Thurner syndrome is a condition that results from narrowing of the left common iliac vein lumen due to pressure from the right common iliac artery as it crosses anterior to it. We describe a very rare case in which a previously asymptomatic patient presented with May-Thurner syndrome. (Folia Morphol 2008; 67: 214–217)*

**Key words: common iliac artery, common iliac vein, May-Thurner syndrome**

## INTRODUCTION

May-Thurner syndrome is a rare vascular constriction that was first described in 1908 by McMurrich [1] and further elaborated on by May and Thurner in 1956 [10]. May-Thurner syndrome is described as compression of the left common iliac vein (LCIV) by the right common iliac artery (RCIA) as it travels from the aortoiliac bifurcation to the right inguinal region [9]. Typically, this crossing over is considered to be anatomically normal. However, in some patients the compression of the vein between the vertebral body posteriorly and the artery anteriorly causes thickening of the inner wall of the vein, leading to intimal hyperplasia and thus to stenosis [10]. This compression may present symptomatically or be an incidental finding. Following the development and widespread use of cross-sectional imaging with computed tomography, compression of the LCIV has become more frequently encountered in asymptomatic patients and is usually readily identifiable with intravenously administered contrast material [7]. While the prevalence of the disorder is unknown, in patients undergoing evaluation for lower extremity venous disorders the condition is found in 2–5% of patients [3] and is most often seen in women between the second and fourth decades of life [5]. Knowledge of

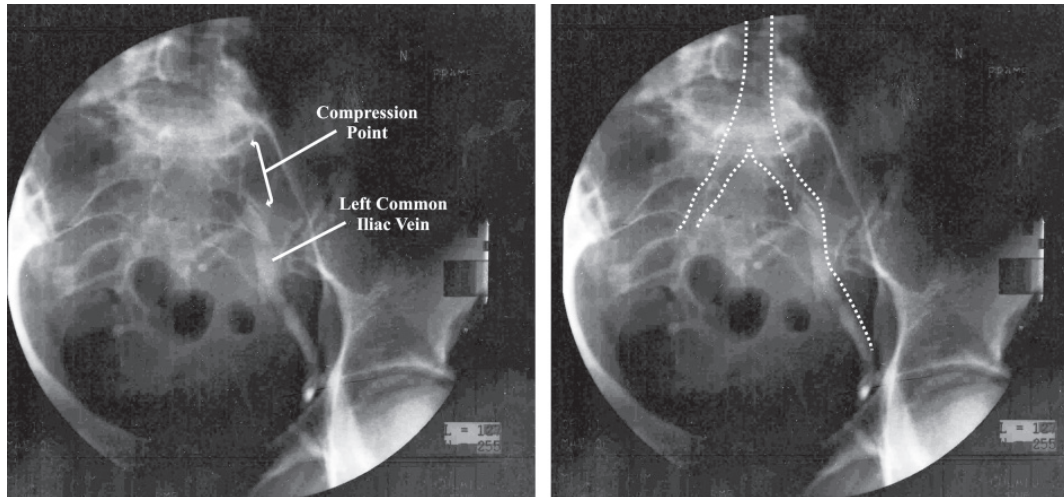
these variations is necessary to avoid misdiagnosis of symptomatic patients. We describe a very rare case in which a previously asymptomatic patient presented with May-Thurner syndrome.

## CASE REPORT

A 35-year-old Caucasian female with no prior illness other than hypertension was scheduled for hysterectomy to remove multiple uterine fibroids. Three days before the scheduled operation the patient was admitted to the Emergency Room complaining of severe lower left leg pain and swelling.

Physical examination revealed a painful left calf and swelling of the lower extremity over 48 hours. The patient's height and weight were 162 cm and 51 kg respectively. The left calf was measured at 15 inches and the right calf at 14 inches. The swelling extended distally from the left knee to the ankle. There was marked tenderness with palpation of the left calf. A blood pressure cuff was applied to both legs up to 160 mm Hg. There was no discomfort on the right side but marked discomfort in the left lower extremity. Pulses were intact and equal to those of the lower extremities. No varicose veins were evident but venous insufficiency was noted.

Address for correspondence: Dr. M. Loukas, MD, PhD, Ass. Prof., Department of Anatomical Sciences, St. George's University, School of Medicine, Grenada, West Indies, tel: 473 444 4175 x2556, fax: 473 444 2887, e-mail: edsg2000@yahoo.com, mloukas@sgu.edu



**Figure 1.** A left iliac vein venogram. Note the compression point at which the left iliac vein is not filled with contrast medium. In the same figure the shadow of the vein has been outlined with a dotted line.

Computed tomography of the pelvis and lower limb was performed and large fibroids of the uterus were noticed. Ultrasonographic examination was performed and was negative for deep vein thrombosis. In addition, an ascending venogram was performed and complete occlusion of the central portion of the left common iliac vein was noted as a result of compression from the overlying left common iliac artery. Measurements obtained with the patient in the supine position revealed a 6-mm Hg pressure gradient across the stenosis. The mean diameter at the origin of the left common iliac vein was 3.2 mm, whereas the mean diameter of the right common iliac vein at the same level was 11.9 mm. The mean percentage stenosis of the left common iliac vein due to compression by the right common iliac artery was 70% (Fig. 1). The mean distance from the posterior border of the right common iliac artery to the nearest lumbar vertebra was 4.5 mm. The femoral vein was grossly patent and duplicated. The clinical history and imaging findings were diagnostic for May-Thurner syndrome, although we were unable to detect the presence or absence of intimal hypertrophy.

After the occluded vein had been identified, a guide wire and a catheter were inserted into the left common iliac vein. A percutaneous transluminal angioplasty of the left common iliac vein and external iliac vein was performed with a  $10 \times 4 \times 80$  Cordis balloon. Furthermore, an endovascular tandem stent ( $10 \times 40$  SMART), was placed into the left common and external iliac veins. The patient tolerated the procedure well and no immedi-

ate symptomatic complications were noticed. The patient was discharged the same day. The patient indicated that she had had a laparoscopy ten years previously and that she suffered from chronic hypertension. She is currently on a diuretic (Lasix) and low molecular weight heparin (Lovenox).

## DISCUSSION

In 1957 May and Thurner examined 430 cadavers and documented the decrease in venous flow that resulted from intimal change in the LCIV. Since then the syndrome has been variously termed May-Thurner syndrome, iliac vein compression syndrome, Cockett syndrome or iliocaval compression syndrome [5, 10, 18].

The syndrome may present clinically as left lower extremity edema, varicosities, venous stasis changes, venous claudication, pain or venous ulceration. Some cases have been described where the syndrome is found in adolescent-aged females [15]. However, the majority of the cases are in women between the second and fourth decades of life [5].

Recent imaging data indicate that compression of the LCIV at the arterial crossover point may be present in 66% of the general population without any venous symptoms [7]. Intraluminally, the mean luminal stenosis of the LCIV due to compression by the artery has been reported to be as high as 68% [12]. Patients who are within this age group and present with a history of persistent left lower extremity swelling with or without deep vein thrombosis with no other obvious causes should have May-Thurner syndrome excluded.

The study of choice has typically been contrast venography, which shows compressions of the iliac vein with spur. Intravenous ultrasound has also been used in diagnosis. According to the literature, venography is less sensitive than IVUS at 66% and 90%, respectively [16]. Once the condition has been identified, traditional therapy involves anticoagulation or surgical correction of the vein compression, either by a vein patch repair or by a venous crossover bypass graft. More recently, interventional radiological techniques such as intraluminal stent placement have been used [11].

Anticoagulation therapy in symptomatic patients as a sole treatment has not been very effective. It has prevented migration of the thrombi, although without managing or reducing the mechanical obstruction caused by the intimal hyperplasia. Recent treatment utilizing intraluminal venous stents has been associated with greater success, as it deals with thrombus formation and the mechanical obstruction [6, 8, 13, 14].

Anatomically, the point of origin of the common iliac arteries varies according to the level of aortic bifurcation. The abdominal aorta bifurcates into right and left common iliac arteries anterolateral to the fourth lumbar vertebral body or upon the disc between the fourth and the fifth in 75% of cases [4]. The arteries continue to diverge as they descend to divide at the level of the sacroiliac joint into external and internal iliac arteries. The length of the individual arteries also varies. The common iliac artery can be as short as 1.2 cm or as long as 11 cm. The usual length is 3.5–7.5 cm in 72% of cases. Of the remaining 28%, 14% were shorter than 3.5 cm and 14% were longer than 7.5 cm [2, 4].

The common iliac veins are formed by the union of the external and internal iliac veins anterior to the sacroiliac joint, ascending obliquely to end on the right side of the 5<sup>th</sup> lumbar vertebra, uniting at an acute angle with the contralateral vessel to form the inferior vena cava. The left common iliac vein is longer than right common iliac vein and more oblique. It lies first medial then posterior to the right common iliac artery [4]. The left common iliac vein receives the iliolumbar, lateral sacral and median sacral veins as tributaries. No valves are found in these veins [17]. It has been reported that lower extremity deep venous thrombosis occurs three to eight times more frequently on the left than on the right side [14]. With venous compression occurring in May-Thurner syndrome, the incidence of thrombi formation grows.

Owing to the impendence of blood flow from the stenosis, collateral pathways are utilized. Thomas et al. described these collaterals and classified them into three groups according to the site of the blockage: the external iliac vein (group 1), the common iliac vein (group 2) and both the common and the external iliac veins (group 3) [19]. They observed that all the collateral veins were normal channels but were enlarged by the increased blood flow. In some instances they carried the blood in the reverse direction. In the specific case of the common iliac vein being obstructed, as in our case, the collateral veins run from the internal iliac vein on the side of obstruction through the parametrial and pre-sacral plexuses to the opposite internal iliac vein, and frequently through the ascending lumbar vein on the side of the obstruction. Occasionally the ovarian veins and internal and external vertebral plexuses act as collaterals [19].

This specific vascular malformation may come to clinical attention in the symptomatic patient, but it would be interesting to study whether the syndrome is acquired or congenital. If congenital, early signs might be seen in children. This case report indicates the potential and the need for continued exploration of this region of the human body.

## REFERENCES

1. Ahmed H, Hagspiel K (2001) Intravascular ultrasonographic findings in May-Thurner syndrome (iliac vein compression syndrome). *J Ultrasound Med*, 20: 251–256.
2. Bergman R (1988) *Compendium of human anatomic variations. Cardiovascular system*. Urban & Schwarzenberg, Baltimore, pp. 84, 92.
3. Billakanty S, Burket M, Grubb B (2006) May-Thurner syndrome: a vascular abnormality encountered during electrophysiologic study. *PACE*, 29: 1310–1311.
4. Clemente C (1985) *Gray's anatomy*. Chapter 8. The arteries. 30<sup>th</sup> ed. Lea & Febiger, Philadelphia, pp. 748–760.
5. Cockett FB, Thomas ML (1965) The iliac compression syndrome. *Br J Surg*, 52: 816–821.
6. Grunwald M, Goldberg M, Hoffman L (2004) Endovascular management of May-Thurner syndrome. *AJR*, 183: 1523–1524.
7. Kibbe M, Ujiki M, Goodwin A, Eskandari M, Yao J, Matsumura J (2004) Iliac vein compression in an asymptomatic patient population. *J Vasc Surg*, 39: 937–943.
8. Lamont JP, Pearl GJ, Patetsios P, Warner MT, Gable DR, Garrett W, Grimsley B, Smith BL, Shutze WP (2002) Prospective evaluation of endoluminal venous stents in the treatment of the May-Thurner syndrome. *Ann Vasc Surg*, 16: 61–64.
9. Liu J, Bonn J, Needleman L, Chiou HJ, Gardiner GA Jr, Goldberg BB (1999) Feasibility of three-dimensional intravascular ultrasonography: preliminary clinical studies. *J Ultrasound Med*, 18: 489–495.

10. May R, Thurner J (1957) The cause of the predominantly sinistral occurrence of thrombosis of the pelvic veins. *Angiology*, 8: 419–427.
11. Oderich G, Treiman G, Schneider P, Bhirangi K (2000) Stent placement for treatment of central and peripheral venous obstruction: a long-term multi-institutional experience. *J Vasc Surg*, 32: 760–769.
12. Oguzkurt L, Tercan F, Pourbagher M, Kizilkilic O, Turkoz R, Boyvat F (2005) Computed tomography findings in 10 cases of iliac vein compression (May-Thurner) syndrome. *Eur J Radiol*, 55: 421–425.
13. O'Sullivan GJ, Semba CP, Bittner CA, Kee ST, Razavi MK, Sze DY, Dake MD (2000) Endovascular management of iliac vein compression syndrome. *J Vasc Interv Radiol*, 11: 823–836.
14. Patel NH, Stookey KR, Ketcham DB, Cragg AH (2000) Endovascular management of acute extensive iliofemoral deep venous thrombosis caused by May-Thurner syndrome. *J Vasc Interv Radiol*, 11: 1297–1302.
15. Raffini L, Raybagkar D, Cahill A, Kaye R, Blumenstein M, Manno C (2006) May-Thurner syndrome (iliac vein compression) and thrombosis in adolescents. *Pediatr Blood Cancer*, 47: 834–838.
16. Raju S, Neglen P (2006) High prevalence of nonthrombotic iliac vein lesions in chronic venous disease: a permissive role in pathogenicity. *J Vasc Surg*, 44: 136–143.
17. Standring S (2005) *Gray's anatomy*. Chapter 108. True pelvis, pelvic floor and perineum. 39<sup>th</sup> ed. Elsevier, Churchill, Livingstone, Edinburgh, pp. 1360–1363.
18. Taheri SA, Williams J, Powell S, Cullen J, Peer R, Nowakowski P, Boman L, Pisano S (1987) Iliocaval compression syndrome. *Am J Surg*, 154: 169–172.
19. Thomas M, Fletcher W, Cockett, Negus D (1967) Venous collaterals in external and common iliac vein obstruction. *Clin Radiol*, 18: 403–411.