

# Transverse subisthmic course of the innominate artery in an adult: detailed anatomy and additional variation

M.C. Rusu<sup>1</sup>, A.L. Boşcu<sup>2</sup>

<sup>1</sup>Faculty of Dental Medicine, University of Medicine and Pharmacy “Carol Davila”, Bucharest, Romania

<sup>2</sup>Faculty of Medicine, University of Medicine and Pharmacy “Victor Babeş”, Timișoara, Romania

[Received 10 June 2010; Accepted 16 July 2010]

*A rare morphology of an aberrant innominate artery (IA) is reported here, together with additional arterial variation encountered in the respective specimen. The IA originated in the aortic arch on the left side of the trachea, coursed on that side of the trachea to reach the left thyroid lobe, turned in at a right angle to pass anterior to the trachea and immediately inferior and parallel to the thyroid isthmus, and finally it divided inferior to the right thyroid lobe into the right subclavian and common carotid arteries. The right common carotid artery immediately turned at a right angle to ascend in the neck. Thus the terminal branches of the IA had origins in a higher position than is usually expected. This aberrant course of the IA determined a step-like morphology in the sagittal plane of the left common carotid artery. Additional variations were also encountered: (a) a lateralised right external carotid artery with the superior thyroid artery initially coursing over the internal carotid artery; (b) the right vertebral artery coursing over the inferior thyroid artery and entering the transverse process of the fifth cervical vertebra; (c) the left subclavian and vertebral arteries were tortuous. Knowledge of the presence of this IA variant, with a transverse subisthmic segment, appears to be important in various surgical approaches, such as tracheostomies, thyroidectomies, and mediastinoscopies; in addition, the variations of the IA and the vertebral arteries are relevant for lower cervical spine approaches. Nevertheless, the lateralised external carotid artery may lead, if unidentified, to hemorrhagic complications during carotid space approaches. It is important for surgeons to be aware that if an aberrant IA is identified it may not be the only variation in that patient. (Folia Morphol 2010; 69, 4: 261–266)*

**Key words:** trachea, thyroid gland, carotid artery, vertebral artery, brachiocephalic trunk

## INTRODUCTION

Usually the brachiocephalic trunk arises from the aortic arch in the upper mediastinum and ascends obliquely to divide at the level of the right sternoclavicular joint into the right common carotid and subclavian arteries. Aberrant/anomalous courses of

this trunk over the trachea can lead to compression syndromes, especially important in paediatric patients; reimplantation of the artery eliminates the anatomic cause of tracheal compression [7].

Although Nomina Anatomica uses the term “brachiocephalic trunk” for the right branch of the aor-

tic arch, the overwhelming majority of literature continues to refer to the vessel as the innominate artery (IA), and the respiratory compromise due to tracheal compression by the brachiocephalic trunk is referred as innominate artery compression syndrome [6]. The usual terms shall be used in the present report.

The anatomy of aortic great vessels is relevant in surgeries of the anterior neck, especially with tracheostomy, thyroidectomy, or mediastinoscopy. Variations in their anatomy can lead to severe complications if not recognised [12].

High localisation of an aberrant innominate artery in the neck is a rare anomaly that increases major complication rate and mortality, particularly during percutaneous procedures in the neck, such as the percutaneous technique for tracheostomy [3]. Even though there are several reports dealing with highly located aberrant IAs that interfere with the tracheostomy procedure, only one resulted from an anatomical study by dissection, the other three being computed tomography studies [8, 9]. The anatomical report under discussion here does not provide details on eventual additional variations on the side with the aberrant IA.

The human arterial system of the head, neck, and upper thoracic regions arises from a series of aortic arches — involution of some pairs and further development of others produce the characteristic morphology and asymmetry of the human arterial system, and variations in the branches of the arch of the aorta are thus likely to occur as a result of the altered development of certain aortic arches [1].

## MATERIAL AND METHODS

The present set of anatomical variations was recorded in an adult female cadaver (aged 65 years) dissection which was initiated at the level of the infrahyoid region.

The stages of the dissection are presented in the Results section. The detailed anatomy of the complex variational picture was documented by microdissection at 4.5 × magnification.

## RESULTS

### First stage of dissection — subisthmic dissection at the level of the cervical trachea

After evidencing the pretracheal layer and bilaterally dissecting the strap muscles, the isthmus of the thyroid gland was evidenced inferior to the cricoid cartilage and in front of the second tracheal ring.

Then the subisthmic region was approached and dissected superficially (Fig. 1A) after the en-block removal of the upper part of the sternal manubrium and the sternoclavicular joints:

- the inferior thyroid veins were isolated and followed to the level of the sternoclavicular joints;
- pretracheal lymph nodes and vessels were evidenced at the lower border of the thyroid isthmus;
- superficial branches of the inferior thyroid arteries were evidenced descending and branching at the level of the thymic fat that was consistent above the sternal manubrium;
- at 1 cm inferior to the thyroid isthmus an unexpected structure was encountered when the tracheal approach was attempted — it further proved to be the cervical segment of an aberrant brachiocephalic trunk (innominate artery, IA), coursing transversally at the inferior border of the thyroid isthmus and not obliquely as one would usually expect.

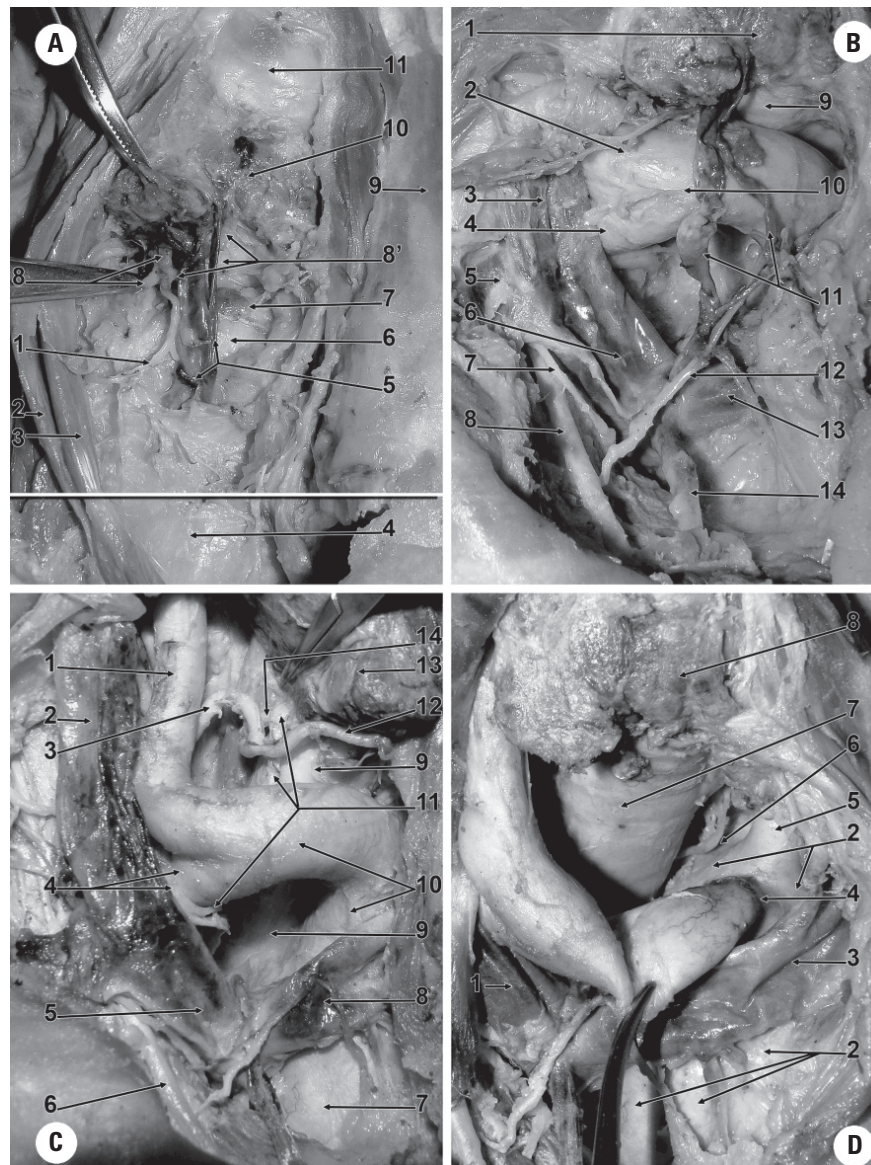
### Second stage of dissection — pretracheal dissection below the transverse segment of the aberrant innominate artery

After identifying the IA variant, the trunk was followed distally to the right: it bifurcated immediately inferior to the lower pole of the right thyroid lobe into the right subclavian artery (RSA) and the right common carotid artery (RCCA) (Fig. 1B). Then the pretracheal dissection was continued to mediastinum, and thymic branches of the right internal thoracic artery were also identified in the superficial layer of the thymic fat, crossing over the left brachiocephalic vein (left innominate vein) and the inferior thyroid veins draining in it (Fig. 1B).

### Third stage of dissection — complete identification of the aberrant innominate artery (Fig. 1C, D)

The identified aberrant IA had a single-step morphology, ascending vertically antero-laterally to the left side of the trachea and then turning right at ninety degrees to continue transversally and divide in this transversal plane, inferior to the thyroid isthmus. Subsequently, the RCCA, with an initial horizontal (left-to-right) segment, turned upwards (the second right angle) to ascend in the neck.

The origin of the IA was from the aortic arch, antero-lateral on the left side of the trachea, proximal and adjacent to the aortic origin of the left common carotid artery (LCCA) (Fig. 1D).

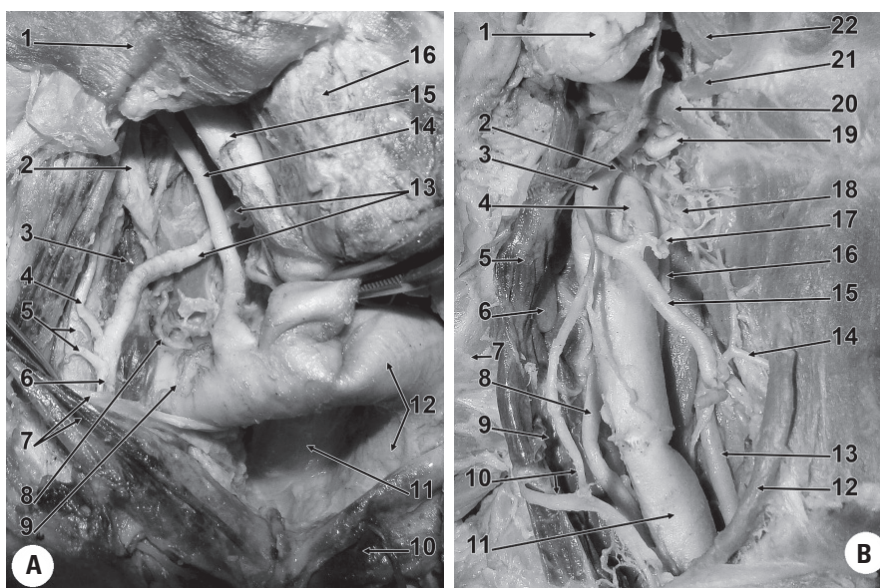


**Figure 1.** Peritracheal course and relations of the brachiocephalic trunk (IA — innominate artery). **A.** Dissection of the subisthmic segment of the IA, anterior view (the horizontal white line marks the level of the sternoclavicular joints): 1. thymic artery, derived from the inferior thyroid artery; 2. sternohyoid muscle; 3. sternothyroid muscle; 4. thymic fat; 5. inferior thyroid veins; 6. transverse subisthmic segment of the IA; 7. subisthmic pretracheal lymph node, applied on the IA; 8. isthmic branch derived from the medial branch of the inferior thyroid artery; 9. left sternocleidomastoid muscle; 10. isthmus of the thyroid gland; 11. cricoid cartilage; **B.** The terminal end of the IA, right antero-infero-lateral view: 1. isthmus of the thyroid gland; 2. right common carotid artery (RCCA); 3. internal jugular vein (IJV); 4. right subclavian artery (RSA); 5. subclavian vein; 6. right brachiocephalic (innominate) vein (RIV); 7. right phrenic nerve; 8. right internal thoracic (mammary) artery; 9. trachea; 10. terminal end of the IA; 11. inferior thyroid veins; 12. thymic branch of the right internal thoracic (mammary) artery; 13. left brachiocephalic (innominate) vein (LIV); 14. right internal thoracic (mammary) vein; **C.** The IA-to-RCCA angle, right antero-infero-lateral view: 1. RCCA; 2. IJV; 3. inferior thyroid artery; 4. RSA, right vagus nerve; 5. RIV; 6. right internal thoracic (mammary) artery; 7. aortic arch; 8. LIV; 9. trachea; 10. IA; 11. right recurrent laryngeal nerve; 12. medial branch of the inferior thyroid artery; 13. right thyroid lobe; 14. posterior branch of the inferior thyroid artery; **D.** Origin of the IA, right antero-supero-lateral view: 1. RIV; 2. aortic arch; 3. LIV; 4. origin of the IA; 5. left common carotid artery; 6. left recurrent laryngeal nerve; 7. trachea; 8. isthmus of the thyroid gland.

Consequently, two segments of the IA could be defined:

- the first, vertical segment coursed ascendant on the anterior left side of the trachea, from mediastinum to neck, until it reached the left thyroid

lobe; it was anterior to the left recurrent laryngeal nerve and antero-medial to the LCCA. As determined by that course, the corresponding segment of the LCCA was displaced posteriorly, and it only repositioned distally to the IA in an



**Figure 2. A.** Branches of right subclavian artery (RSA) in the scaleno-vertebral triangle, right antero-inferior view: 1. sternothyroid muscle, reflected; 2. middle cervical ganglion; 3. vertebral vein; 4. ascending cervical artery; 5. transverse cervical artery; 6. thyrocervical trunk; 7. internal jugular vein (IJV), right vagus nerve, reflected; 8. costocervical trunk; 9. RSA; 10. left brachiocephalic (innominate) vein; 11. trachea; 12. innominate artery; 13. right inferior thyroid artery; 14. vertebral artery; 15. right common carotid artery (RCCA); 16. right thyroid lobe; **B.** Dissection of the carotid triangle, lateralisation of the right external carotid artery (RECA), anterior view: 1. submandibular gland; 2. origin of the lingual artery; 3. RECA; 4. right internal carotid artery; 5. common facial vein; 6. deep lymph node, of the jugular chain; 7. sternocleidomastoid muscle, reflected; 8. vagus nerve; 9. IJV; 10. ansa cervicalis (hypoglossi); 11. RCCA; 12. superior belly of the omohyoid muscle; 13. vertebral artery; 14. cricothyroid artery; 15. superior thyroid artery; 16. sympathetic trunk; 17. superior laryngeal artery; 18. internal branch of the superior laryngeal nerve; 19. hypoglossal nerve; 20. stylohyoid muscle; 21. intermediate tendon of the digastric muscle; 22. mylohyoid muscle.

anterior plane, thus displaying a step-like morphology in the sagittal plane; on the left side tortuous subclavian and vertebral arteries were also identified;

- the second, cervical, pretracheal, subisthmic, horizontal segment had a left-to-right course in front of the fourth tracheal ring while the terminal division was in a high location below the right thyroid lobe and above the right sternoclavicular joint. The end of the IA and the initial segment of the RCCA were crossed posterior by the right recurrent laryngeal nerve that, above the two arteries, continued between the posterior and medial terminal branches of the inferior thyroid artery, deep to the right thyroid lobe (Fig. 1C).

**Fourth stage of dissection — the right scaleno-vertebral triangle**

Dissection was continued in order to evaluate the RSA branches in the scaleno-vertebral triangle (Fig. 2A). The following results were recorded:

- the prescalenic part of the RSA adopted a postero-lateral course towards the medial border of the anterior scalene muscle;

- the prescalenic portion of the RSA was crossed anteriorly by the internal jugular vein and the vagus nerve; at the lower border of the RSA the recurrent nerve left the vagus nerve and coursed initially posterior to the origin of the RSA;
- from the initial part of the antero-superior aspect of the RSA emerged the vertebral artery (VA), initially dilated; the VA ascended and slightly inclined posteriorly, behind the carotid sheath (postero-medial to the RCCA) and crossed anteriorly, and not posteriorly as was expected, to the inferior thyroid artery, anterior to the lateral border of the longus colli muscle. As related to the sympathetic trunk (covered by the prevertebral fascia), the VA was antero-medial and continued as such to reach the carotid space where it entered the transverse foramen of the fifth cervical vertebra (Fig. 2B); below the transverse process of the sixth cervical vertebra on the course of the sympathetic trunk a large middle cervical ganglion was identified;
- the vertebral vein exited the transverse foramen of the sixth cervical vertebra and initially coursed posteriorly to the middle cervical ganglion to continue anterior to the lower part of the cervical sym-

pathetic trunk and the inferior cervical ganglion; a deep communicating branch emerged from the lower pole of the middle cervical ganglion coursed on the antero-medial side of the vertebral vein to enter the transverse foramen of the sixth cervical vertebra. The vertebral vein further continued anterior to the prescalenic RSA to drain on the posterior side of the origin of the right brachiocephalic vein (right innominate vein);

- from the postero-superior aspect of the RSA emerged, distally to the VA, a thin costocervical trunk that coursed postero-superiorly, reached the postero-medial side of the vertebral vein, traversed through the sympathetic trunk, and then divided into two branches;
- the thyrocervical trunk of the RSA emerged at the medial border of the tendon of the anterior scalene muscle, lateral to the vertebral vein; from that trunk, the transverse cervical artery (the suprascapular was missing), the cervical ascending artery, and the inferior thyroid artery had origins. Notably, the trunk:
  - first ascended at the medial border of the anterior scalene muscle;
  - then it crossed obliquely supero-medially over the vertebral vein and the sympathetic trunk and continued on that course posteriorly crossing the VA and the RCCA (carotid sheath) to reach deep to the right thyroid lobe;
  - it then turned downwards and divided into posterior and medial glandular branches (Fig. 1C).

#### **Fifth stage of dissection — the lateralised external carotid artery**

The dissection was continued at the level of the carotid triangle, where the lateralised position of the external carotid artery (ECA), as referred to the internal carotid artery (ICA), was noticed (Fig. 2B):

- the initial segment of the ECA was placed postero-laterally to the corresponding segment of the ICA. It then continued over the ICA, covering it laterally, and both entered deep to the digastric and stylohyoid muscles;
- due to the topography, the right superior thyroid artery had an initial course over the ICA, level where it sent off the superior laryngeal artery;
- also the origin but not the initial trunk of the lingual artery had an anterior situation to the ICA.

## **DISCUSSION**

An anomalous innominate artery crossing the trachea anteriorly below the thyroid gland is ex-

tremely rare [3] and adds to the common anatomical causes for bleeding during subisthmic tracheostomy; the risk of major bleeding from a transverse subisthmic IA can be minimised if the surgeons are aware of this rare but possible variation and check for the presence of pulsations anterior to the cervical trachea [3]. A comparable step-like morphology, such as the one presented here, was reported in a case with a pretracheal RCCA; in that case the right subclavian artery coursed posterior to the oesophagus [4].

Several details should be discussed here:

- the direct relation of the transverse segment of such an aberrant IA with the lymph nodes may lead to, if adenopathy is present, pulsatile masses in the infrahyoid neck, which, when observed, may help in the diagnosis of the vascular variant;
- deep to the pretracheal fascial layer a *vascular layer* covers the transverse segment of the aberrant IA, consisting of the inferior thyroid veins and thymic branches of the inferior thyroid arteries; during surgical approaches at such a level these thin vessels have to be approached with caution in order to identify whether or not an IA courses over the cervical trachea;

Such an aberrant morphology and course of the IA determines its *bilateral relations with the recurrent nerves*: the left one ascending posterior to the vertical segment of the IA while the right one courses posterior to the end of its transverse segment. As such, the surgical approaches that deal with the recurrent nerves, such as the anterior approach to the lower cervical spine [5], may determine catastrophic haemorrhage if such aberrant IA is not identified prior to the intervention.

When surgery at the level of the lower neck is performed it is mandatory for the practitioners to be aware that, if such aberrant IA is identified, it may not be the only variation in the patient.

As in the case reported here, morphologic and topographic variation of the VA may also be encountered, determined, or not, by the altered course of the RSA. The scalenovertebral triangle corresponds to the topographic triangle of the vertebral artery where the ganglionated sympathetic chain and certain spinal nerves can be approached [11]; in the case reported here the following differences to anatomical features considered as normal were recorded:

- the prevertebral segment of the VA appeared longer, continued from the VA triangle to the carotid space, where it entered the transverse foramen of the fifth cervical vertebra; its dilated initial segment appeared, to us, to be a developmental anomaly rather than an aneurismal dilatation;

- the inferior thyroid artery passed posterior to the VA and not between the VA and the RCCA;
- the costocervical trunk emerged from the RSA before the thyrocervical trunk and coursed through the sympathetic chain;
- the vertebral vein coursed through the transverse process of the sixth cervical vertebra alone and not with the VA.

As such, the altered topography within the scaleno-vertebral triangle may put the neurovascular structures at risk during various surgical approaches such as the anterolateral approach to the lower cervical spine [2].

Nevertheless, a lateralised ECA, as encountered here, must be borne in mind when performing arterial ligatures in the carotid triangle, to avoid damage to the internal carotid artery or haemorrhagic accidents [10].

## REFERENCES

1. Bhatia K, Ghabriel MN, Henneberg M (2005) Anatomical variations in the branches of the human aortic arch: a recent study of a South Australian population. *Folia Morphol*, 64: 217–223.
2. Civelek E, Karasu A, Cansever T, Heggul K, Kiris T, Sabanci A, Canbolat A (2008) Surgical anatomy of the cervical sympathetic trunk during anterolateral approach to cervical spine. *Eur Spine J*, 17: 991–995.
3. Comert A, Comert E, Ozlugedik S, Kendir S, Tekdemir I (2004) High-located aberrant innominate artery: an unusual cause of serious hemorrhage of percutaneous tracheotomy. *Am J Otolaryngol*, 25: 368–369.
4. Conoyer BM, Varvares MA, Cooper MH (2008) Right common carotid artery crossing the midline neck anterior to the trachea: a cadaver case report. *Head Neck*, 30: 1253–1256.
5. Ebraheim NA, Lu J, Skie M, Heck BE, Yeasting RA (1997) Vulnerability of the recurrent laryngeal nerve in the anterior approach to the lower cervical spine. *Spine*, 22: 2664–2667.
6. Fawcett SL, Gomez AC, Hughes JA, Set P (2010) Anatomical variation in the position of the brachiocephalic trunk (innominate artery) with respect to the trachea: a computed tomography-based study and literature review of innominate artery compression syndrome. *Clin Anat*, 23: 61–69.
7. Hawkins JA, Bailey WW, Clark SM (1992) Innominate artery compression of the trachea. Treatment by reimplantation of the innominate artery. *J Thorac Cardiovasc Surg*, 103: 678–682.
8. Maldjian PD, Saric M, Tsai SC (2007) High brachiocephalic artery: CT appearance and clinical implications. *J Thorac Imag*, 22: 192–194.
9. Mukadam GA, Hoskins E (2002) Aberrant brachiocephalic artery precluding placement of tracheostomy. *Anaesthesia*, 57: 297–298.
10. Rusu MC, Vasilescu A, Nimigean V (2006) A rare anatomic variant: the lateral position of the external carotid artery. *Int J Oral Maxillofac Surg*, 35: 1066–1067.
11. Tubbs RS, Salter EG, Wellons JC 3rd, Blount JP, Oakes WJ (2005) The triangle of the vertebral artery. *Neurosurgery*, 56: 252–255.
12. Upadhyaya PK, Bertellotti R, Laeeq A, Sugimoto J (2008) Beware of the aberrant innominate artery. *Ann Thorac Surg*, 85: 653–654.