

ONLINE FIRST

This is a provisional PDF only. Copyedited and fully formatted version will be made available soon.



ISSN: 0015-5659

e-ISSN: 1644-3284

Long head of biceps brachii tendon and transverse humeral ligament morphometry and their associated pathology

Authors: Raeesa Khan, Kapil Satyapal, Nerissa Naidoo, Lelika Lazarus

DOI: 10.5603/FM.a2019.0075

Article type: ORIGINAL ARTICLES

Submitted: 2019-05-09

Accepted: 2019-07-02

Published online: 2019-07-02

This article has been peer reviewed and published immediately upon acceptance. It is an open access article, which means that it can be downloaded, printed, and distributed freely, provided the work is properly cited.

Articles in "Folia Morphologica" are listed in PubMed.

Long head of biceps brachii tendon and transverse humeral ligament morphometry and their associated pathology

Running title: Long head of biceps brachii tendon and transverse humeral ligament morphometry

R. Khan¹, K.S. Satyapal¹, N. Naidoo², L. Lazarus¹

¹Department of Clinical Anatomy, School of Laboratory Medicine and Medical Sciences, University of Kwa-Zulu Natal, Durban, South Africa

²Department of Basic Medical Sciences, College of Medicine, Mohammed Bin Rashid University of Medicine and Health Sciences, Dubai, United Arab Emirates

Address for correspondence: Dr Nerissa Naidoo, Department of Basic Medical Sciences, Mohammed Bin Rashid University of Medicine and Health Sciences, P. O. Box 505055, Dubai, UAE, tel: 505 864 363, e-mail: Nerissa.naidoo@mbru.ac.ae; Nerissa.naidoo17@gmail.com

Abstract

As a dynamic stabilizer and flexor of the glenohumeral joint (GHJ), the long head of the biceps brachii tendon (LHBBT) is further stabilized by the retinacular activities of the transverse humeral ligament (THL). The aim of this study was to determine the morphometric dimensions of the LHBBT and THL which were obtained from a total of forty cadaveric upper limb specimens (n = 80; Females: 36, Males: 44; Right: 40, Left: 40), were bilaterally dissected and subjected to morphometric evaluation. Results (mm): (i) LHBBT length: 81.99±21.28 Right, 79.73±17.27 Left; 79.82±19.66 Male, 82.14±19.03 Female; (ii) LHBBT width: 4.28±1.31 Right, 4.67±1.43 Left; 4.35±1.17 Male, 4.63±1.60 Female; (iii) THL length: 20.91±5.24 Right, 21.19±6.63 Left; 21.52±5.71 Male, 20.48±5.92 Female; (iv) THL width (mm): 16.65±6.92 Right, 16.63±7.49 Left; 16.83±6.65 Male, 16.40±7.84 Female. With larger LHBBT length observed on the right side and larger LHBBT width observed on

the left side; both parameters appeared to be distinctly longer in female individuals. On the contrary, the THL length and width were evidently greater in male individuals, with larger lengths and widths present on the left and right sides respectively. These findings may contribute to South African literature and to clinical knowledge as these parameters are important in the successful outcomes of tenotomy, tenodesis and shoulder-related procedures.

Key words: long head of biceps brachii tendon, transverse humeral ligament, tendinitis, tenodesis, morphometry

Introduction

The annual report of the National Institute for Occupational Health (NIOH) in South Africa has identified musculoskeletal disorders among the most commonly reported illnesses within the working population (Ross, 2008). Although prevalence of self-reported cases ranges from 16% to 26%, approximately 1% of the adult population consults a medical practitioner on an annual basis with initial complaints of shoulder pain (Brownson *et al.*, 2015). The long head of biceps brachii tendon (LHBBT) together with the transverse humeral ligament (THL) is subject to mechanical stress and has been reported to present with instability of the glenohumeral joint (GHJ) (Werner *et al.*, 2000). The biceps brachii muscle, characterized by the presence of two heads (*viz.* short head and long head), is a powerful supinator and weak elbow flexor (Chauhan *et al.*, 2013). Long head of biceps brachii muscle tendinopathy is common in conjunction with other shoulder pathology *viz.* rotator cuff degeneration (Raney *et al.*, 2017). Furthermore, instability of the LHBBT occurs in approximately 45% of patients with rotator cuff tears (Lafosse *et al.*, 2007). As a common source of anterior shoulder pain, recent studies have placed emphasis on the role of the tendinous long head of this muscle (Ahrens and Boileau, 2007). The LHBBT, which arises from the supraglenoid tubercle, courses intra-articularly for a short distance through the canal formed by the THL antero-superiorly and the bicipital groove (BG) postero-laterally (Standring, 2016). The LHBBT then exits the canal but continues to descend within the BG as it approaches its insertion site at the radial tuberosity (Werner *et al.*, 2000). While the extra-articular portion of the LHBBT is stabilized by the biceps reflection pulley medially, deviations in the depth and morphology of the BG may subject the LHBBT to mechanical stress and consequent instability (Werner *et al.*, 2000). The tendon is reported to have an approximate width of 5mm-6mm and a length of 90mm (Ahrens and Boileau, 2007; Cucca *et*

al., 2010; Joshi *et al.*, 2014). Although the THL contributes to the stability of the LHBBT within the BG and prevents subluxation; sudden abduction and external rotation of the arm forces the LHBBT against the lesser humeral tubercle medially and the THL superiorly thereby displacing the LHBBT (Johnson *et al.*, 2013; Joshi *et al.*, 2014). Moreover, a torn THL may dislodge the LHBBT from the BG or may allow its free movement, eventually leading to biceps tendinitis (Churgay *et al.*, 2009). Literature outlining the anatomy of the THL remains scarce and for this reason, there is a lack of consensus regarding its morphology and morphometry (Clark *et al.*, 1992; Jost *et al.*, 2000; Werner *et al.*, 2000). Therefore, the aim of this study was to determine the morphometric dimensions of the LHBBT and the THL.

Methods and materials

This study comprised of forty cadaveric upper limb specimens (n = 80; Females: 36, Males: 44; Right: 40, Left: 40) obtained from the Discipline of Clinical Anatomy, School of Laboratory Medicine and Medical Sciences, University of KwaZulu-Natal, South Africa. Adherence to institutional policies regarding ethical conduct was maintained (Ethical Clearance Number: BE308/18).

Only adult cadaveric specimens with absence of osteophytic changes and macroscopic pathology and evidence of no previous shoulder surgery were included in this study.

Following standard dissection protocol as outlined in Grant's Dissector by Tank (2013), the parameters pertaining to the LHBBT and THL were bilaterally quantified with a digital caliper (Linear Tools 2012, 0-150mm, LIN 86500963) and in accordance with the methods of Snow *et al.* (2014) and Joshi *et al.* (2014), respectively.

Measurements were recorded as follows:

- a) *Length of THL* (mm) (a): measured from the anterior tip of the THL (medial to subscapularis tendon) to the posterior tip of the THL (between the greater and lesser humeral tubercles) (Figure 1A)
- b) *Width of THL* (mm) (b): measured from the greater tubercle to the lesser tubercle of the proximal humerus (Figure 1A)
- c) *Length of LHBBT* (mm) (c): from point of origin (supraglenoid tubercle) to musculo-tendinous junction (Figure 1B)

d) *Width of LHBBT* (mm) (d): distance between the medial and lateral walls of the BG (Figure 1B)

The statistical analysis was performed using IBM SPSS version 25 (Copyright IBM corporation 1989, 2017, Chicago, Illinois, USA). This included a comparison of the parameters between gender and laterality, Pearson's correlation coefficient test and the multivariate analysis test. P-values less than 0.05 were considered to be statistically significant. The mean values with standard deviations were calculated from the three measurements recorded for each parameter of the THL and LHBBT, with a distinct time interval of approximately fifteen seconds between each measurement. Since only one observer obtained measurements of the LHBBT and THL parameters, intra-observer reliability was determined using the multivariate analysis test of the general linear model (Table 3).

Results

In this study, the mean LHBBT lengths were observed as 81.99 ± 21.28 mm (right) and 79.73 ± 17.27 mm (left) with a p-value of 0.604 recorded for the comparison of the LHBBT length between right and left sides. Male individuals presented with a mean LHBBT length of 79.82 ± 19.66 mm, while the mean LHBBT length in female individuals was recorded as 82.14 ± 19.03 mm with a p-value of 0.594 recorded for comparison of the LHBBT length between male and female individuals (Table 1).

The mean LHBBT widths were found to be 4.28 ± 1.31 mm and 4.67 ± 1.43 mm on the right and left sides, respectively, with a p-value of 0.205 recorded for the comparison of the LHBBT between the right and left sides (Table 1). In addition, the mean LHBBT width was noted as 4.35 ± 1.17 mm in male individuals, while that of female individuals was 4.63 ± 1.60 mm with a p-value of 0.387 recorded for the comparison of the LHBBT width between males and females (Table 1).

The mean THL length was found to be 20.91 ± 5.24 mm and 21.19 ± 6.36 mm on the right and left sides, respectively, with a p-value of 0.832 recorded for the comparison of THL length between the right and left sides; while that of male and female individuals reflected mean values was 21.52 ± 5.71 mm and 20.48 ± 5.92 mm, respectively, with a p-value of 0.433 recorded for the comparison of THL length between males and females (Table 1). In the present study, the mean THL width was observed as 16.65 ± 6.92 mm and 16.63 ± 7.49 mm on the right and left sides, respectively, with a p-value of 0.989 recorded for the comparison of

THL width between the right and left sides. Male individuals presented with a mean THL width of 16.83 ± 6.65 mm, while that of female individuals was recorded as 16.40 ± 7.84 mm with a p-value of 0.797 recorded for comparison of the THL width between males and females (Table 1).

The following were recorded as statistically significant correlations with regard to age and morphometric parameters of the LHBBT and THL (Table 2):

- | | | |
|------|-----------------------------|-----------------------------------|
| i) | Age vs. THL width | ($r = 0.274$; p-value = 0.014) |
| ii) | Age vs. LHBBT length | ($r = 0.254$; p-value = 0.023) |
| iii) | LHBBT width vs. THL width | ($r = -0.239$; p-value = 0.033) |
| iv) | LHBBT length vs. THL length | ($r = 0.284$; p-value = 0.011) |
| v) | LHBBT length vs. THL width | ($r = 0.436$; p-value = 0.000) |
| vi) | THL width vs. THL length | ($r = 0.379$; p-value = 0.001) |

As seen in Table 3, only one parameter, viz. LHBBT length, yielded statistically significant p-values for different effects of the multivariate analysis. The descriptive statistics also indicated that the mean value, deduced from the third set of measurements, is dissimilar to the mean values of the first and second sets of measurements (Table 3). This discrepancy in readings may be due to presence of one or more outliers in the respective dataset. The difference in readings was further confirmed by the statistically significant p-value of 0.003, indicating the reduced reliability of the values recorded for this LHBBT parameter. As the biostatistician verified the accuracy of the sample size, the reduced reliability may be due to investigator fatigue. The remaining parameters (viz. THL width, THL length and LHBBT width) did not yield any statistically significant differences, thus indicating optimum intra-observer reliability of the respective values as similar readings were recorded for all these parameters (Table 3).

Discussion

The LHBBT is a common origin site of anterior shoulder pain (Walch *et al.*, 1999; Ahrens and Boileau, 2007). Pathology of the LHBBT is often associated with rotator cuff disease and instability of the GHJ as it is intricately associated with the GHJ and the rotator cuff muscles (Urita *et al.*, 2016). Biomechanical movements of the arm resulting in sudden abduction and external rotation, forces the LHBBT medially against the lesser tubercle of the humerus and superiorly against the THL (Joshi *et al.*, 2014). The THL contributes to the

stability of the LHBBT within the BG and prevents subluxation (Johnson *et al.*, 2013). In athletes, especially those participating in overhead throwing activities, the GHJ and LHBBT undergo large amounts of stress due to greater biceps activity (Hsu *et al.*, 2008). When the arm is abducted and externally rotated during the accelerated phases of throwing, antagonistic forces are experienced by the superior labrum and biceps brachii anchor complex (Seroyer *et al.*, 2009). This throwing phase results in impingement of the posterosuperior labrum between the glenoid fossa and the humeral head (Seroyer *et al.*, 2009). This study, therefore, aimed to investigate the morphometric parameters of the LHBBT and THL.

Biceps tendinitis is a musculoskeletal disorder of the LHBBT (Churgay *et al.*, 2009). Inflammation of the LHBBT is defined as primary tendinitis and secondary tendinitis when it is in the BG or in the presence of rotator cuff tears, respectively (Churgay *et al.*, 2009). Primary tendinitis occurs in 5% of reported cases of biceps tendinitis, with secondary tendinitis accounting for the remaining 95% (Churgay *et al.*, 2009). Variation in the length and width of the LHBBT and THL has become an area of renewed interest as these factors play a key role in tendon reattachment and tenotomy (Mazocca *et al.*, 2007). According to Zunt (2014), hypertrophic biceps brachii muscles and larger LHBBT were commonly observed in individuals involved in manual labor. Furthermore, 90-95% of these individuals demonstrated right-hand dominance (Zunt, 2014). In the current study, the LHBBT mean length was found to be larger on the right side and distinctively greater in female individuals. The mean LHBBT lengths recorded in this study correlated with the findings of Joshi *et al.* (2014). However, the mean LHBBT length reported by Gothelf *et al.* (2009) and Cucca *et al.* (2010) were lower than those of the present study. Greater mean LHBBT widths were observed on the left side and were markedly higher in female individuals (Table 1). Although the mean LHBBT width documented by Drolet *et al.* (2016) was similar to that of the current study; the mean values of Cucca *et al.* (2010) and Joshi *et al.* (2014) were characteristically larger.

The LHBBT width may influence pathology of the LHBBT as the tendon is ensheathed within the BG by the THL (Wirth and Rockwood, 2009). The presence of a wider groove may allow the LHBBT to move more freely, thereby decreasing the chances of damage or injury (Karistinos and Paulos, 2007). In other cases, the THL covering the LHBBT may rupture causing the tendon to slide back and forth in the BG or slip out of the groove subsequently leading to biceps tendinitis (Karistinos and Paulos, 2007). However, the presence of a narrow BG may predispose an athlete to tendinitis (Pfahler *et al.*, 1999). This

degeneration may be seen on imaging resources (viz. CT scans, MRI, radiographs) and is noted to correlate with pathology of the LHBBT (Pfahler *et al.*, 1999). With regards to the right and left side, the mean THL length and width recorded by Snow *et al.* (2014) and Chidambaram *et al.* (2015) were lower than those of the current study. This may be due to the difference in the sample sizes of previous studies. Ethnicity and population-specific differences may also account for the difference in magnitude of the THL length and width (Karistinos and Paulos, 2007). The mean THL length and width observed in this study was found to be larger in male individuals. This finding alluded to gender-based differences generally depicted by the size of muscle-tendon units in males and the presence of light-weighted bones in females (Karistinos and Paulos, 2007). This study also correlated age with the relevant morphometric parameters (i.e. lengths and widths of the LHBBT and THL). Only one of the four negative correlations yielded a statistically significant p-value (i.e. LHBBT width vs. THL width) (Table 2). Similarly, statistically significant differences were observed for five out of the six positive weak correlations (i.e. Age vs. THL width; Age vs. LHBBT length; LHBBT width vs. LHBBT length, LHBBT length vs. THL width; THL width vs. THL length) (Table 2). It may be postulated that the negative weak correlation shared between the width of the LHBBT and the THL may be due to body build, nutritional status, diet and the effects of training (Mazzocca *et al.*, 2008). Biceps tenotomy and tenodesis have been identified as quick, easy and cost-effective procedures for the management of pathological conditions of the LHBBT when present with lesions of the rotator cuff muscles and the biceps labral complex (Elser *et al.*, 2011). While the functional role of the LHBBT is not clearly understood, the LHBBT is well accepted as a source of shoulder pain (Hanypsiak *et al.*, 2014). Pathology of the LHBBT originally included inflammation and tendinitis, however, recent literature has outlined that even in young athletes, tendinopathy of the LHBBT may allude to a more degenerative process rather than an inflammatory process (Lewis *et al.*, 2016). Shoulder pain resulting from biceps tendinitis has been successfully treated with arthroscopic biceps tenotomy or tenodesis and many techniques require the extra-articular portion of the LHBBT within the BG to be visualized morphometrically (Hanypsiak *et al.*, 2014). Although physical examinations can aid in diagnosing biceps tendinitis, ultrasound is considered the best method in obtaining a definitive diagnosis (Lewis *et al.*, 2016). Therefore, morphometric parameters outlining the structures of the LHBBT and THL may provide useful reference data required for the design and development of prosthesis, successful operative outcomes and may lead to an overall improvement in the healthcare system (Walch *et al.*, 1999; Boileau *et al.*, 2007; Mazzocca *et al.*, 2008). This

study comprised of 80 specimens with females representing 45% of the sample size and was considered a limitation due to the sample size and unequal numbers of male and female specimens. Future studies should include a larger sample size with equal numbers of male and female specimens to prevent false positive or false negative results. Since this study did not account for body build (viz. height, humeral length, weight) and lifestyle factors (viz. smoking, exercise and diet), it is recommended that future studies incorporate these factors for effective translation in clinical practice.

Conclusions

Although both parameters of the LHBBT were markedly greater in female individuals in this study, the LHBBT length was found to be larger on the right side and the LHBBT width was found to be larger on the left side. While male individuals presented with larger THL morphometric parameters, the THL length and width were notably greater on the left and right sides, respectively. This study noted that female individuals displayed larger LHBBT parameters, a finding that should be considered during surgical and prosthetic procedures. The results of this study may contribute to South African literature and enrich clinical knowledge as these parameters are important in tenotomy, tenodesis and other shoulder-related procedures.

References

1. Ahrens P, Boileau P. The long head of biceps and associated tendinopathy. *J Bone Joint Surg.* 2007; 89(8): 1001-1009. <https://doi.org/10.1302/0301-620X.89B8.19278>.
2. Boileau P, Baqué F, Valerio L, Ahrens P, Chuinard C, Trojani C. Isolated arthroscopic biceps tenotomy or tenodesis improves symptoms in patients with massive irreparable rotator cuff tears. *J Bone Joint Surg.* 2007; 89(4): 747-757. DOI: 10.2106/JBJS.E.01097.
3. Brownson P, Donaldson O, Fox M, Rees J, Rangan A, Jaggi A, Tytherleigh-Strong G, McBernie J, Thomas M, Kulkarni R. BESS/BOA patient care pathways: traumatic anterior shoulder instability. *Shoulder Elbow.* 2015; 7(3): 214-226. DOI: 10.1177/1758573215585656
4. Churgay CA. Diagnosis and treatment of biceps tendinitis and tendinosis. *Am Fam Physician.* 2009; 80(5): 470-476.
5. Chauhan K, Bansal M, Mistry P, Patil D, Modi SM. Variations of origin of biceps brachii muscle from glenoid labrum of scapula. *Nat J Med Res.* 2013; 3(2): 137-139.
6. Chidambaram R, Jayasree N, Sridhar S. Ossified Brodie's ligament: a case report. *Int J Anat Res.* 2015; 3(2): 1084-1086. DOI: 10.16965/ijar.2015.169
7. Clark J, Harryman D. Tendons, ligaments, and capsule of the rotator cuff. *Gross and microscopic anatomy. J Bone Joint Surg.* 1992; 74(5): 713-725. DOI: 10.2106/00004623-199274050-00010.
8. Cucca y, McLay S, Okamoto T, Ecker J, McMEnamin P. The biceps brachii muscle and its distal insertion: observations of surgical and evolutionary relevance. *Surg Radiol Anat.* 2010; 32(4): 371-375. DOI: 10.1007/s00276-009-0575-y.

9. Drolet P, Martineau A, Lacroix R, Roy J. Reliability of ultrasound evaluation of the long head of biceps tendon. *J Rehab Med.* 2016; 48: 554-558. DOI: 10.2340/16501977-2095.
10. Elser F, Braun S, Dewing C, Giphart J, Millett P. Anatomy, function, injuries, and treatment of the long head of biceps brachii tendon. *Arthroscopy.* 2011; 27(4): 581-592. DOI: 10.1016/j.arthro.2010.10.014.
11. Gothelf T, Bell D, Goldberg J, Harper W, Pelletier M, Yu Y, Walsh W. Anatomic and biomechanical study of the biceps vinculum, a structure within the biceps sheath. *Arthroscopy.* 2009; 25(5): 515-521. DOI: 10.1016/j.arthro.2008.10.026.
12. Hanypsiak B, DeLong J, Simmons L, Lowe W, Burkhart S. Knot strength varies widely among expert arthroscopists. *Am J Sports Med.* 2014; 42(8): 1978-1984. DOI: 10.1177/0363546514535554.
13. Hsu S, Miller S, Curtis A. Long head of biceps tendon pathology: management alternatives. *Clin Sports Med.* 2008; 27(4): 747-762. DOI: 10.1016/j.csm.2008.07.005.
14. Johnson JW, Thosteson J, Suva L, Ashfaq HS. Relationship of bicipital groove rotation with humeral head retroversion: A three-dimensional computed tomographic analysis. *J Bone Joint Surg Am.* 2013; 95(8):719-724. ISSN 2321-4287.
15. Joshi SD, Joshi SS, Sontakke Y, Mittal PS. Some details of morphology of biceps brachii and its functional relevance. *J Anat Soc India.* 2014; 63(1): 24-29. DOI:10.1016/j.jasi.2014.03.001
16. Jost B, Pfirrmann C, Gerber C. Clinical outcome after structural failure of rotator cuff repairs. *J Bone Joint Surg.* 2000; 82(3): 304-314. DOI:10.2106/00004623-200003000-00002.
17. Karistinos A, Paulos L. Anatomy and function of the tendon of the long head of biceps muscle. *Oper Techniq Orthop.* 2007; 15(1): 2-6. DOI: 10.1053/j.otsm.2006.12.004.
18. Lafosse L, Reiland Y, Baier GP, Toussaint B, Jost B. Anterior and posterior instability of the long head of the biceps tendon in rotator cuff tears: a new classification based on arthroscopic observations. *Arthroscopy.* 2007; 23(1):73-80.
19. Lewis RB, Reyes BA, Khazzam MS. A review of recent advances in the diagnosis and treatment modalities for long head of bicep tendinopathy. *Clin Med Insights: Trauma and intensive medicine.* 2016; 7: 9-15. DOI:10.4137/CMtiM.s39404.
20. Mazocca A, Rincon L, O'Connor R, Obopilwe E, Andersen M, Geaney L, Arciero R. Intra-articular cuff tears: analysis of injured and repaired strain behavior. *Am J Sports Med.* 2008; 36(1): 110-116. DOI: 10.1177/0363546307307502.
21. Pfahler M, Branner S, Refior HJ. The role of the bicipital groove in tendopathy of the long biceps tendon. *J Shoulder Elbow Surg.* 1999; 8(5): 419-424. DOI: [https://doi.org/10.1016/S1058-2746\(99\)90070-8](https://doi.org/10.1016/S1058-2746(99)90070-8).
22. Raney ED, Thankam FG, Dilisio MF, Agrawal DK. Pain and the pathogenesis of biceps tendinopathy. *Am J Transl Res.* 2017; 9(6): 2668-2683.
23. Ross M. National Institute of occupational health: 2008 surveillance report. 2008; 1-43. <http://www.nioh.ac.za/wp-content/uploads/2018/03/AR2008.pdf>.
24. Seroyer ST, Nho SJ, Bach BR, Bush-Joseph CA, Nicholson GP, Romeo AA. Shoulder pain in the overhead throwing athlete. *Sports Health.* 2009; 1(2):108-120. DOI: 10.1177/1941738108331199
25. Snow BJ, Narvy SJ, Omid R, Atkinson RD, Vangness CT. Anatomy and histology of the transverse humeral ligament. *J Orthop.* 2013; 36(10): e1295-1298. DOI: 10.3928/01477447-20130920-23.
26. Standring S. *Gray's Anatomy: The anatomical basis of clinical practice.* (4th ed). 2016; Elsevier Limited, New York, ISBN: 9780702052309.
27. Tank PW, Grant JCB. *Grant's Dissector.* 15th ed. Philadelphia: Wolter Kluwer Health. 2013. ISBN-10: 1609136063
28. Urita A, Funakoshi T, Amano T, Matsui Y, Kawamura D, Kameda Y, Iwasaki N. Predictive factors of long head of the biceps tendon disorders-the bicipital groove morphology and subscapularis tendon tear. *J Shoulder Elbow Surg.* 2016; 25(3): 384-389. DOI: 10.1016/j.jse.2015.12.015.
29. Walch G, Badet R, Boulahia A, Khoury A, St Anne-Lumiere C, Lyon, France. Morphologic study of the glenoid in primary glenohumeral osteoarthritis. *Arthroscopy.* 1999; 14(6): 756-760. DOI: 10.1016/S0883-5404(99)90232-2.
30. Werner A, Mueller T, Boehm D, Gohlke F. The stabilizing sling for the long head of biceps tendon in the rotator cuff interval: a histoanatomic study. *Am J Sports Med.* 2000; 28(1): 28-31. DOI: 10.1177/03635465000280011701.
31. Wirth MA, Rockwood CA, Lippitt SB, Matsen FA. *Rockwood and Matsen's: The shoulder.* 5th Ed. Philadelphia. 2009. ISBN: 978-1-4160-3427-8.
32. Zunt JR. Adams and Victor's principles of neurology. *Neurol.* 2010; 74(17): 1400. DOI: 10.1212/WNL.0b013e3181dad651.

Abbreviations	
BG	Bicipital groove
GHJ	Glenohumeral joint
I	Inferior
L	Lateral
LHBBT	Long head of biceps brachii tendon
M	Medial
P	p-value
<i>r</i>	<i>r</i> correlation co-efficient value
S	Superior
THL	Transverse humeral ligament

Table 1. Morphometric parameters of the LHBBT and THL

Parameters		Morphometry: Mean ± SD (mm)			
		LHBBT length	LHBBT width	THL length	THL width
Laterality	Right (n=40)	81.99±21.28	4.28±1.31	20.91±5.24	16.65±6.92
	Left (n=40)	79.73±17.27	4.67±1.43	21.19±6.36	16.63±7.49
p-value		0.604	0.205	0.832	0.989
Gender	Male (n=44)	79.82±19.66	4.35±1.17	21.52±5.71	16.83±6.65
	Female (n=36)	82.14±19.03	4.63±1.60	20.48±5.92	16.40±7.84
p-value		0.594	0.387	0.433	0.797

Table 2. Pearson Product Moment Correlation Co-efficient(*r*) test of parameters in this study

Parameters	Age		LHBBT width		LHBBT length		THL width		THL length	
	<i>r</i>	P	<i>r</i>	p	<i>r</i>	P	R	P	<i>r</i>	p
THL length	0.076	0.504	-0.147	0.192	0.284	0.011*	0.379	0.001*	1	

THL width	0.274	0.014*	-0.239	0.033*	0.436	0.000*	1
LHBBT length	0.254	0.023*	-0.093	0.412	1		
LHBBT width	-0.113	0.319	1				
Age	1						

*statistically significant p-value

Table 3. Intra observer reliability

Descriptive Statistics			Multivariate Analysis: Effect			
Parameter	Dataset	Mean \pm Std. Deviation (mm)	Pillai's Trace	Wilk's Lambda	Hotelling's Trace	Roy's Largest Root
THL Width	1	13.42 \pm 2.58	0.036	0.964	0.037	0.037
	2	13.50 \pm 2.60				
	3	13.43 \pm 2.60				
THL Length	1	19.53 \pm 2.55	0.009	0.991	0.009	0.009
	2	19.74 \pm 2.90				
	3	19.61 \pm 2.82				
LHBBT Width	1	5.28 \pm 1.27	0.030	0.970	0.031	0.031
	2	5.38 \pm 1.33				
	3	5.18 \pm 1.12				
LHBBT Length	1	80.39 \pm 21.17	0.136*	0.864*	0.157*	0.157*
	2	79.96 \pm 20.62				
	3	74.75 \pm 21.25				

LHBBT: long head of biceps brachii tendon; THL: transverse humeral ligament; *- statistically significant

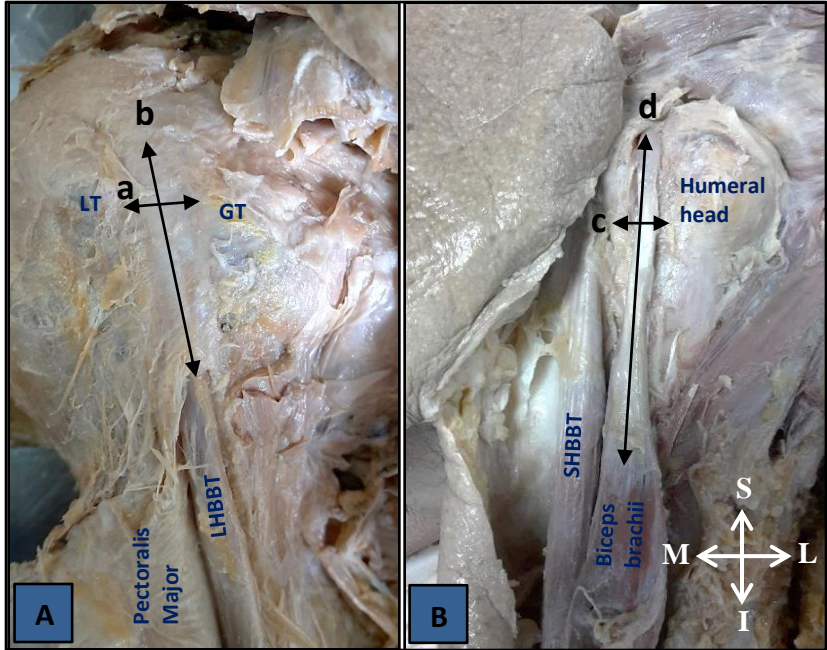


Figure 1. Anterior view of right shoulder: (A) Length and width of THL, (B) Length and width of LHBBT; A — THL width; b — THL length; c — LHBBT width; d — LHBBT length; GT — greater tubercle; I — inferior; L — lateral; LHBBT — long head of biceps brachii tendon; LT — lesser tubercle; M — medial; S — superior; SHBBT — short head of biceps brachii tendon