

ONLINE FIRST

This is a provisional PDF only. Copyedited and fully formatted version will be made available soon.



ISSN: 0015-5659

e-ISSN: 1644-3284

Root morphology of mandibular molars: a CBCT study

Authors: J. Abarca, M. Duran, D. Parra, K. Steinfort, C. Zaror, H. Monardes

DOI: 10.5603/FM.a2019.0084

Article type: ORIGINAL ARTICLES

Submitted: 2019-04-23

Accepted: 2019-07-17

Published online: 2019-07-19

This article has been peer reviewed and published immediately upon acceptance. It is an open access article, which means that it can be downloaded, printed, and distributed freely, provided the work is properly cited.
Articles in "Folia Morphologica" are listed in PubMed.

Root morphology of mandibular molars: a CBCT study

Canals anatomy of mandibular molars

J. Abarca^{1,2}, M. Duran³, D. Parra³, K. Steinfort¹, C. Zaror⁴, H. Monardes¹

¹Endodontics Graduate Program, Faculty of Dentistry, San Sebastian University, Santiago, Chile

²Faculty of Dentistry, San Sebastian University, Puerto Montt, Chile

³Endodontics Graduate Program Student, Faculty of Dentistry, San Sebastian University, Santiago, Chile

⁴Center for Research in Epidemiology, Economics and Oral Public Health (CIEESPO), Faculty of Dentistry, Universidad de La Frontera, Temuco, Chile

Address for correspondence: Jaime Abarca, Faculty of Dentistry, San Sebastian University, Lago Panguipulli 1390, Pelluco Alto, Puerto Montt, Chile, tel: +56652325536, e-mail: jaime.abarca@uss.cl

Abstract

Background: To assess the number and anatomical classification of roots and root canals of first and second mandibular molars using cone beam computed tomography (CBCT) in a Chilean population.

Materials and methods: This study evaluated the CBCT scans of 289 patients aged between 14 and 86 years, obtaining a sample of 1022 mandibular first and second molars. The number of roots and root canals was evaluated according to the anatomical classification proposed by Ahmed in 2016. Data were analyzed using Pearson's chi-squared test and ANOVA.

Results: 951 molars had two roots (93.05%), while the remaining 71 molars (6.95%) had one root. The most frequent root and root canal morphologies found were: ²MM M² D¹ (29,65%), ²MM M²⁻¹ D¹ (22,3%) and ²MM M¹ D¹ (13,4%), with a total of 32 different anatomical distributions. C-shaped canals were present in 56 second molars and were more frequently found in women than in men (7.1% vs. 3.88%) (p = 0.024).

Conclusions: The analysis of internal anatomy using CBCT revealed a highly variable distribution of root canals. The most frequent morphology found in mandibular molars in a Chilean population was two roots and three canals.

Key words: root canal configuration, mandibular molar, C-shaped canal, cone beam computed tomography, root anatomy

INTRODUCTION

The full understanding of the external and internal dental anatomy is indispensable to successfully removing organic residue and microorganisms from root canals (1, 2). The correct cleaning and shaping of the main root canals could be decisive in the prognosis of the treated tooth. A study conducted by Karabucak et al. shows that apical radiolucency in endodontically treated teeth appears four times more frequently in those with untreated root canals (3). Of the teeth that were observed, almost 20% of mandibular molars had untreated canals.

Mandibular molars are among the teeth that most frequently require endodontic treatment, and there are several studies that describe and analyze their complex internal anatomy. However, most of these studies have been conducted on Asian and European populations (1), there being scarce literature that addresses the Latin American population (4, 5). The influence of ethnicity on anatomical variability is known, which makes it relevant to obtain more data on the dental anatomy of Latin American and of its individual countries in particular (5); this is because the ethnic characterization of Latin-american countries can be quite different. For example, Brazilian population has a strong contribution of European, African, Asian and Native-american ethnic groups(6), while Chile has mainly Native-american and European genetics (7).

Internal dental anatomy studies have used different methods, which include diaphanization with or without staining, impressions with plastic resins, x-rays with or without files inside the canals, retrospective evaluation of periapical x-rays, cone beam computed tomography (CBCT), spiral computed tomography and computed microtomography (micro-CT) (1, 8). The use of CBCT in anatomical studies began several years ago because it has advantages like the non-invasive three-dimensional

analysis of structures, good resolution, adjustable field of vision and low radiation dose using state-of-the-art equipment (8).

The emergence of new ways to evaluate the internal anatomy has made it difficult to use the traditional classifications of anatomy like Vertucci's (9). The new anatomical classification proposed by Ahmed (10) for dental anatomy and anomalies (11) recommends going beyond the rigidity of former classification systems and adapting to the conditions of each tooth, as well as recommending it for the three-dimensional analysis of the dental structure.

The aim of this study was to determine the number and anatomical classification of roots and root canals of mandibular first and second molars in a Chilean population using CBCT.

MATERIALS AND METHODS

A descriptive study was carried out, prior approval of the Ethics Committee of the University San Sebastian (resolution 2019-51), where 1580 CBCT images were examined, taken as part of the diagnosis or planning of dental treatments between January 2011 and March 2015 in the Begmax center in Santiago, Chile. CBCT exams were included that showed mandibular first or second molars with complete root formation and root integrity of patients aged between 14 and 86 years. Teeth with endodontic treatment, open apex, signs of apical resorption or apical surgery and extensive metallic restorations that impeded the correct observation of the internal anatomy were excluded.

The CBCT images were obtained by qualified personnel using a Gendex® GXCB-500, powered by I-CAT (Gendex/Kavo Dental, GmbH, Biberach, Germany), that operates with 120KVp and 5mA, with pulsed exposure and an effective dose of 36 to 74 μ Sv. The voxel size was 0.2mm and the slice-thickness was 0.2mm.

Prior to the evaluation of the images, two observers were calibrated, first theoretically and then practically. In the practical part, each evaluator analyzed ten CBCT images independently under the same conditions of time, light and screen resolution. Two weeks later the procedure was repeated under the same conditions. With the results obtained, the interobserver agreement was calculated using Cohen's Kappa coefficient, obtaining good agreement (Kappa = 0.75).

The images obtained were analyzed using the iCAT Vision software (Kavo Dental GmbH, Biberach, Germany) in a dark room on 19.5" LCD monitors with a resolution of 1920 x 1080 pixels (LG®). The samples were analyzed using the three spatial axes of the program and classifying the frequency, type of roots and root canals according to Ahmed's classification (Fig. 1) (10). The results were collected in an Excel® spreadsheet (Microsoft Office, USA) designed specifically for this study. A descriptive analysis was performed to establish the frequency and distribution of the variables. Pearson's chi-squared test for qualitative variables and ANOVA for quantitative variables were applied for comparison between groups. For all cases a level of significance of 0.05 was considered. The results were presented through frequency distribution tables. The data were processed with the STATA 15 software (Stata Corp LP, USA).

RESULTS

289 CBCT images fulfilled the inclusion criteria, with a total of 1022 molars observed. 49.61% of the CBCT images were from female patients with an average age of 30 years (range 14 - 86).

In terms of the frequency of roots, 951 molars (93.05%) had two roots, whereas the remaining 71 (6.95%) had one root, of which 70 were mandibular second molars (Table 1).

In terms of the distribution of roots and root canals, the most frequent was: ²MM M² D¹ (29,65%), ²MM M²⁻¹ D¹ (22,3%) and ²MM M¹ D¹ (13,4%). A third mesial canal (middle mesial canal) was present in 0.3% of the molars (Table 2). 32 different anatomical configurations were found for the roots and root canals of mandibular molars.

When referring specifically to the cervical third, it was observed that the mesial roots of the first and second molars had two canals, 416 (81.56%) and 292 (57.03%) respectively, unlike the distal root of the first and second molar, where only one canal was found, 438 (85.88%) and 432 (84.37%) respectively (Table 3). The presence of 56 molars with C-shaped canals was confirmed (Figure 2), all in second molars, which corresponds to 11.02% of the right second molars and 12.16% of the left second molars (10.93% on average). This anatomical variation was found more in women than in men

(7.1% vs. 3.88%), a difference that was statistically significant ($p= 0.024$). No dependency ratio was found in relation to age ($p= 0.156$).

DISCUSSION

The different anatomical variations represent a technical challenge to achieve success in endodontic treatment (6). Images obtained by CBCT are a reliable tool for the detection and later instrumentation of complex canal configurations (12) and one of the reasons for which their application in endodontics has increased in recent years (13). The results obtained in this study agree with those observed in Brazilian, Palestinian, Turkish and Chinese populations, where it was seen that the most frequent morphology for mandibular molars is two canals in the mesial root and one in the distal evaluated by CBCT (8) (6) (14). The same results were reported in Egyptian and Brazilian populations using micro-CT (9, 15) and in a systematic review that included 64 studies using micro-CT (12). Evidence shows that ethnicity is more related to the number of roots than to the number or distribution of root canals (1), which would explain the similarity with the results obtained in this study.

In relation to the presence of C-shaped canals, our results are similar to those of the Belgian (8.93%) (4) and Saudi populations (9.1%) (16). However, it was considerably less than what was observed in the Chinese (29%) and Mayan populations (35%) (5, 14). There is some evidence that there are similarities between Native American and Northeast Asian anatomy which could explain the high incidence of C-shaped canals in Mayan population. Differences with our results could be because Chile may have a different genetic background than North American native populations, because of European genetics due to immigration to Chile since the 18th, or perhaps both.

Dental anatomy studies usually include a characterization according to gender, and this is because there is some correlation between root development and the X chromosome (Varrela, 1990). Studies conducted on Chinese and Turkish populations reported a greater prevalence of C-shaped canals in women than in men, which is similar to what was found in this study (8, 16). On the other hand, Ladeira et al. found no differences in the frequency of C-shaped canals according to gender in the Brazilian population (17). The incidence of C-shaped canals is strongly linked to ethnicity, which

would explain the differences observed among the different populations (1, 5, 14, 16-18), but it is unknown as to why some populations present gender differences and others do not.

The third canal of the mesial root, or middle mesial canal, was first described in 1974 (19), but it has not been widely studied and presents a highly diverse prevalence among different populations, ranging from 0.1 and 22.1% (1, 12, 20). In this study, the presence of this third mesial canal in some of the root thirds was observed in 0.3% of cases and all converged into the mesiobuccal or mesiolingual canal, with a prevalence similar to that noted in a meta-analysis of micro-CT studies (12), but mandibular than that observed in Brazilian (22.1%) and Turkish (14.8%) dental anatomy (20). There is agreement among different studies in that the most frequent anatomical configuration of this canal is confluent (16).

Among the most frequently used methods currently to analyze internal root anatomy are CBCT and micro-CT. Both are non-invasive methods that capture three-dimensional images of the anatomical structures (18). The main advantage of micro-CT is the high resolution, which even allows the detailed and precise analysis of accessory structures (5). On the other hand, the advantage of CBCT is that it can be used in vivo and larger sample sizes can be obtained (21). In a study by Domark (18), the analysis of the two methods was compared to determine the presence of root canals in mesiobuccal roots of upper molars with no statistically significant differences being found between the two methods. Another study, however, that evaluated the configuration of mesial roots in mandibular molars, found that micro-CT showed greater detail particularly when the anatomy did not conform to Vertucci's classification (21).

Vertucci's classification (19), which has been widely used in both clinical settings and research, includes eight different types of canal configurations. The results obtained in this study show 32 different types of root and root canal configurations, which is consistent with what is proposed by Ahmed (10), who suggests that the old anatomical classifications have become insufficient for the correct interpretation of three-dimensional images like CBCT and micro-CT (9, 15). An advantage of this new classification system is that it considers all possible root canal configurations, which in a

clinical scenario, would favor a proper coronal and radicular access for the location of these canals at all levels.

Recently, its use has been proposed for research, education and clinical practice in order to gain a systematic and more precise anatomical description that facilitates endodontic treatment (22). In our experience, this classification is more intuitive, logical and accurate in the description of internal dental anatomy.

To our knowledge, this would be the first study in molars to use this classification and it shows the reality of the diversity of root canal configurations. In a study conducted in premolars that used this new classification, they found eleven different configurations (23), which is more than what is considered by Vertucci's classification, but not as much as what was observed in this study. This may have happened because molar anatomy tends to be more complex, ranging from one to five canals per tooth.

CONCLUSIONS

The most frequent morphology found in mandibular molars in a Chilean population was two roots and three canals, two mesial and one distal. 32 different types of anatomical distribution were observed. The frequency of C-shaped canals was 10.9% in second molars.

Conflict of interest

The authors declare no conflict of interest.

This study received no funding from institutional or private sources.

References

1. de Pablo OV, Estevez R, Peix Sanchez M, Heilborn C, Cohenca N. Root anatomy and canal configuration of the permanent mandibular first molar: a systematic review. *Journal of endodontics* 2010;36(12):1919-1931.
2. Hartmann RC, Baldasso FE, Sturmer CP, Acauan MD, Scarparo RK, Morgental RD, et al. Clinically relevant dimensions of 3-rooted maxillary premolars obtained via high-resolution computed tomography. *Journal of endodontics* 2013;39(12):1639-1645.
3. Karabucak B, Bunes A, Chehoud C, Kohli MR, Setzer F. Prevalence of Apical Periodontitis in Endodontically Treated Premolars and Molars with Untreated Canal: A Cone-beam Computed Tomography Study. *Journal of endodontics* 2016;42(4):538-541.

4. Torres A, Jacobs R, Lambrechts P, Brizuela C, Cabrera C, Concha G, et al. Characterization of mandibular molar root and canal morphology using cone beam computed tomography and its variability in Belgian and Chilean population samples. *Imaging Sci Dent* 2015;45(2):95-101.
5. Ramirez-Salomon M, Vega-Lizama E, Tiesler V, Alvarado-Cardenas G, Lopez-Villanueva M, Sierra-Sosa T, et al. The C-shaped canal molar: an Endodontic-Archaeological study of the relationships between Mayan pre-Hispanic and contemporary population of Yucatan. *International endodontic journal* 2014;47(11):1084-1089.
6. Caputo BV, Noro Filho GA, de Andrade Salgado DM, Moura-Netto C, Giovani EM, Costa C. Evaluation of the Root Canal Morphology of Molars by Using Cone-beam Computed Tomography in a Brazilian Population: Part I. *Journal of endodontics* 2016;42(11):1604-1607.
7. Rocco P P, Morales G C, Moraga V M, Miquel P JF, Nervi O F, Llop R E, et al. Composición genética de la población chilena: Distribución de polimorfismos de DNA mitocondrial en grupos originarios y en la población mixta de Santiago. *Revista médica de Chile* 2002;130:125-131.
8. Celikten B, Tufenkci P, Aksoy U, Kalender A, Kermeoglu F, Dabaj P, et al. Cone beam CT evaluation of mandibular molar root canal morphology in a Turkish Cypriot population. *Clin Oral Investig* 2016;20(8):2221-2226.
9. Wolf TG, Paque F, Zeller M, Willershausen B, Briseno-Marroquin B. Root Canal Morphology and Configuration of 118 Mandibular First Molars by Means of Micro-Computed Tomography: An Ex Vivo Study. *Journal of endodontics* 2016;42(4):610-614.
10. Ahmed HMA, Versiani MA, De-Deus G, Dummer PMH. A new system for classifying root and root canal morphology. *International endodontic journal* 2017;50(8):761-770.
11. Ahmed HMA, Dummer PMH. A new system for classifying tooth, root and canal anomalies. *International endodontic journal* 2018;51(4):389-404.
12. Tomaszewska IM, Skinningsrud B, Jarzebska A, Pekala JR, Tarasiuk J, Iwanaga J. Internal and external morphology of mandibular molars: An original micro-CT study and meta-analysis with review of implications for endodontic therapy. *Clin Anat* 2018;31(6):797-811.
13. Setzer FC, Hinckley N, Kohli MR, Karabucak B. A Survey of Cone-beam Computed Tomographic Use among Endodontic Practitioners in the United States. *Journal of endodontics* 2017;43(5):699-704.
14. Zhang R, Wang H, Tian YY, Yu X, Hu T, Dummer PM. Use of cone-beam computed tomography to evaluate root and canal morphology of mandibular molars in Chinese individuals. *International endodontic journal* 2011;44(11):990-999.
15. Filpo-Perez C, Bramante CM, Villas-Boas MH, Hungaro Duarte MA, Versiani MA, Ordinola-Zapata R. Micro-computed tomographic analysis of the root canal morphology of the distal root of mandibular first molar. *Journal of endodontics* 2015;41(2):231-236.
16. Alfawaz H, Alqedairi A, Alkhayyal AK, Almobarak AA, Alhusain MF, Martins JNR. Prevalence of C-shaped canal system in mandibular first and second molars in a Saudi population assessed via cone beam computed tomography: a retrospective study. *Clin Oral Investig* 2019;23(1):107-112.
17. Ladeira DB, Cruz AD, Freitas DQ, Almeida SM. Prevalence of C-shaped root canal in a Brazilian subpopulation: a cone-beam computed tomography analysis. *Braz Oral Res* 2014;28(1):39-45.

18. Domark JD, Hatton JF, Benison RP, Hildebolt CF. An ex vivo comparison of digital radiography and cone-beam and micro computed tomography in the detection of the number of canals in the mesiobuccal roots of maxillary molars. *Journal of endodontics* 2013;39(7):901-905.
19. Vertucci FJ. Root canal morphology and its relationship to endodontic procedures. *Endodontic Topics* 2005;10(1):3-29.
20. Versiani MA, Ordinola-Zapata R, Keles A, Alcin H, Bramante CM, Pecora JD, et al. Middle mesial canals in mandibular first molars: A micro-CT study in different populations. *Arch Oral Biol* 2016;61:130-137.
21. Ordinola-Zapata R, Bramante CM, Versiani MA, Moldauer BI, Topham G, Gutmann JL, et al. Comparative accuracy of the Clearing Technique, CBCT and Micro-CT methods in studying the mesial root canal configuration of mandibular first molars. *International endodontic journal* 2017;50(1):90-96.
22. Ahmed HMA, Dummer PMH. Advantages and Applications of a New System for Classifying Roots and Canal Systems in Research and Clinical Practice. *EUR Endod J* 2018;3(1):9-17.
23. Saber SEDM, Ahmed MHM, Obeid M, Ahmed HMA. Root and canal morphology of maxillary premolar teeth in an Egyptian subpopulation using two classification systems: a cone beam computed tomography study. *International endodontic journal* 2019;52(3):267-278.

Tables

Table 1: Number of roots in mandibular first and second molars

<i>Molars</i>	Number of roots		
	1	2	Total
First molars	1	509	510
Second molars	70	442	512
Total	71	951	1022

Table 2: Frequency of roots and root canals by root third in mandibular molars.

<i>Number of canals in cervical third</i>	Mesial		Distal	Mesial	Distal
	Root		Root	Root	Root
	First molar		First molar	Second molar	Second molar
0	0	0	0	59	
1	94	438	220	432	
2	416	72	292	21	
Total	510	510	512	512	

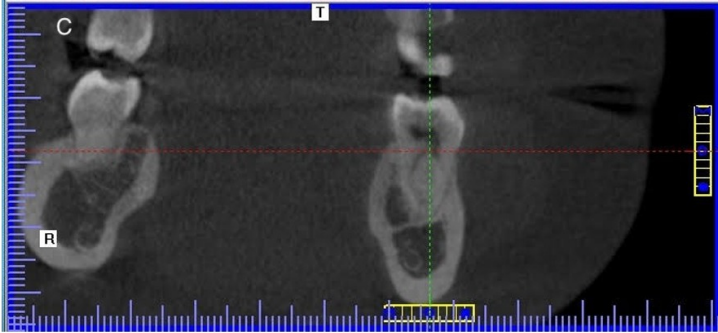
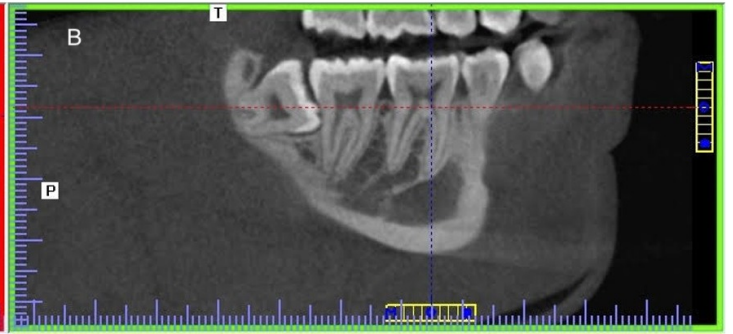
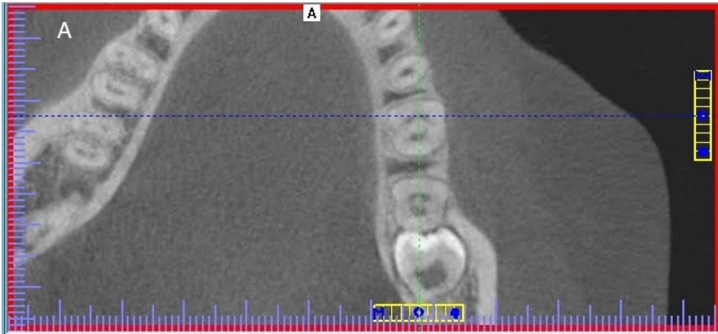
Table 3: Number of root canals in cervical third in mandibular first and second molars.

Frequency of canals by root	M Root			D Root		
	cervical third	middle third	apical third	cervical third	middle third	apical third
	0	0%	0%	0%	5.77%(59)	5.77%(59)
1	30.72%(314)	0)	6)	0)	1)	5)
2	69.18%(707)	0)	6)	9.10%(93)	8.02%(82)	7.43%(80)
3	0.1% (1)	0.20%(2)	0%	0%	0%	0%

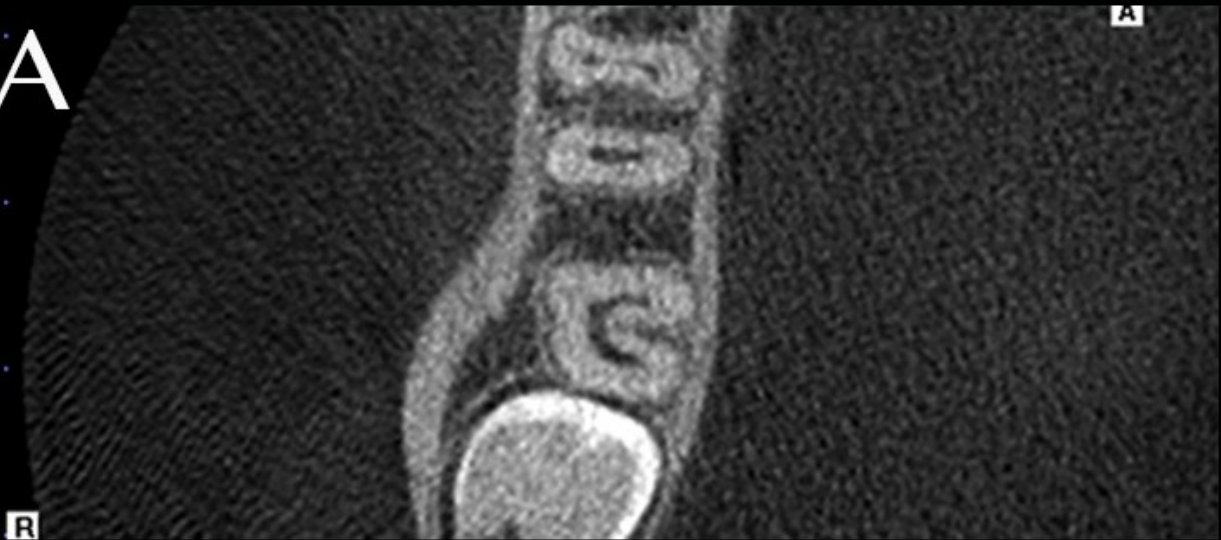FIGURES

Figure 1. CBCT slices (GXCB-500, powered by I-CAT, Gendex/Kavo Dental, GmbH, Biberach, Germany) used to analyze the root and root canal dental anatomy of a 46 tooth (arrow). A: Axial view, note the presence of two canals in mesial root and one canal in distal root, B: Coronal view, C: Sagittal view, where the two mesial canals are visible in their length.

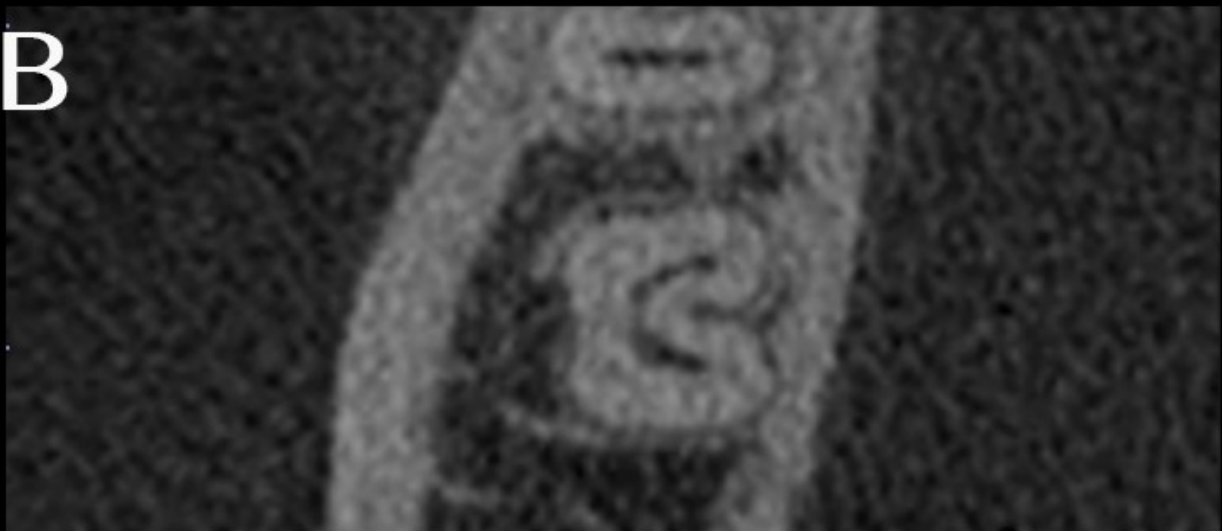Figure 2. CBCT slices (GXCB-500, powered by I-CAT, Gendex/Kavo Dental, GmbH, Biberach, Germany) used to analyze a C-Shaped mandibular second molar (arrow). Coronal view of the A: cervical root third, B: middle root third and C: apical root third.



A



B



C

