

ONLINE FIRST

This is a provisional PDF only. Copyedited and fully formatted version will be made available soon.



ISSN: 0015-5659

e-ISSN: 1644-3284

Sella turcica and craniofacial morphology in patients with palatally displaced canines: a retrospective study

Authors: Michele Tepedino, Michele Laurenziello, Laura Guida, Graziano Montaruli, Vincenzo Grassia, Claudio Chimenti, Merigrazia Campanelli, Domenico Ciavarella

DOI: 10.5603/FM.a2019.0050

Article type: ORIGINAL ARTICLES

Submitted: 2019-03-15

Accepted: 2019-04-09

Published online: 2019-04-19

This article has been peer reviewed and published immediately upon acceptance. It is an open access article, which means that it can be downloaded, printed, and distributed freely, provided the work is properly cited.

Articles in "Folia Morphologica" are listed in PubMed.

Sella turcica and craniofacial morphology in patients with palatally displaced canines: a retrospective study

Running title: Sella morphology and canine impaction

Michele Tepedino¹, Michele Laurenziello², Laura Guida², Graziano Montaruli²,
Vincenzo Grassia³, Claudio Chimenti¹, Merigrazia Campanelli², Domenico Ciavarella²

¹*Department of Biotechnological and Applied Clinical Sciences, University of L'Aquila, L'Aquila, Italy*

²*Department of Clinical and Experimental Medicine, University of Foggia, Foggia, Italy*

³*Multidisciplinary Department of Medical- Surgical and Dental Specialties, Second University of Naples, Naples, Italy*

Address for correspondence: Dr Michele Tepedino, Department of Biotechnological and Applied Clinical Sciences, University of L'Aquila. V.le S. Salvatore, Edificio Delta 6, 67100 L'Aquila (AQ), Italy. E-mail: m.tepedino@hotmail.it; Phone: +39 0862 434782.

ABSTRACT

Background: To evaluate the sella and craniofacial morphological features in growing patients with palatally displaced canines compared to controls.

Materials and methods: Twenty-two subjects with palatally displaced canines were retrospectively selected and compared to 22 controls matched for age and gender. Lateral cephalograms were collected and sagittal and vertical cephalometric variables were measured, together with sella interclinoid distance, sella depth, and sella diameter. The independent samples T-test or Mann-Whitney U-test were used to compare all the variables between the two groups. A Pearson correlation was computed for the craniofacial and sella variables that differed significantly ($p < 0.05$) between the groups.

Results: Patients with palatally displaced canines showed a smaller interclinoid distance

and a greater SNA angle than control subjects. The interclinoid distance and the SNA angle were negatively correlated (-0.52 , $p=0.017$) in the experimental group.

Conclusions: Growing patients with palatally displaced canines had smaller sella interclinoid distances and a greater SNA angle than control subjects.

Key words: canine impaction, impacted teeth, impacted tooth, impacted canine, sella turcica

INTRODUCTION

Impaction of maxillary canines is a condition found in 1–2% of the population,[1] and in 2.4% in patients of Italian ancestry [2,3]. If left untreated, it can lead to dentigerous cyst formation, root resorption of adjacent teeth, ankylosis, teeth migration and loss of arch space [4], and therefore an appropriate intervention is needed. When intercepted in a timely fashion, the palatal ectopy of a maxillary canine can be treated with extraction of the deciduous canine [1,5] and palatal expansion [6,7], with anchorage on deciduous molars when possible [8,9]. At later stages of development, the treatment of an impacted maxillary canine requires surgical exposure and orthodontic traction with the use of physiological forces [10,11]. Such treatment can be challenging for both the patient and the clinician, can require complex biomechanics and the use of miniscrews [12], and treating a malocclusion with an impacted tooth usually takes longer than treating a similar condition without impaction [13]. Therefore, it is of great importance to recognize the risk of canine impaction as soon as possible and to intervene to change the eruptive path of the tooth to avoid establishment of a full-blown impaction. Many prognostic factors have been studied [14], as well as other skeletal features that can indicate a higher risk of impaction [15]. Since genetic factors have been demonstrated in the etiology of the palatal impaction of maxillary canines [16,17], it is possible that other features having the same genetic origin could be used as indicators for treatment need and the prognosis of ectopic canines. For example, some authors found a relationship between palatally impacted canines and sella turcica bridging (i.e. the abnormal calcification of the dura mater

between the anterior and posterior clinoidal processes) [18–23]. The sella turcica is of great importance for orthodontists because it is a landmark used for several cephalometric analyses, and the anterior wall of the sella is used for growth prediction and tracing superimpositions [24]. The anterior wall of the sella shares with the dental lamina a common embryological origin from the neural crest cells, and therefore a common genetic origin of dental and sella anomalies is plausible [25]. In addition, sella turcica anomalies were observed in patients with skeletal Class II and III [26,27]. The aim of the present study was, therefore, to evaluate the shape of the sella and the craniofacial morphology of growing patients with palatally displaced canines, compared to healthy untreated subjects. The null hypothesis was that no difference exists in sella and craniofacial morphology between patients with impacted canines and controls.

MATERIALS AND METHODS

This manuscript was prepared according to the STROBE guidelines. The present protocol was approved by the Institutional Review Board of the University of L'Aquila (Protocol no 23169), the methods used were in accordance to the relevant guidelines (the Helsinki Declaration of 1975 and subsequent revisions) and legislation, and all patients gave written informed consent to participate. The records of patients treated at the Dental Clinic, University of L'Aquila, from January 2010 to January 2018 were screened for the following inclusion criteria:

- Age between 8 and 16 years old
- Absence of systemic diseases or craniofacial syndromes
- Good-quality pre-treatment lateral cephalogram, without evident distortions
- Diagnosis of a palatally displaced maxillary canine (with any depth, position, or severity)

The diagnosis of palatally displaced maxillary canine was based on clinical examination and confirmed by an orthopantomography (Fig. 1) or every other available source of information (i.e. computed tomography). A maxillary canine was considered palatally displaced when one or more of the following clinical or radiographic conditions were present: was not erupted after the physiologic time limit, the crown was

positioned palatally to the roots of the adjacent teeth, the crown was overlapped over the root of the lateral incisor, the canine was inclined at an angle greater than 30° with respect to the median plane on an orthopantomography. The subjects were not stratified by the severity of the canine's displacement, because this was considered not relevant for the aim of the study: for the considered age range, the presence of any eruption anomaly would require an intervention.

Sample size calculation (PS Power and Sample Size Calculations, Version 3.0)[28] revealed that to detect a difference in group means of at least 1 mm of sella length with an independent samples T-test, with a Type I error probability of 0.05 and a power of 0.9, 22 subjects would be needed, with an experimental-to-control ratio of 1. The first 22 subjects screened in chronological order that met the inclusion criteria were included in the study group. Then, 22 subjects without canine impaction, matched for age and gender, were included in the control group.

Cephalometric tracings

Tracings were performed over lateral cephalograms by an expert operator in a single-blinded fashion (Fig. 2). The following variables were calculated for each subject in both groups:

- SN-GoMe, the angle between the plane passing through the Sella and Nasion points, and the plane passing through the Gonion and Menton points
- SNA, the angle between the plane passing through the Sella and Nasion points, and the plane passing through the Nasion point and the A-point
- ANB, the angle between the plane passing through the A-point and Nasion point, and the plane passing through the Nasion point and the B-point
- SN-U1, the angle between the plane passing through the Sella and Nasion points, and the long axis of the upper central incisor
- S-N, the distance in mm between the Sella and Nasion points
- Go-Me, the distance in mm between the Gonion and Menton points

Sella morphology

Lateral cephalograms were calibrated using a ruler positioned over the craniostat. Then, the following measurements (Fig. 3) were performed using ImageJ software (ImageJ version 1.5, National Institute of Health, USA), by an expert operator in a single-blinded fashion:

- Sagittal interclinoid distance, the distance between the tip of the dorsum sellae and the tuberculum sellae
- Sella depth, the perpendicular distance between the interclinoid line and the deepest point of the floor of the sella
- Sella diameter, the distance between the tip of the tuberculum sellae and the most posterior point of the inner surface of the posterior wall of the sella.

Error of the method

To calculate the error of the method, ten subjects were randomly selected (www.randomizer.org) from each of the two groups, and each operator repeated the tracings and sella measurements, respectively, after a 2-week interval. An Intra-Class Correlation (ICC) coefficient was calculated between the two sets of measurements to evaluate the intra-operator reliability.

Statistical analysis

Descriptive statistics were computed for all the variables. A Shapiro-Wilk normality test was used to assess the type of data distribution ($p < 0.05$). An independent samples T-test or a Mann-Whitney U-test, depending on whether data were normally or not-normally distributed, was used to compare the cephalometric and sella variables in the study and control group.

For the variables that showed a statistically significant difference between groups, a Pearson correlation or a Spearman's rho correlation, depending on data distribution, was used to correlate the cephalometric characteristics with the sella measurements in both groups.

For all statistical tests, the Type I error was set as 0.05. Calculations were made using SPSS Software (SPSS for Windows, Version 13.0, Chicago, SPSS Inc.).

RESULTS

Regarding the error of the method, the calculated ICC coefficient was excellent (> 0.85) for all variables, revealing good intra-observer reliability of the measurements. The experimental group was composed of six males and 16 females (mean age 13 ± 1.2), as was the control group (mean age 12.9 ± 1.0).

Descriptive statistics are reported in Tables I and II. Regarding cephalometric measurements, a statistically significant difference was observed regarding SNA angle, which was higher ($86.0^\circ \pm 4.7^\circ$ in the study group, $82.8^\circ \pm 4.8^\circ$ in the control group, $p= 0.047$) in the study group (Table III). Regarding sella morphology, the interclinoid distance was smaller in the study group (3.2 ± 1.2 mm, $p= <0.001$) than in the control group (5.3 ± 2.2 mm, Table II). Such reduced interclinoid distance is the expression of an abnormal calcification of the dura mater between the anterior and posterior clinoidal processes (i.e. sella turcica bridging)[18]. The null hypothesis that no difference was present between patients with palatally displaced canines and controls regarding sella and craniofacial morphology was rejected.

A Pearson correlation between SNA angle and interclinoid distance revealed a moderate correlation between craniofacial and sella morphology in subjects with palatally displaced canines ($\rho= -0.52$, $p= 0.017$), but not in the control group (Table IV).

DISCUSSION

The abnormal calcification of the dura mater forming the interclinoid ligament, known radiographically as sella “bridging”, is considered a normal variation of the morphology of sella turcica [29–32], although some pathological conditions are associated with it, such as nevoid basal cell carcinoma syndrome, Williams syndrome, and other craniofacial syndromes [33–35]. Morphological alterations of the sella, as well as of other structures like the atlas, are easily observed on radiographs routinely

taken in dental practice, such as lateral cephalograms. Therefore, being able to recognize such alterations that could indicate other developmental anomalies is of great importance [19,33].

The incidence of partial calcification of the interclinoid ligament in a healthy Italian population is reported to be around 33%, while complete calcification (sella bridging) is reported to occur in 9.9% of patients [18]. In other studies on autopsy material, a true sella bridge was found in 2% to 6% of cases [35]. In the present study, 13% of cases had complete sella bridging. A general increase in calcification of the interclinoid ligament was also found in the experimental group compared to the control group, demonstrated by the smaller interclinoid distance (Table II). Similarly, Leonardi et al.[18] found a significant association between sella bridging and dental anomalies like palatally displaced canines, agenesis of second mandibular premolars, and dental transposition [36]. Ali et al.[24] reported that the chance of observing increased calcification of the interclinoid ligament or sella bridging in patients with an impacted canine is four times higher than in patients without dental anomalies. Similar results were found by other authors, confirming the relationship between ossification of the interclinoid ligament and canine impaction [19,37]. The reason behind this association could lie in the common embryogenic origin from neural crest cells of sella turcica and dental epithelial progenitor cells, as well as maxillary, palatal, and frontonasal developmental fields [33]. This common origin may explain why genetic mutations can affect the development of the midface, the teeth, and part of the sella turcica [19,33]. Even if this theory is suggested by many authors [18,20–24], it can only partially explain these findings, because the presence of a sella bridging requires to a certain extent the involvement of the posterior clinoidal processes, which have a different embryological origin from the notochord [33]. On the other hand, the only study that investigated the association between sella bridging and canine impaction on 3-D Cone-Beam Computed Tomography [38], reported results that did not reach statistical significance. The methodological differences to evaluate the presence of a partial or a complete sella bridging in 2-D radiographs compared to 3-D images makes these studies incomparable, and suggests that further investigation are needed to refine the diagnostic process of this anomaly of the sella, considering that 2-D radiographs are still representing the standard for orthodontic diagnosis.

Regarding sella depth, our measurements were consistent with those of other studies, ranging from 6 to 8 mm [24,37]; on the other hand, we found smaller values of sella diameter in our sample (Table II) than in other studies [24,37]. However, there was no significant difference between the experimental and control group for these measurements.

Regarding cephalometric assessment, in the present study patients with palatally displaced maxillary canines presented a greater SNA angle than control subjects (Table III). In addition, the value of the SNA angle was correlated (Table IV) with the interclinoid distance in the group of patients with palatally displaced canines, with one variable increasing as the other one decreased. An altered sella depth or diameter would influence the Sella point's position, thus possibly modifying the value of the SNA angle, but in the present study no differences were found between the two groups regarding sella depth or sella diameter. Therefore, the greater SNA angle observed in patients with palatally displaced canines should be related to an altered anterior cranial base or to a different morphology of the maxilla, compared to control subjects. Some authors investigated the association between canine impaction and different craniofacial morphologies, with contradicting results. Mercuri et al. [39] found no influence of the sagittal skeletal relationship on the incidence of canine impaction. On the other hand, some authors found an increased incidence of sella bridging in patients with skeletal Class II [27] and Class III [26] compared to Class I patients. Basdra et al.[40] reported a close association of skeletal Class II malocclusion and congenital dental anomalies, and in particular impacted canines that were present in 33.5% of subjects with such skeletal disharmony. Nevertheless, the evaluations of those authors are not directly comparable to those of the present study. Larsen et al.[41] observed a significantly shorter anterior cranial base (Sella-Nasion distance) in patients with ectopic canines, and such condition can translate into an increased SNA angle. Therefore, it can be argued that alterations of the development of the anterior cranial base, which result in a reduced interclinoid distance and a shorter Sella-Nasion distance, are related to eruption anomalies of the maxillary canines. However, the presence of a causative effect behind this association needs to be demonstrated.

Regarding the limitations of the present study, the principal limitation is the retrospective nature of this study, although care was taken to select the patients in a

rigid chronological order to reduce any selection bias as much as possible. The selected sample comprised more females (n= 16) than males (n= 6), but this reflects the normal gender difference for the incidence of palatally displaced canines [2]. Moreover, age and gender do not significantly alter the ossification of the interclinoid ligament [18,24,37].

The clinical importance of the present findings is associated with the fact that the shortening of the interclinoid distance due to calcification of the interclinoid ligament is independent of age [18,24,37], as this calcification process is completed during very early childhood [35]. Therefore, it could be used as a useful prognostic factor for palatally displaced canines, because it can be seen before any signs of an abnormal eruptive pathway of the canine can be detected. Further studies would be needed to investigate if a large sample of patients showing a sella bridging and an increased SNA angle will show an increased number of palatally displaced canines, compared to controls with a normal sella turcica and a normal SNA angle. This would definitely prove that these two parameters can be used as a predictor of the risk of canine impaction at an early stage of development: children diagnosed with sella turcica bridging and an increased SNA angle would need a careful monitoring, especially when a familial history of canine impaction is known.

CONCLUSIONS

Growing patients with palatally displaced canines had smaller sella interclinoid distances and a larger SNA angle than control subjects. Future studies are needed to investigate how these observations can be used as prognostic factors for the development of palatally displaced canines.

Funding: This research did not receive any specific grant from funding agencies in the public, commercial, or not-for-profit sectors.

Conflict of interest: The authors declare that they have no conflict of interest.

REFERENCES

1. Ericson S, Kurol J. Early treatment of palatally erupting maxillary canines by extraction of the primary canines. *Eur J Orthod.* 1988;10: 283–95.
2. Sacerdoti R, Baccetti T. Dentoskeletal features associated with unilateral or bilateral palatal displacement of maxillary canines. *Angle Orthod.* 2004;74: 725–732. doi:10.1043/0003-3219(2004)074<0725:DFAWUO>2.0.CO;2
3. Luzzi V, Ierardo G, Corridore D, Di Carlo G, Di Giorgio G, Leonardi E, et al. Evaluation of the orthodontic treatment need in a paediatric sample from Southern Italy and its importance among paediatricians for improving oral health in pediatric dentistry. *J Clin Exp Dent.* 2017;9: e995–e1001. doi:10.4317/jced.54005
4. Bishara SE. Impacted maxillary canines : A review. *Am J Orthod Dentofac Orthop.* 1992;101: 159–171.
5. Naoumova J, Kurol J, Kjellberg H. Extraction of the deciduous canine as an interceptive treatment in children with palatal displaced canines - part I: Shall we extract the deciduous canine or not? *Eur J Orthod.* 2015;37: 209–218. doi:10.1093/ejo/cju040
6. Naoumova J, Kurol J, Kjellberg H. A systematic review of the interceptive treatment of palatally displaced maxillary canines. *Eur J Orthod.* 2011;33: 143–149. doi:10.1093/ejo/cjq045
7. Di Carlo G, Saccucci M, Ierardo G, Luzzi V, Occasi F, Zicari AM, et al. Rapid Maxillary Expansion and Upper Airway Morphology: A Systematic Review on the Role of Cone Beam Computed Tomography. *Biomed Res Int.* 2017;2017: 5460429. doi:10.1155/2017/5460429
8. Di Palma E, Tepedino M, Chimenti C, Tartaglia GM, Sforza C. Longitudinal effects of rapid maxillary expansion on masticatory muscles activity. *J Clin Exp Dent.* 2017;9: e635–e640. doi:10.4317/jced.53544
9. Tepedino M, Iancu-Potrubacz M, Ciavarella D, Masedu F, Marchione L, Chimenti C. Expansion of permanent first molars with rapid maxillary expansion

- appliance anchored on primary second molars. *J Clin Exp Dent*. 2018;10: e241–e247. doi:10.4317/jced.54585
10. Iancu Potrubacz M, Chimenti C, Marchione L, Tepedino M. Retrospective evaluation of treatment time and efficiency of a predictable cantilever system for orthodontic extrusion of impacted maxillary canines. *Am J Orthod Dentofac Orthop*. 2018;154: 55–64. doi:10.1016/j.ajodo.2017.10.027
 11. Tepedino M, Chimenti C, Masedu F, Iancu Potrubacz M. Predictable method to deliver physiologic force for extrusion of palatally impacted maxillary canines. *Am J Orthod Dentofac Orthop*. 2018;153: 195–203. doi:10.1016/j.ajodo.2017.05.035
 12. Tepedino M, Masedu F, Chimenti C. Comparative evaluation of insertion torque and mechanical stability for self-tapping and self-drilling orthodontic miniscrews – an in vitro study. *Head Face Med*. 2017;13: 1–7. doi:10.1186/s13005-017-0143-3
 13. Stewart JA, Heo G, Glover KE, Williamson PC, Lam EW m, Major PW. Factors that relate to treatment duration for patients with palatally impacted maxillary canines. *Am J Orthod Dentofac Orthop*. 2001;119: 216–225. doi:10.1067/mod.2001.110989
 14. Naoumova J, Kürol J, Kjellberg H. Extraction of the deciduous canine as an interceptive treatment in children with palatally displaced canines - part II: Possible predictors of success and cut-off points for a spontaneous eruption. *Eur J Orthod*. 2015;37: 219–229. doi:10.1093/ejo/cju102
 15. Laurenziello M, Montaruli G, Gallo C, Tepedino M, Guida L, Perillo L, et al. Determinants of maxillary canine impaction: Retrospective clinical and radiographic study. *J Clin Exp Dent*. 2017;9: e1304–e1309. doi:10.4317/jced.54095
 16. Peck S, Peck L, Kataja M. The palatally displaced canine as a dental anomaly of genetic origin. *Angle Orthod*. 1994. pp. 249–56. doi:10.1043/0003-3219(1994)064<0249:WNID>2.0.CO;2

17. Rutledge MS, Hartsfield JK. Genetic Factors in the Etiology of Palatally Displaced Canines. *Semin Orthod*. 2010;16: 165–171.
doi:10.1053/j.sodo.2010.05.001
18. Leonardi R, Barbato E, Vichi M, Caltabiano M. A sella turcica bridge in subjects with dental anomalies. *Eur J Orthod*. 2006;28: 580–585. doi:10.1093/ejo/cjl032
19. Haji Ghadimi M, Amini F, Hamed S, Rakhshan V. Associations among sella turcica bridging, atlas arcuate foramen (ponticulus posticus) development, atlas posterior arch deficiency, and the occurrence of palatally displaced canine impaction. *Am J Orthod Dentofac Orthop*. 2017;151: 513–520.
doi:10.1016/j.ajodo.2016.08.024
20. Baidas LF, Al-Kawari HM, Al-Obaidan Z, Al-Marhoon A, Al-Shahrani S. Association of sella turcica bridging with palatal canine impaction in skeletal Class I and Class II. *Clin Cosmet Investig Dent*. 2018;10: 179–187.
doi:10.2147/CCIDE.S161164
21. Divya S, Urala A, Prasad GI, Pentapati K. Sella turcica bridging a diagnostic marker for impacted canines and supernumerary teeth. *J Int Oral Heal*. 2018;10: 94. doi:10.4103/jioh.jioh_276_17
22. Dixit S, Kafle D, Bornstein M, Sanjel S. Sella Turcica Bridging as a Predictor of Dentofacial Anomalies: A Cephalometric Analysis. *Orthod J Nepal*. 2018;7: 32–36. doi:10.3126/ojn.v7i2.20162
23. Majeed O, Quadeer T, Habib M. Relationship Between Palatally Impacted Canines and Sella Turcica Bridging. *J Pakistan Dent Assoc*. 2018;27: 160–164.
doi:10.25301/jpda.274.160
24. Ali B, Shaikh A, Fida M. Association between sella turcica bridging and palatal canine impaction. *Am J Orthod Dentofac Orthop*. 2014;146: 437–441.
doi:10.1016/j.ajodo.2014.06.010
25. Kjaer I, Fischer-Hansen B. The adeno-hypophysis and the cranial base in early human development. *J Craniofac Genet Dev Biol*. 1995;15: 157–61.
26. Meyer-Marcotty P, Reuther T, Stellzig-Eisenhauer A. Bridging of the sella

- turcica in skeletal Class III subjects. *Eur J Orthod.* 2010;32: 148–153.
doi:10.1093/ejo/cjp081
27. Dasgupta P, Sen S, Srikanth HS, Kamath G. Sella Turcica Bridging As A Predictor Of Class II Malocclusion–An Investigative Study. *J Stomatol Oral Maxillofac Surg.* 2018; doi:10.1016/j.jormas.2018.05.005
 28. Dupont W, Plummer W. Power and Sample Size Calculations: A Review and Computer Program. *Control Clin Trials.* 1990;11: 116–128.
 29. Kantor ML, Norton LA. Normal radiographic anatomy and common anomalies seen in cephalometric films. *Am J Orthod Dentofacial Orthop.* 1987;91: 414–26.
 30. Skrzat J, Walocha J, Jaworek J, Mròz I. The clinical significance of the petroclinoid ligament. *Folia Morphol.* 2007;66: 39–43.
 31. Skrzat J, Szewczyk R, Walocha J. The ossified interclinoid ligament. *Folia Morphol.* 2006;65: 242–245.
 32. Skrzat J, Mroz I, Marchewka J. Bridges of the sella turcica - anatomy and topography. *Folia Med Cracov.* 2012;52: 97–101.
 33. Kjær I. Sella turcica morphology and the pituitary gland - A new contribution to craniofacial diagnostics based on histology and neuroradiology. *Eur J Orthod.* 2015;37: 28–36. doi:10.1093/ejo/cjs091
 34. Axelsson S, Storhaug K, Kjær I. Post-natal size and morphology of the sella turcica. Longitudinal cephalometric standards for Norwegians between 6 and 21 years of age. *Eur J Orthod.* 2004;26: 597–604. doi:10.1093/ejo/26.6.597
 35. Becktor JP, Einersen S, Kjaer I. A sella turcica bridge in subjects with severe craniofacial deviations. *Eur J Orthod.* 2000;22: 69–74.
 36. Leonardi R, Farella M, Cobourne MT. An association between sella turcica bridging and dental transposition. *Eur J Orthod.* 2011;33: 461–465.
doi:10.1093/ejo/cjq106
 37. Scribante A, Sfondrini MF, Cassani M, Fraticelli D, Beccari S, Gandini P. Sella turcica bridging and dental anomalies: is there an association? *Int J Paediatr*

Dent. 2017;27: 568–573. doi:10.1111/ipd.12301

38. Ortiz PM, Tabbaa S, Flores-Mir C, Al-Jewair T. A CBCT Investigation of the Association between Sella-Turcica Bridging and Maxillary Palatal Canine Impaction. *Biomed Res Int.* 2018;2018. doi:10.1155/2018/4329050
39. Mercuri E, Cassetta M, Cavallini C, Vicari D, Leonardi R, Barbato E. Skeletal features in patient affected by maxillary canine impaction. *Med Oral Patol Oral Cir Bucal.* 2013;18: e597-602. doi:10.4317/medoral.18746
40. Basdra EK, Kiokpasoglou M, Stellzig A. The Class II division 2 craniofacial type is associated with numerous congenital tooth anomalies. *Eur J Orthod.* 2000;22: 529–535. doi:10.1093/ejo/22.5.529
41. Larsen H, Sorensen H, Artmann L, Christensen I, Kjaer I. Sagittal , vertical and transversal dimensions of the maxillary complex in patients with ectopic maxillary canines. *Orthod Craniofac Res.* 2010;13: 34–39.

Table I. Descriptive statistics for cephalometric variables of both groups

Variable	Study group (n= 22)		Control group (n=22)	
	Mean ± SD	Normality test†	Mean ± SD	Normality test†
SN-GoMe (°)	31.1 ± 6.5	n.s	32.1 ± 5.5	n.s
SNA (°)	86.0 ± 4.7	n.s	82.8 ± 4.8	n.s
ANB (°)	6.9 ± 2.0	n.s	5.3 ± 3.9	n.s
SN-U1 (°)	100.1 ± 12.1	n.s	104.4 ± 9.6	n.s
S-N (mm)	67.2 ± 6.0	n.s	67.6 ± 7.9	n.s
Go-Me (mm)	72.8 ± 7.9	n.s	71.5 ± 8.6	n.s

*statistically significant with $p < 0.05$; †p value from Kolmogorov-Smirnov normality test.

Table II. Descriptive statistics and Independent Samples T-test for sella measurements between the two groups

Variable	Study group (n= 22)	Control group (n= 22)	Mean difference	P value
Sagittal interclinoid distance (mm)	3.2 ± 1.2	5.3 ± 2.2	-2.1 ± 0.5**	<0.001†
Sella depth (mm)	6.3 ± 1.3	7.1 ± 1.2	-	0.061‡
Sella diameter (mm)	7.0 ± 1.7	7.7 ± 1.4	0.7 ± 0.5	0.161†

**statistically significant with $p < 0.05$; **statistically significant with $p < 0.01$; †p value from Independent Samples T-test; ‡p value from Mann-Whitney U-test.*

Table III. Independent Samples T-test for cephalometric variable between Study group (n= 22) and Control group (n= 22)

Variables	Mean difference	Standard error	p value	95% Confidence interval	
				Lower bound	Upper bound
SN-GoMe (°)	0.9	1.9	0.624	-2.9	4.8
SNA (°)	-3.1*	1.5	0.047	-6.2	-0.1
ANB (°)	-1.7	1	0.094	-3.7	0.3
SN-U1 (°)	4.3	3.5	0.221	-2.7	11.3
S-N (mm)	0.4	2.2	0.867	-4.1	4.9
Go-Me (mm)	-1.3	2.6	0.61	-6.7	4

**statistically significant with $p < 0.05$.*

Table IV. Pearson correlation between craniofacial and sella morphology

		Study group (n= 22)	Control group (n= 22)	
<i>SNA</i>		Sella interclinoid distance	SNA	Sella interclinoid distance
<i>SNA</i>	1	-0.52* (0.017)	1	0.07 (0.746)

*Pearson correlation (p value); *statistically significant for $p < 0.05$.*

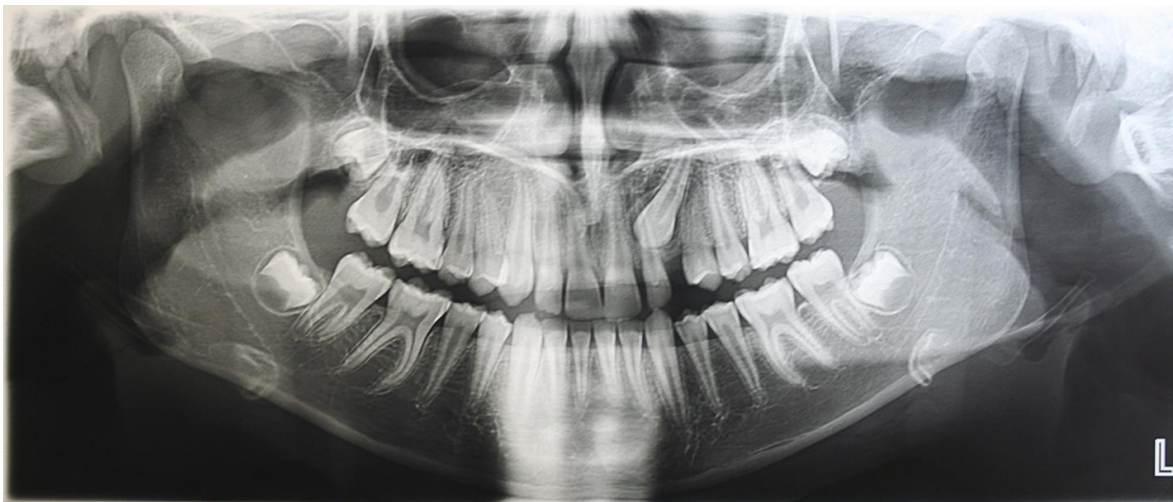


Figure 1. Panoramic radiograph of a patient showing a palatally displaced upper left maxillary canine.

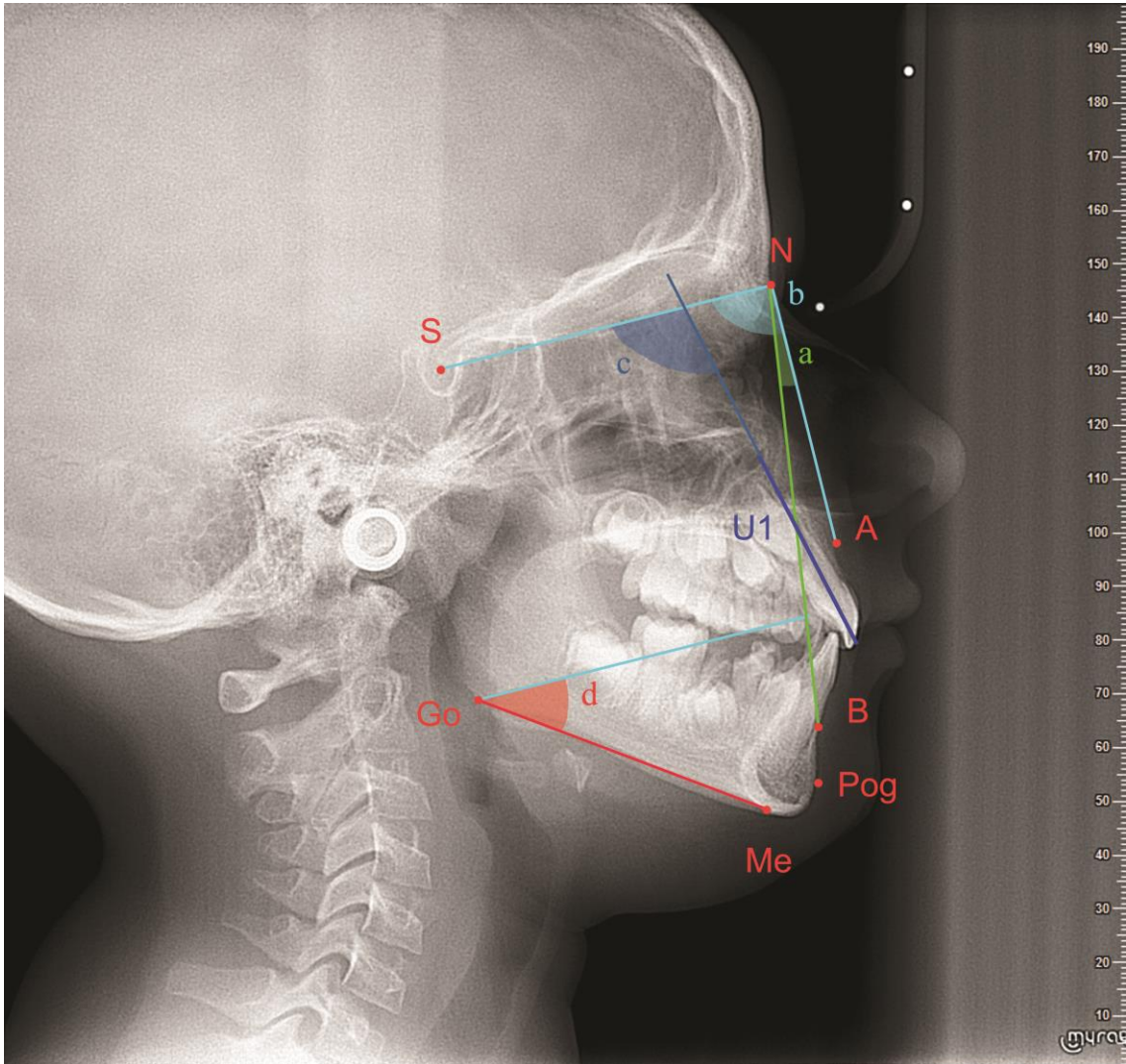


Figure 2. Cephalometric landmarks and angular measurements. S, sella point; N, skeletal Nasion point; A, skeletal A-point; B, skeletal B-point; Pog, skeletal Pogonion point; Me, skeletal Menton point; Go, Gonion point; U1, long axis of the central upper incisor; a, angle between A-point, Nasion, and B-point; b, angle between Sella, Nasion, and A-point; c, angle between the Sella-Nasion plane and the long axis of the upper central incisor; d, angle between the Sella-Nasion plane (light blue line, transposed to Gonion point) and the Gonion-Menton plane.

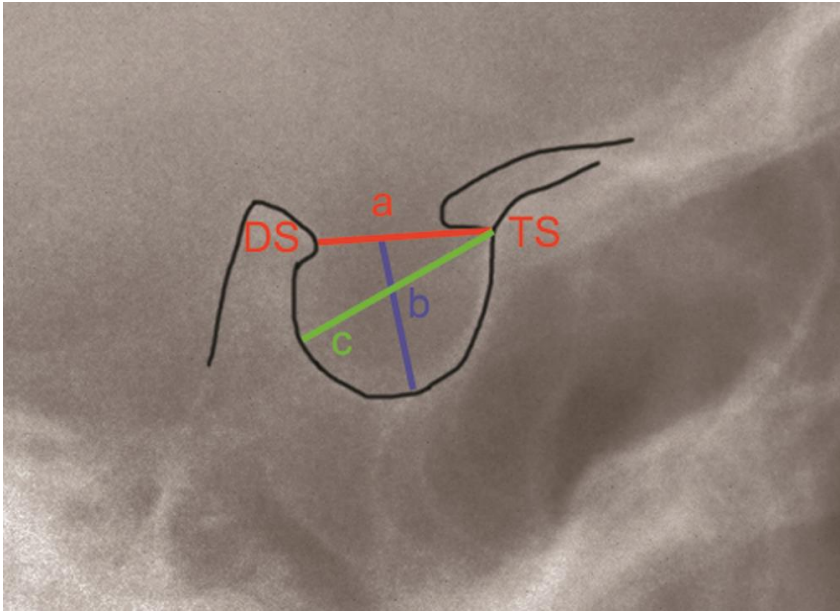


Figure 3. Sella measurements. DS, dorsum sellae; TS, tuberculum sellae; a, interclinoid distance; b, sella depth; c, sella diameter.