

Efficacy of erythropoietin-pretreated mesenchymal stem cells in murine burn wound healing: possible in vivo transdifferentiation into keratinocytes

R.A. Imam¹, A.A.-E. Rizk^{1, 2}

¹Departement of Anatomy and Embryology, Faculty of Medicine, Cairo University, Cairo, Egypt

²Faculty of Medicine (Rabigh), King AbdulAziz University (KAU), +96 Rabigh, Saudi Arabia

[Received: 15 January 2019; Accepted: 1 March 2019]

Background: Stem cells have shown promising potential to treat burn wounds. Erythropoietin was capable of promoting *in vitro* transdifferentiation of mesenchymal stem cells (MSCs). The aim of the study was to investigate possible role of erythropoietin-pretreated mesenchymal stem cells (EPOa/MSCs) in burn wounds healing and to evaluate its *in vivo* differentiation into keratinocytes.

Materials and methods: Forty rats were utilised in this study divided into four groups ($n = 10$ for each). Control group (I), burn group (II), burn + MSCs, group (III), burn + EPOa/MSCs. 1×10^6 cells were injected locally for each 1 cm^2 of burn areas. Burn areas were followed-up morphologically. After 21 days of the experiment, the rats were euthanised, skin specimens were assessed biochemically, histologically and immunohistochemically.

Results: EPOa/MSCs enhanced significantly ($p < 0.05$) burn wound vimentin gene expression and level of interleukin (IL)-10 while decreased IL-1 and COX2 as compared to the burn group. Histologically, EPOa/MSCs improved epithelialisation despite stem cells' differentiation into keratinocytes was rarely detected by PKH26 red fluorescence. EPOa/MSCs promoted angiogenesis as detected by significant increase in VEGF and PDGF immunoexpression as compared to burn group.

Conclusions: EPOa/MSCs may improve burn wound healing, probably through anti-inflammatory, immunomodulatory and angiogenic action. However, *in vivo* transdifferentiation into keratinocytes was rarely detected. (Folia Morphol 2019; 78, 4: 798–808)

Key words: erythropoietin, stem cells, keratinocytes, burn-rats

INTRODUCTION

Stem cells, by pronounced anti-inflammatory and angiogenic role, can improve wound healing through differentiation into skin cells. For so, stem cells have shown promising potential to treat burn wounds [21]. The unique abilities of mesenchymal stem cells (MSCs) to suppress the immune response, to secrete a large number of cytokines and chemokines, together

with their potential for multilineage differentiation make them suitable for tissue regeneration through cell replacement and repair [15]. Mobilisation of bone marrow-derived mesenchymal stem cells (BM-MSCs) regulated via CXCL12/CXCR4 signalling had promoted BM-MSCs migration into the burn wound margins enhancing re-epithelialisation [11]. Through reducing unhealed areas, and enhancement of the

Address for correspondence: Dr. R.A. Imam, Department of Anatomy and Embryology, Faculty of Medicine, Cairo University, Kasr Alainy, Cairo, Egypt, e-mail: abdelnasserreada@gmail.com

dermal thickness, epidermal area as well as collagen content, allogeneic MSCs had been demonstrated to improve burn wound healing [5]. In the study of Liu et al. [19], a burn wound model was developed in pigs; tissue-engineered skin containing autologous MSCs was grafted on deep partial thickness wounds. They found that when stem cells were grafted onto the burn wounds, these substitutes had less contraction, more vascularisation, and improved epidermal formation. A lot of methods had been done to potentiate the efficacy of stem cells in burn healing either by incorporation into tissue engineered scaffolds, by gene modification or by pretreatment with proliferating agents. It had been proved that MSCs-pretreated with platelets rich plasma (PRP) improved the histopathology of burned skin 20 days post burn through upregulation of transforming growth factor beta (TGF- β), interleukin (IL)-10, angiopoietin-1, angiopoietin-2 and vimentin while downregulation of tumour necrosis factor-alpha (TNF- α), matrix metalloproteinase-1 and tissue inhibitor of metalloproteinase-2 [10]. Transplantation of genetically modified bone marrow MSCs with TGF- β 3 in an animal model had remarkably improved wound healing and reduced skin scar tissue formation providing an alternative in the treatment of extensive scar tissue formation after soft tissue injury [17]. In addition to erythropoietin (EPOa) primary biological role in erythropoiesis, it acts as a paracrine and/or autocrine agent as a response to cellular stress [31]. Recently, recombinant human alpha-erythropoietin had been proved to accelerate cell proliferation and to promote endothelial transdifferentiation of human MSCs from the apical papilla (SCAP) [15]. Despite the promising results of MSCs in burn wound healing, the pathophysiological mechanisms mediating this action remains a challenge due to in vivo limitation of monitoring MSCs dynamics [23]. In this work, it was hypothesised that EPOa pretreated MSCs could improve burn wound healing. The aim of this work was to investigate this role and to evaluate its in vivo differentiation into keratinocytes.

MATERIALS AND METHODS

Animals

The experiment strictly adhered to all ethical guidelines regarding animal research and was approved by the Institutional Animal Care and Use Committee of Cairo University (CU-IACUC) number CU-III-F-47-18. Forty adult male albino rats weighing 200–250 g were

used in this experiment. Animals were obtained from Animal House, Faculty of Medicine, Cairo University. They were housed under standard laboratory and environmental conditions, 20–23°C, 40–60% humidity, 12 h light–dark cycle, with free access to food and water and fed ad libitum.

Experimental design

Forty animals were utilised divided into four equal groups:

- group I (n = 10): control group, skin was shaved and left for 3 weeks;
- group II (n = 10): burn induction without mesenchymal cells injection;
- group III (n = 10): burn induction + immediate local injection of MSCs 1 mL (1×10^6 cells) for each 1 cm² of burn area;
- group IV (n = 10): burn induction + immediate local injection of EPOa/MSCs 1 mL (1×10^6 cells) for each 1 cm² of burn area.

Preparation of BM-MSCs from rats

The MSCs were obtained from the Biochemistry Department, Faculty of Medicine, Cairo University. They were derived from rats as previously described by Schrepfer et al. [26]. Ten rats were euthanised after administration of sodium pentobarbital intraperitoneally at a dose of 30 mg/kg. After cleaning from adherent tissues, the tips of femurs and tibiae were cut with a bone cutter. Bone marrow cells were flushed from the medullary cavities of the femurs and tibiae and disaggregated into a single-cell suspension by sequential passage through a 23-gauge needle. This single cell suspension was cultured in 15 mL of MSCs specific medium; minimum essential medium supplemented with 10% foetal bovine serum and penicillin/streptomycin, Gibco) in T-75 culture flasks at 37°C in 5% carbon dioxide incubator. Three to four days later, non-adherent cells were removed by changing the medium. After 10 days in culture, adherent cells formed homogenous fibroblast-like colonies. When MSCs become confluent (80–90%), adherent cells were passaged with trypsin (0.25%) by incubating for 10 min. Three passages were done to obtain the optimal number of MSCs before transplantation. The de-adhered cells after trypsin treatment were collected in a 15 mL falcon tube and centrifuged at 480 g for 5 min and these cells were counted and tested for viability by trypan blue.

Flow cytometry analysis of cell surface markers

Immunophenotyping of BM-MSCs cell was examined by flow cytometry for CD34, CD29 and CD90 (BD Bioscience, USA). The cells were incubated at room temperature for 30 min with the previous monoclonal antibodies, labelled with fluorescein isothiocyanate (FITC) and analysed on a flow cytometer (FACS Caliber, BD Bioscience USA) [12, 27]. BM-MSCs cells exhibited negative reaction for the haematopoietic marker (CD34), while strong positive reaction for MSC specific markers including CD29 and CD90 (Fig. 1).

MSCs treatment with erythropoietin

Mesenchymal stem cells growth was divided into two equal fractions, each fraction represented a group:

- group 1: a control group of MSCs which were not treated with EPOa;
- group 2: MSCs that were treated with EPOa (Eprex® injectable solution 10.000 IU/mL, Janssen-Cilag Pty Ltd.). MSCs were seeded at 4×10^3 cells/cm² in tissue culture plates and incubated with the culture medium supplemented with EPOa (40 IU/mL) for 24 h [15].

The cells were examined for cell proliferation assay using the MTT (3-[4,5-dimethylthiazol-2-yl]-2,5-diphenyl tetrazolium bromide) cell proliferation kit (Trevigen Inc., Gaithersburg, MD, USA) as per manufacturer's protocol. Then MSCs were labelled with PKH26 red fluorescent linker dye supplied by Sigma (Saint Louis, Missouri, USA) for homing detection, and used for injection in the treated groups. MSCs 1×10^6 in 1 mL of phosphate buffer saline, pH 7.4, were administered to the groups treated with cells for each 1 cm² of the burn area.

Burn induction

Rats were anaesthetised with single intramuscular injection of 5% ketamine HCl (ketamine hydrochloride, Rotexmedica, Germany) (35.0 mg/kg) after injection of 2% xylazine HCl (VMD, Belgium) (5.0 mg/kg) via the quadriceps group of muscles [7]. The backs of the rats were shaved, prepared and skin burns were made by using a stainless steel tuning fork weighing 51 g with a rounded end (Fig. 2). After immersing in boiling (100°C) water for 5 min to induce full-thickness third-degree skin burns, the rounded end of tuning fork was applied without pressure for 15 s (proved histologically to produce full-thickness burn based on preliminary tests) on the back of the rats. This burn model was in close

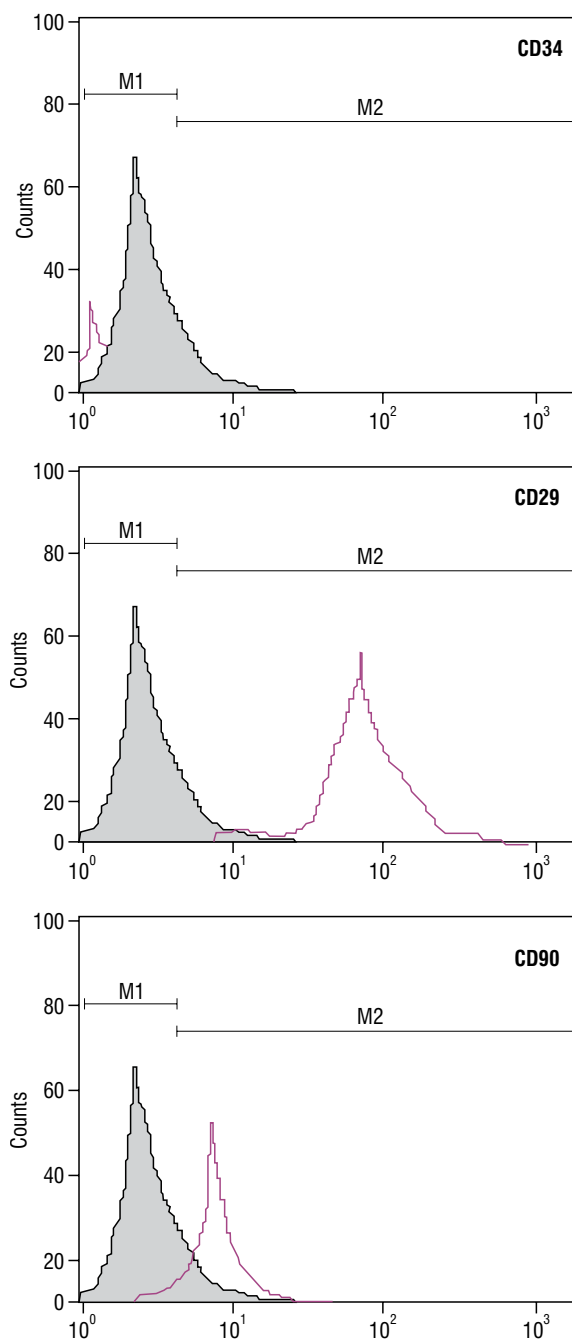


Figure 1. Flow cytometry of mesenchymal stem cells (MSCs). The pink histograms represent antibody-labelled cells while the grey histograms show the profile of the isotype control. Bone marrow-derived MSCs cells exhibited negative reaction for CD34, while strong positive reaction for CD29 and CD90.

similarity to that described by Motamed et al. [22]. Daily rats' observation for signs of discomfort had been performed and analgesics (Meloxicam, 20 mg/kg SC; Mobitil, MUP, Egypt) were given as needed for the first 5 days [30]. Following the burning, each animal was placed in a separate cage. As to pre-

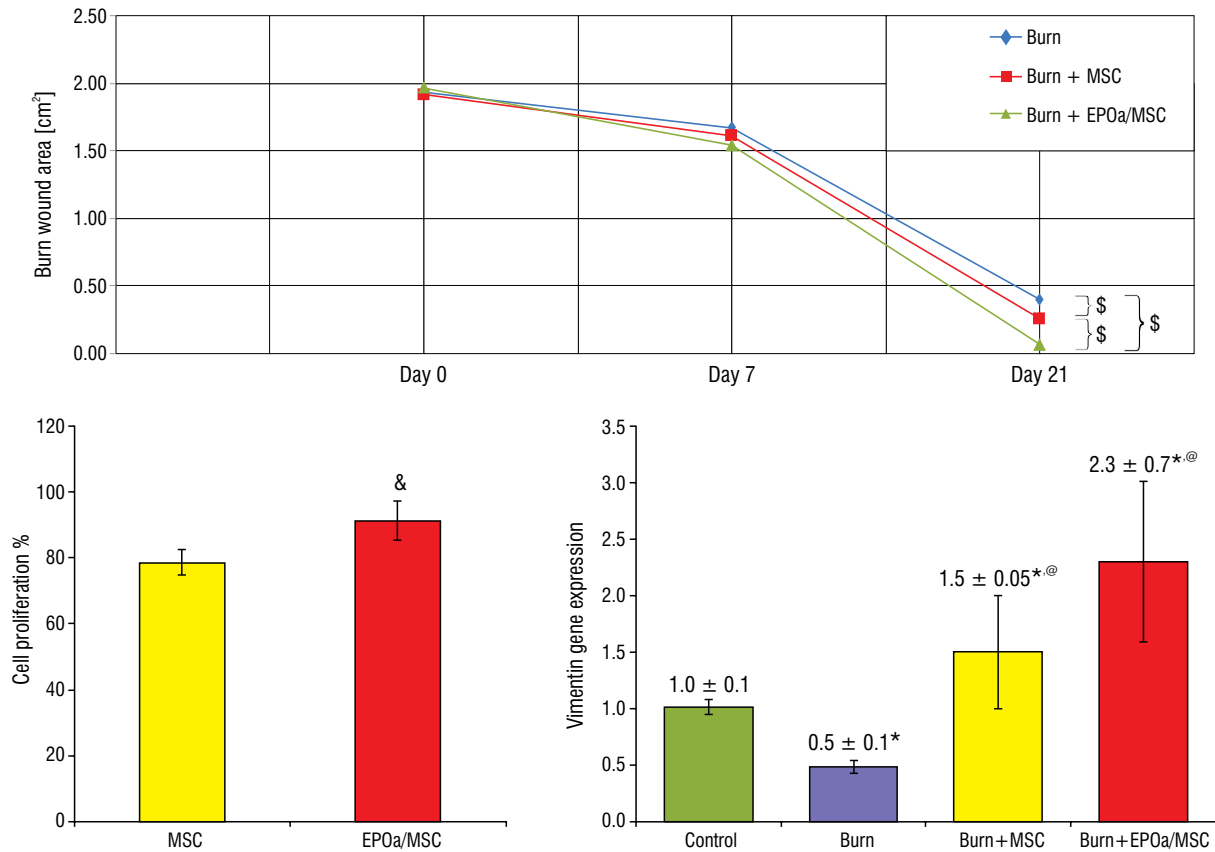


Figure 2. Histograms of burn areas in cm², cell proliferation % and vimentin gene expression; ^{*}statistically significant differences in burn areas between the different groups; [&]statistically significant difference in cell proliferation between mesenchymal stem cells (MSCs) and erythropoietin-pretreated mesenchymal stem cells (EPOa/MSCs) between the different groups; ^{*}statistically significant as compared to control; [@]statistically significant as compared to burn group.

vent burn wound infection, cefazolin 15 mg/kg subcutaneous was given for the first 5 days [1, 19]. Skin burn areas were photographed at day 0, 7 and 21 days from the experiment with measurement of the burn areas from scanned images using ImageJ Software (NIH, USA) starting within 2 h of burn injury for determination of original wound area (day 0) [30]. The rats were euthanised after 3 weeks from the experiment by intraperitoneal injection of pentobarbital 150 mg/kg. Skin burn specimens were obtained processed for biochemical, histological and immunohistochemical examination.

Biochemical analysis

Skin and burn wound specimens homogenates were used for estimation of COX2, IL-1, and IL-10 by ELISA supplied by MyBiosource, USA. Gene expression for vimentin was assessed by real-time polymerase chain reaction (RT-PCR). Total RNA was extracted from skin tissue homogenate using SV Total RNA Isolation System (Promega, Madison, WI, USA). Extracted RNA

was quantified by spectrophotometer at 260 nm the total RNA was used for cDNA conversion using high capacity cDNA reverse transcription kit (#K1621, Fermentas, USA). cDNA was generated from 10 µL of total RNA extracted with 3 µL antisense primer and 1 µL superscript MMLV reverse transcriptase for 60 min at 37°C. The relative abundance of mRNA species was assessed using the SYBR Green method on an ABI prism 7500 sequence detector system (Applied Biosystems, Foster City, CA). The forward primer for Vimentin was 5'-GCACCCTGCAGTCATTGAGA-3' with the Reverse primer: 5'-GCAAGGATTCCACTTTACGTTCA-3' and Gene bank accession number (XM_007624597.2). All primer sets had a calculated annealing temperature of 60°C. Quantitative RT-PCR was performed in duplicate in a 25 µL reaction volume consisting of 12.5 µL SYBR Green PCR Master mix, 1 µL of each primer and 5 µL of cDNA. Amplification conditions were 2 min at 50° and 40 cycles of 15 s at 95°, 1 min at 60° and 1 min at 72°C for the amplification step. Relative expression of vimentin was calculated using the comparative cycle

threshold method ($\Delta\Delta Ct$). All values were normalised to the GAPDH genes and reported as fold change.

Histological examination

The skin specimens were prepared for histological staining using haematoxylin and eosin (H&E) as well as Masson's trichrome stains.

Immunohistochemical examination

Deparaffinised sections were mounted on positively charged slides for staining with smooth muscle actin (SMA), vascular endothelial growth factor (VEGF) and platelets derived growth factor (PDGF). Heat-induced epitope retrieval (HIER) was done to the sections. Dako autostainer was used for immunohistochemistry [13, 25]. Sections were EnVision Flex peroxidase blocked. Primary antibodies were VEGF (Santa Cruz, USA), α SMA (Dako, Denmark) and PDGF (Genetex, USA). Dako EnVision Flex/HRP had been used as secondary antibodies. Visualisation had been performed with EnVision FLEX DAB+ Chromogen. Prepared sections from H&E, Masson's trichrome and immunohistochemical stains were photographed using a Canon digital camera (Canon, Japan) attached to the IBM computer system.

Histomorphometric analysis

The software Leica Quin 500, Germany, was used in performing image analysis for measuring the area per cent of positive immunohistochemical reactions of VEGF, PDGF and α SMA at a magnification $\times 400$. ImageJ was used in counting the PKH26 fluorescent particles in different groups at the same magnification. All data were expressed as mean \pm standard deviation and processed for statistical analysis

Statistical analysis

All histomorphometric measurements, as well as the sizes of burn area were statistically analysed using the statistical package for the social sciences (SPSS) version 21.0 (IBM Corporation, Somers, NY, USA) statistical software. Statistical evaluation was done using analysis of variance (ANOVA) followed by *post hoc* Tukey test. Significance was considered when the *p*-value was less than 0.05.

RESULTS

Proliferation assay test

There was a significant increase ($p < 0.05$) in the per cent of cell proliferation of EPOa/MSCs as compared to the control group (MSCs only) (Fig. 2).

Clinical wound observations

Rats that received MSCs and EPOa/MSCs at day 21 from burn induction showed better healing and epithelialisation as compared to those didn't receive without a noticeable difference at day 7 from burn induction (Fig. 3). There was a significant decrease in burn area in rats that received MSCs and EPOa/MSCs only at day 21 from burn induction with a statistically nonsignificant decrease at day 7 from burn induction (Fig. 2). The rats treated with EPOa/MSCs exhibited significant decrease in burn area as compared to those treated with MSCs (Fig. 2).

Biochemical results

Mesenchymal stem cells and EPOa/MSCs significantly down-regulated IL-1B and COX2 while significantly up-regulated IL-10 in skin burn tissues of rats that receive them as compared to those that didn't receive them (Table 1). EPOa/MSCs-treated group exhibited a significant decline in IL-1B and a significant increase in IL-10 as compared to MSCs-treated group (Table 1). Vimentin gene expression in burn group was significantly decreased as compared to the control group (Fig. 2). MSCs and EPOa/MSCs significantly up-regulated vimentin gene expression as compared to burn group (Fig. 2).

Histological results

On H&E staining (Fig. 4), control rats appeared with normal skin histology. The burn group showed granulation tissue with abundant fibrocytes. MSCs-treated group exhibited a partially healed epidermis with cellular inflammatory infiltrate. EPOa/MSCs-treated group showed apparently intact epidermis with areas of hyperkeratinisation. On Masson's trichrome staining (Fig. 4), control rats appeared with normal amount of collagen while burn group showed totally replaced skin by granulation tissue. MSCs group exhibited regenerating skin with modelling collagen fibres while EPOa/ MSCs-treated group appeared with well-modelled collagen fibres.

Immunohistochemical results

Immunohistochemical staining (Fig. 5) revealed burn group with decreased VEGF and PDGF immunoeexpression while increased α SMA immunoeexpression. MSCs and EPOa/ MSCs group exhibited decreased α SMA immunoeexpression while increased dermal VEGF and PDGF immunoeexpression as compared to burn group.

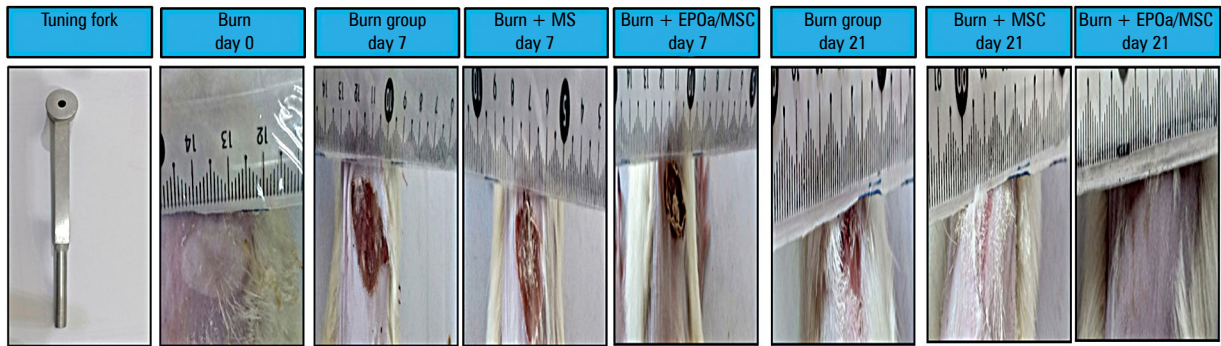


Figure 3. The tuning fork used in burn induction. Rats that received mesenchymal stem cells and erythropoietin-pretreated mesenchymal stem cells (EPOa/MSCs) at day 21 showed a better healing and epithelialisation as compared to those that didn't receive these treatments without a noticeable difference at day 7.

Table 1. Inflammatory markers among different groups

Group	COX2 [pg/mg protein]	Intereukin-1B [pg/mg protein]	Interleukin-10 [pg/mg protein]
Control	43.1 ± 2.6	15.5 ± 2.2	139.5 ± 8.3
Burn	108.7 ± 7*	88.1 ± 5.9*	74.1 ± 4.9*
Burn + MSCs	72.5 ± 5.6*,@	59.1 ± 5.2*,@	104.1 ± 6.9*,@
Burn + EPOa/MSCs	66.4 ± 3.3*,@	44.6 ± 5.4*,@,#	117.9 ± 5.4*,@,#

MSCs — mesenchymal stem cells; EPOa/MSCs — erythropoietin-pretreated mesenchymal stem cells

*statistically significant as compared to control; @statistically significant as compared to burn group; #statistically significant as compared to burn + MSCs

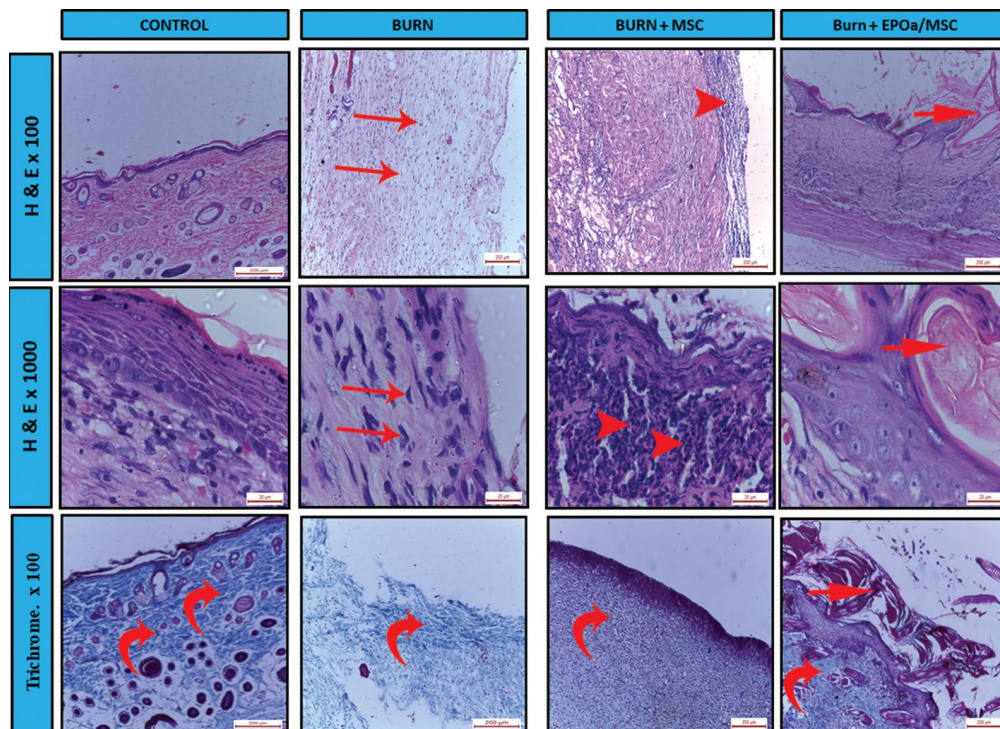


Figure 4. Burn group in haematoxylin and eosin (H&E) sections is showing granulation tissue with abundant fibrocytes (arrows). Stem cells-treated group is showing partially healed epidermis with cellular inflammatory infiltrate (arrow heads). The group that received erythropoietin-pretreated mesenchymal stem cells (EPOa/MSCs) is showing apparently intact epidermis with areas of hyperkeratinisation (incomplete arrow). By Masson's trichrome stain, control group appeared with normal collagen fibres (curved arrows), while burn group is showing granulation tissue. Mesenchymal stem cells group is showing regenerating skin with modelling collagen fibres while EPOa/MSCs group appears with well-modelled collagen fibres.

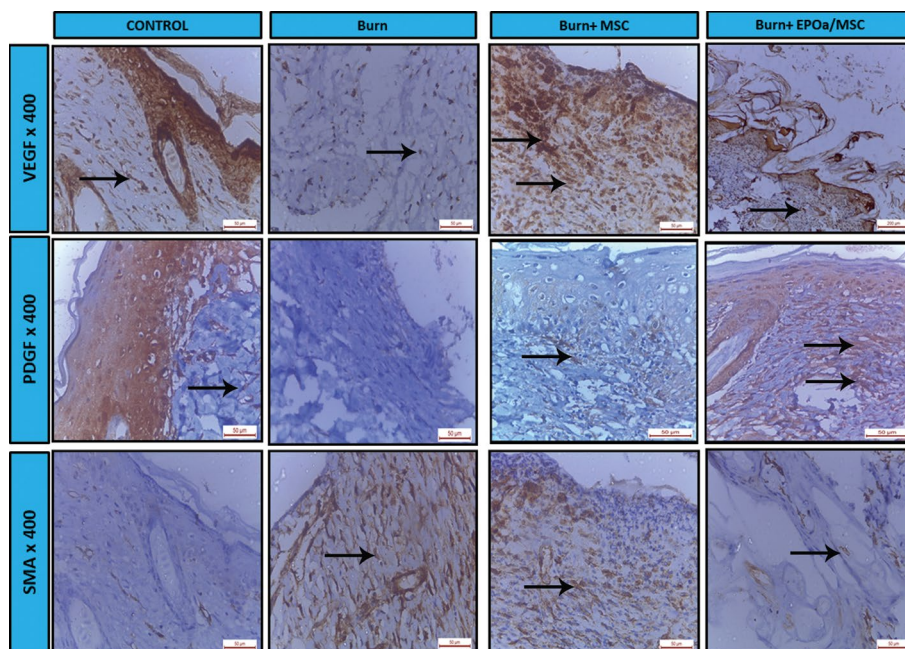


Figure 5. Immunohistochemical stains. Burn group is showing decreased vascular endothelial growth factor (VEGF) and platelets derived growth factor (PDGF) immunoexpression while increased α staining with smooth muscle actin (SMA) immunoexpression (arrows). Mesenchymal stem cells and erythropoietin-pretreated mesenchymal stem cells (EPOa/MSCs) group are showing increased dermal VEGF and PDGF immunoexpression while decreased SMA immunoexpression as compared to burn group.

PKH26 fluorescence results

PKH26 fluorescent detection of labelled stem cells (Fig. 6) revealed negative detection in control and burn groups while positive detection in MSCs-treated group and EPOa/MSCs-treated group. The detection was almost totally in the dermis with the absence of the PKH26 fluorescence in the epidermis.

Histomorphometric results (Fig. 7)

Area % of alpha-SMA positive reaction. It was significantly increased in burn group as compared to the control. Meanwhile, it was significantly decreased in burn + MSCs and burn + EPOa/MSCs groups as compared to the burn group with a more significant decrease in burn + EPOa/MSCs group as compared to burn + MSCs cells group.

Area % of VEGF positive reaction. It was significantly decreased in burn group as compared to the control while significantly increased in MSCs treated and EPOa/MSCs-treated groups as compared to the burn group.

Area % of PDGF positive reaction. It was significantly decreased in burn group as compared to the control while significantly increased in MSCs-treated and EPOa/MSCs-treated groups as compared to the burn group with a more significant increase in

EPOa/MSCs group as compared to MSCs-treated group.

Count of PKH26 fluorescent particles in different groups. It was significantly increased in the dermis of EPOa/MSCs group as compared to MSCs group. However, it was rarely detected in the epidermis of both MSCs and EPOa/MSCs groups.

DISCUSSION

A burn wound is a dynamic process that can deepen in time usually by infection, and thereby increase the total tissue damage and the risk of complications such as hypertrophic scarring [20]. Stem cell therapy had been shown as a promising modality for burn healing. A lot of methods had been done to potentiate stem cell efficacy in burn healing either by incorporation into tissue engineered scaffolds or by pretreatment with proliferating agents. In the current work, pretreatment of mesenchymal stem cells by erythropoietin successfully enhanced their *in-vitro* proliferation, *in-vivo* burn healing as evidenced clinically, histologically and histochemically.

Burn area had significantly decreased in MSCs and EPOa/MSCs groups 21 days following injury as compared to the burn alone group of rats with no statistical significance 7 days from burn induction.

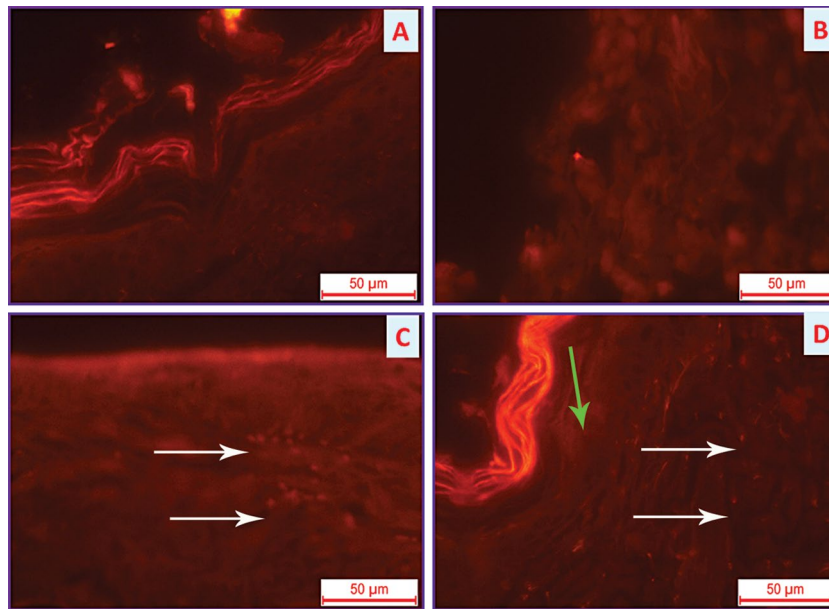


Figure 6. A, B. Control and burn groups respectively with negative PKH26 red fluorescence; C, D. Mesenchymal stem cells-treated group and erythropoietin-pretreated mesenchymal stem cells (EPOa/MSC) group respectively with positive fluorescence (white arrows). Note the lack of fluorescent dye in the epidermis (green arrow); PKH26 red fluorescence $\times 400$.

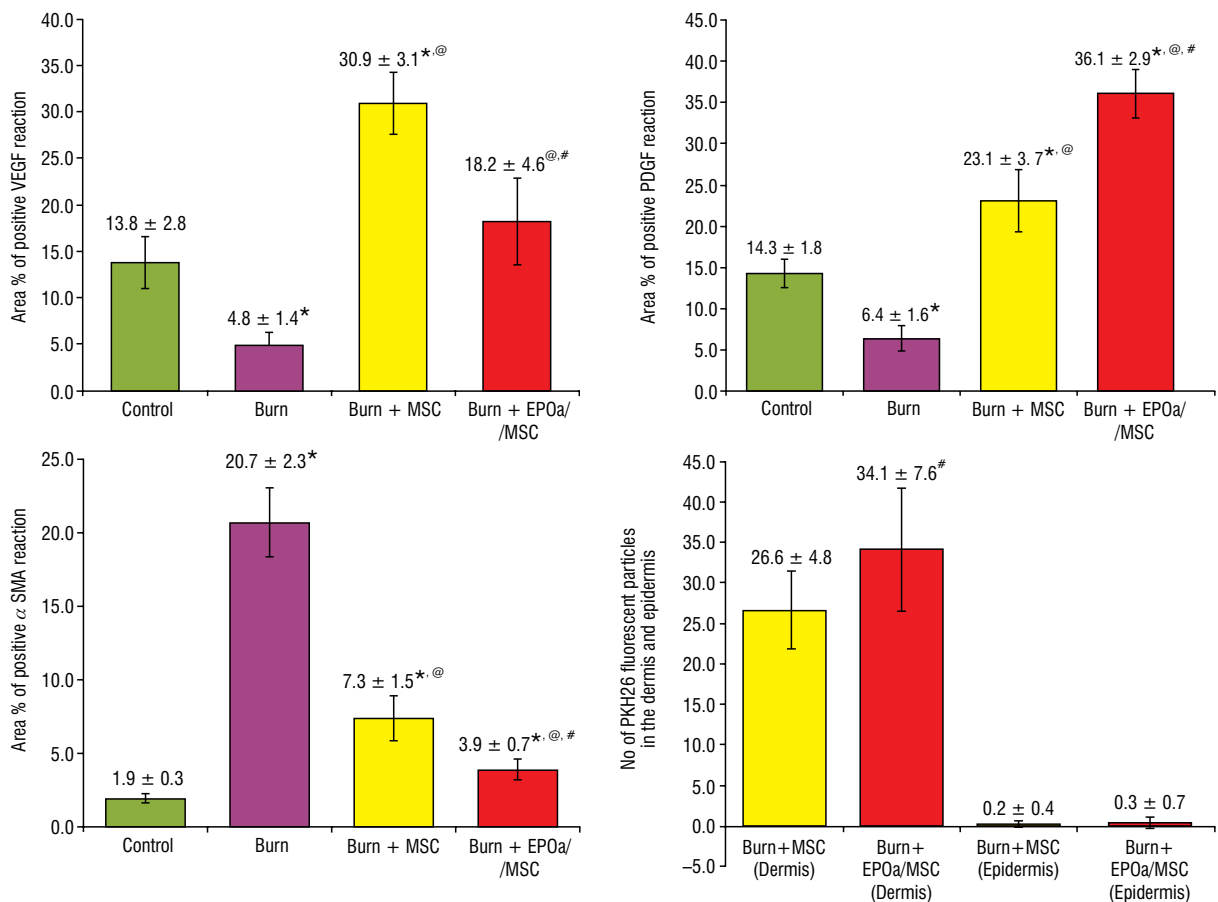


Figure 7. Histograms of area % of positive immunostaining reaction of staining with α smooth muscle actin (SMA), vascular endothelial growth factor (VEGF) and platelets derived growth factor (PDGF) in different groups as well as the number of PKH26 fluorescent particles in different groups; *statistically significant as compared to control; [@]statistically significant as compared to burn group; [#]statistically significant as compared to burn + mesenchymal stem cells.

Partially agreeing with these results, no significant difference in time to wound epithelialisation was observed in adipose-derived stem cells treated versus untreated burn wounds after days 1, 4, 7, 14, 21 from burn induction despite favourable effect on collagen deposition and angiogenesis [2]. The smaller area of starting burn wound (1 cm²) in the latter study might be the cause of not detecting significant difference in wound closure; however, with larger starting burn wound (30% TBSA), the healing time of wounds in the burn transplanted human umbilical cord mesenchymal cells (hUC-MSCs) group was significantly shorter than that in the burn group [18]. It has been reported that rats treated with MSCs after burn injury had a higher percentage of vital tissue at the injury site as well as fewer apoptotic cells and as compared to the control group [24]. Two distinct phenotypes of MSCs were involved in the wound healing process: the pro-inflammatory M1 and the anti-inflammatory M2 [33]. MSC role in the control of cell migration, cytokine secretion and extracorporeal matrix deposition is the result of the switching between both phenotypes which is mediated by different toll-like receptors (TLRs), specifically, stimulation of TLR3 and TLR4 switches the cell between an anti-inflammatory and pro-inflammatory phenotype, respectively [32].

Down-regulation of inflammatory markers COX2 and IL-1B and up-regulation of anti-inflammatory marker IL-10 in the skin tissues burn of EPOa/MSCs group in the present work might clarify the possible mediating mechanism of these MSCs in burn healing. Similarly, there was a local increase in anti-inflammatory cytokines IL-10 and TNF stimulated gene 6 (TSG-6) and decrease in the number of inflammatory cells and pro-inflammatory cytokines (IL-1, IL-6 and TNF- α) at the burn injury site following an intravenous injection of human umbilical cord MSCs [18]. Concordantly, it had been demonstrated that at early time points post-burn, rats treated with MSCs have decreased circulating levels of TNF- α , IL-6, white blood cells and C-reactive protein as compared to the control group [35]. In addition, MSCs have also demonstrated the ability to attenuate T cell activation and proliferation, decrease cytotoxic T cells, and increase immunosuppressive regulatory T cells [8]. Also, murine MSCs were injected intradermally in a rat burn model resulting in an increase in anti-inflammatory cytokines TGF- β and IL-10 in the blood and reduction of CD4+ and CD8+ cells in the spleen as compared to control PBS-treated rats [3]. MSCs had been shown to possess a paracrine

action by secretion of "secretomes" or extracellular vesicles [6]. These secretomes can cause profound immunomodulatory effects when studied *in vitro* experiments by downregulating IL-6 and nitric oxide synthase, promoting M1 (pro-inflammatory) to M2 (anti-inflammatory) polarisation of macrophages, increase IL-10 concentrations, and increase adenosine triphosphate [6].

Vimentin gene expression was significantly increased burn + MSCs or burn + EPOa/MSCs groups as compared to the burn group. In accordance, MSCs and PRP pretreated MSCs had been reported to up-regulate vimentin gene expression in burn wounds [10]. Vimentin is considered as type III intermediate filament that acts as a signal integrator during wound healing, orchestrating the healing process by controlling fibroblast proliferation, TGF- β secretion, collagen accumulation, and epithelial-mesenchymal transition processing [4].

Keratinocytes differentiation of MSCs either alone or EPOa/MSCs into keratinocytes or other epidermal cells was rarely detected in this work by PKH26 fluorescence. Supporting these results, a comparative study between allogeneic MSCs and culture modified monocytes in burn healing had detected that the majority of the MSCs were in the dermis not the epidermis and there was rare evidence of MSC differentiation as seen by co-localisation of MSC with keratin 14 which was not observed in culture modified monocytes [5]. In addition, green fluorescence protein (GFP)-labelled hUC-MSCs injected IV 3 days after burn had been observed to mainly concentrate in the wound edge and wound base on weeks 2 and 3 after hUC-MSCs transplantation [18]. Contradictory to the present work, IV stem cells injection in burned rats followed by tracking of them in lesions immunohistochemically by GFP, had resulted in strong GFP-positive staining in the epidermal region [23]. But this tracking was done early after burn induction and no actual epidermis consisting of keratinocytes appeared in the figures related but granulation tissue instead. Another contradictory research also reported localisation of IV injected stem cells in the epidermis and hair follicles in post burn-injured lesions [11]. Wound site levels of CXCL12 and CXCR4 had been increased in stem cells injected mice in the latter research and mobilisation of MSCs to the wound site had been significantly reduced by pre-treatment of the MSCs with a CXCR4 antagonist thus affecting wound closure [11]. Even though, Recell[®] spray-on system in which a small

sample of the patient's own skin is immersed in the enzyme solution in the RECELL system, which separates the skin cells to produce Spray-On Skin Cells in as little as 30 min with resultant of a suspension including keratinocytes, fibroblasts, and melanocytes, which are involved in wound healing. This Food and Drug Association approved alternative to traditional epidermal skin grafts (STSG) has been compared in a controlled randomised trial to meshed STSG for deep partial thickness burns with no statistically significant reduction in re-epithelisation time [9]. Another similar study have been conducted but was underpowered (sample size of 10) [28] and results of a larger trial are awaited. Nevertheless, it might be suggested that transplanted stem cells could stimulate the naturally present skin stem cells to differentiate into keratinocytes and other epidermal cells, further researches are needed to point out the mediating mechanisms.

VEGF and PDGF immunoeexpression in the MSCs and EPOa/MSCs groups was significantly increased as compared to burn group in the present work. This confirms the angiogenic role of MSC in burn healing. Agreeing to these results, it was reported that Western blot analysis for TGF- β 1 and VEGF performed in the burn injury lesions of mice that received MSCs/Fluc was higher than those of mice that did not receive [23]. Also, PDGF immunoeexpression had been reported to be up-regulated in MSCs and PRP-pretreated MSCs rats' burn lesions as compared to those didn't receive [10]. PDGF and TGF- β had been reported to participate in the stabilisation process of the newly formed vessels in wound healing by the recruitment of pericytes and smooth muscle cells and by the deposition of connective tissue. PDGF recruits smooth muscle cells and TGF- β suppresses endothelial proliferation and migration, and enhances the production of extracorporeal matrix proteins [16].

α SMA immunoeexpression in MSCs and EPOa/MSCs groups was significantly decreased as compared to burn group, this might confirm their favourable role in decreasing post healing scar formation. Contradictory to these results, it was reported that RT-PCR levels of mouse α SMA were elevated in both adipose-derived stem cells (ASC)-treated and control burns compared to unwounded skin with no significant difference in relative expression of α SMA was observed between ASC-treated and control groups suggesting that contraction of these wounds is similar between the two latter groups [2]. α SMA immuno-

expression results of the current study ascertained the EPOa/MSCs role in wound contraction. It was reported that fibroblasts enter the wound from the edges and migrate toward the centre in response to cytokines and growth factors. Some of these cells may differentiate into cells called myofibroblasts, which contain SMA and have increased contractile activity, and serve to close the wound by pulling its margins toward the centre [16]. Activated fibroblasts and myofibroblasts also increase their synthetic activity and produce connective tissue proteins, mainly collagen, which is the major component of the fully developed scar [16]. A number of studies had declared that through reducing expression of myofibroblast marker and the down-regulation of collagen I synthesis, BM-MSCs had succeeded in reducing hypertrophic scarring [29, 34, 35].

EPOa/MSCs-treated rats showed more favourable biochemical, histological and immunohistochemical results as compared to MSCs-treated rats in the current work, this might elucidate the stem cells proliferating role of erythropoietin *in vivo* in addition to its *in vitro* proliferating role. Supporting these results, recombinant human-alpha erythropoietin (rhEPOa) had been proved to accelerate *in vitro* cell proliferation and to promote endothelial transdifferentiation of human MSCs from the apical papilla (SCAP) [15]. Erythropoietin also recently had been proved to be antifibrotic, protect rats against spongiofibrosis and improve urethral wound healing in a rat model of urethral injury [14]. However, the exact mechanism by which EPOa enhanced stem cells proliferation is still unclear and further researches are warranted.

CONCLUSIONS

EPOa/MSCs might improve burn wound healing probably through anti-inflammatory, immunomodulatory and angiogenic action. However, *in vivo* transdifferentiation into keratinocytes had been rarely detected.

REFERENCES

1. Altman AM, Yan Y, Matthias N, et al. IFATS collection: Human adipose-derived stem cells seeded on a silk fibroin-chitosan scaffold enhance wound repair in a murine soft tissue injury model. *Stem Cells*. 2009; 27(1): 250–258, doi: [10.1634/stemcells.2008-0178](https://doi.org/10.1634/stemcells.2008-0178), indexed in Pubmed: [18818439](https://pubmed.ncbi.nlm.nih.gov/18818439/).
2. Bliley JM, Argenta A, Satish L, et al. Administration of adipose-derived stem cells enhances vascularity, induces collagen deposition, and dermal adipogenesis in burn wounds. *Burns*. 2016; 42(6): 1212–1222, doi: [10.1016/j.burns.2015.12.007](https://doi.org/10.1016/j.burns.2015.12.007), indexed in Pubmed: [27211359](https://pubmed.ncbi.nlm.nih.gov/27211359/).
3. Caliari-Oliveira C, Yaochite JN, Ramalho LN, et al. Xenogenic mesenchymal stromal cells improve wound healing and modu-

- late the immune response in an extensive burn model. *Cell Transplant.* 2016; 25(2): 201–215, doi: [10.3727/096368915X688128](https://doi.org/10.3727/096368915X688128), indexed in Pubmed: [25955320](https://pubmed.ncbi.nlm.nih.gov/25955320/).
4. Cheng F, Shen Y, Mohanasundaram P, et al. Vimentin coordinates fibroblast proliferation and keratinocyte differentiation in wound healing via TGF- β -Slug signaling. *Proc Natl Acad Sci U S A.* 2016; 113(30): E4320–E4327, doi: [10.1073/pnas.1519197113](https://doi.org/10.1073/pnas.1519197113), indexed in Pubmed: [27466403](https://pubmed.ncbi.nlm.nih.gov/27466403/).
 5. Clover AJP, Kumar AHS, Isakson M, et al. Allogeneic mesenchymal stem cells, but not culture modified monocytes, improve burn wound healing. *Burns.* 2015; 41(3): 548–557, doi: [10.1016/j.burns.2014.08.009](https://doi.org/10.1016/j.burns.2014.08.009), indexed in Pubmed: [25234958](https://pubmed.ncbi.nlm.nih.gov/25234958/).
 6. Cruz FF, Rocco PRM. Stem-cell extracellular vesicles and lung repair. *Stem Cell Investig.* 2017; 4: 78, doi: [10.21037/sci.2017.09.02](https://doi.org/10.21037/sci.2017.09.02), indexed in Pubmed: [29057250](https://pubmed.ncbi.nlm.nih.gov/29057250/).
 7. Eyarefe DO, Kuforiji DI, Jarikre TA, et al. Enhanced electroscaelpel incisional wound healing potential of honey in wistar rats. *Int J Vet Sci Med.* 2017; 5(2): 128–134, doi: [10.1016/j.ijvsm.2017.10.002](https://doi.org/10.1016/j.ijvsm.2017.10.002), indexed in Pubmed: [30255061](https://pubmed.ncbi.nlm.nih.gov/30255061/).
 8. Gore AV, Bible LE, Song K, et al. Mesenchymal stem cells increase T-regulatory cells and improve healing following trauma and hemorrhagic shock. *J Trauma Acute Care Surg.* 2015; 79(1): 48–52; discussion 52, doi: [10.1097/TA.0000000000000681](https://doi.org/10.1097/TA.0000000000000681), indexed in Pubmed: [26091313](https://pubmed.ncbi.nlm.nih.gov/26091313/).
 9. Gravante G, Di Fede MC, Araco A, et al. A randomized trial comparing ReCell system of epidermal cells delivery versus classic skin grafts for the treatment of deep partial thickness burns. *Burns.* 2007; 33(8): 966–972, doi: [10.1016/j.burns.2007.04.011](https://doi.org/10.1016/j.burns.2007.04.011), indexed in Pubmed: [17904748](https://pubmed.ncbi.nlm.nih.gov/17904748/).
 10. Hosni Ahmed H, Rashed LA, Mahfouz S, et al. Can mesenchymal stem cells pretreated with platelet-rich plasma modulate tissue remodeling in a rat with burned skin? *Biochem Cell Biol.* 2017; 95(5): 537–548, doi: [10.1139/bcb-2016-0224](https://doi.org/10.1139/bcb-2016-0224), indexed in Pubmed: [28314112](https://pubmed.ncbi.nlm.nih.gov/28314112/).
 11. Hu C, Yong X, Li C, et al. CXCL12/CXCR4 axis promotes mesenchymal stem cell mobilization to burn wounds and contributes to wound repair. *J Surg Res.* 2013; 183(1): 427–434, doi: [10.1016/j.jss.2013.01.019](https://doi.org/10.1016/j.jss.2013.01.019), indexed in Pubmed: [23462453](https://pubmed.ncbi.nlm.nih.gov/23462453/).
 12. Jaiswal N, Haynesworth SE, Caplan AI, et al. Osteogenic differentiation of purified, culture-expanded human mesenchymal stem cells in vitro. *J Cell Biochem.* 1997; 64(2): 295–312, indexed in Pubmed: [9027589](https://pubmed.ncbi.nlm.nih.gov/9027589/).
 13. Khorramirouz R, Go JL, Noble C, et al. A novel surgical technique for a rat subcutaneous implantation of a tissue engineered scaffold. *Acta Histochem.* 2018; 120(3): 282–291, doi: [10.1016/j.acthis.2018.02.010](https://doi.org/10.1016/j.acthis.2018.02.010), indexed in Pubmed: [29519681](https://pubmed.ncbi.nlm.nih.gov/29519681/).
 14. Kilinc MF, Doluoglu OG, Eser PE, et al. Intraurethral erythropoietin to prevent fibrosis and improve urethral healing: an experimental study in a rat model. *Urology.* 2019; 123: 297.e9–297.e14, doi: [10.1016/j.urology.2018.05.045](https://doi.org/10.1016/j.urology.2018.05.045), indexed in Pubmed: [30036615](https://pubmed.ncbi.nlm.nih.gov/30036615/).
 15. Koutsoumparis A, Vassili A, Bakopoulou A, et al. Erythropoietin (rhEPOa) promotes endothelial transdifferentiation of stem cells of the apical papilla (SCAP). *Arch Oral Biol.* 2018; 96: 96–103, doi: [10.1016/j.archoralbio.2018.09.001](https://doi.org/10.1016/j.archoralbio.2018.09.001), indexed in Pubmed: [30205239](https://pubmed.ncbi.nlm.nih.gov/30205239/).
 16. Kumar V, Abbas AK, Aster JC. Inflammation and Repair. In: *Robbins Basic Pathology*, 10th edition. Elsevier, Philadelphia. 2018: 57–59.
 17. Li M, Qiu L, Hu W, et al. Genetically-modified bone mesenchymal stem cells with TGF- β improve wound healing and reduce scar tissue formation in a rabbit model. *Exp Cell Res.* 2018; 367(1): 24–29, doi: [10.1016/j.yexcr.2018.02.006](https://doi.org/10.1016/j.yexcr.2018.02.006), indexed in Pubmed: [29453974](https://pubmed.ncbi.nlm.nih.gov/29453974/).
 18. Liu L, Yu Y, Hou Y, et al. Human umbilical cord mesenchymal stem cells transplantation promotes cutaneous wound healing of severe burned rats. *PLoS One.* 2014; 9(2): e88348, doi: [10.1371/journal.pone.0088348](https://doi.org/10.1371/journal.pone.0088348), indexed in Pubmed: [24586314](https://pubmed.ncbi.nlm.nih.gov/24586314/).
 19. Liu P, Deng Z, Han S, et al. Tissue-engineered skin containing mesenchymal stem cells improves burn wounds. *Artif Organs.* 2008; 32(12): 925–931, doi: [10.1111/j.1525-1594.2008.00654.x](https://doi.org/10.1111/j.1525-1594.2008.00654.x), indexed in Pubmed: [19133020](https://pubmed.ncbi.nlm.nih.gov/19133020/).
 20. Middelkoop E, van den Bogaerd AJ, Lamme EN, et al. Porcine wound models for skin substitution and burn treatment. *Biomaterials.* 2004; 25(9): 1559–1567, indexed in Pubmed: [14697858](https://pubmed.ncbi.nlm.nih.gov/14697858/).
 21. Mofazzal Jahromi MA, Sahandi Zangabad P, Moosavi Basri SM, et al. Nanomedicine and advanced technologies for burns: Preventing infection and facilitating wound healing. *Adv Drug Deliv Rev.* 2018; 123: 33–64, doi: [10.1016/j.addr.2017.08.001](https://doi.org/10.1016/j.addr.2017.08.001), indexed in Pubmed: [28782570](https://pubmed.ncbi.nlm.nih.gov/28782570/).
 22. Motamed S, Taghiabadi E, Molaei H, et al. Cell-based skin substitutes accelerate regeneration of extensive burn wounds in rats. *Am J Surg.* 2017; 214(4): 762–769, doi: [10.1016/j.amj-surg.2017.04.010](https://doi.org/10.1016/j.amj-surg.2017.04.010), indexed in Pubmed: [28522073](https://pubmed.ncbi.nlm.nih.gov/28522073/).
 23. Oh EJ, Lee HoW, Kalimuthu S, et al. In vivo migration of mesenchymal stem cells to burn injury sites and their therapeutic effects in a living mouse model. *J Control Release.* 2018; 279: 79–88, doi: [10.1016/j.jconrel.2018.04.020](https://doi.org/10.1016/j.jconrel.2018.04.020), indexed in Pubmed: [29655989](https://pubmed.ncbi.nlm.nih.gov/29655989/).
 24. Öksüz S, Ülkür E, Öncül O, et al. The effect of subcutaneous mesenchymal stem cell injection on stasis zone and apoptosis in an experimental burn model. *Plast Reconstr Surg.* 2013; 131(3): 463–471, doi: [10.1097/PRS.0b013e31827c6d6f](https://doi.org/10.1097/PRS.0b013e31827c6d6f), indexed in Pubmed: [23446561](https://pubmed.ncbi.nlm.nih.gov/23446561/).
 25. Sanderson S, Wild G, Cull AM, et al. Immunohistochemical and immunofluorescent techniques. In: *Suvarna SK, Layton C, Bancroft, JD, Editors. Bancroft's Theory and Practice of Histological Techniques*, Eighth Edition, Elsevier Limited. 2019: 337–394.
 26. Schrepfer S, Deuse T, Lange C, et al. Simplified protocol to isolate, purify, and culture expand mesenchymal stem cells. *Stem Cells Dev.* 2007; 16(1): 105–108, doi: [10.1089/scd.2006.0041](https://doi.org/10.1089/scd.2006.0041).
 27. Seo MS, Jeong YH, Park JR, et al. Isolation and characterization of canine umbilical cord blood-derived mesenchymal stem cells. *J Vet Sci.* 2009; 10(3): 181–187, doi: [10.4142/jvs.2009.10.3.181](https://doi.org/10.4142/jvs.2009.10.3.181), indexed in Pubmed: [19687617](https://pubmed.ncbi.nlm.nih.gov/19687617/).
 28. Sood R, Roggy DE, Zieger MJ, et al. A comparative study of spray keratinocytes and autologous meshed split-thickness skin graft in the treatment of acute burn injuries. *Wounds.* 2015; 27(2): 31–40, indexed in Pubmed: [25785905](https://pubmed.ncbi.nlm.nih.gov/25785905/).
 29. Sultan SM, Barr JS, Butala P, et al. Fat grafting accelerates revascularisation and decreases fibrosis following thermal injury. *J Plast Reconstr Aesthet Surg.* 2012; 65(2): 219–227, doi: [10.1016/j.bjps.2011.08.046](https://doi.org/10.1016/j.bjps.2011.08.046), indexed in Pubmed: [21962530](https://pubmed.ncbi.nlm.nih.gov/21962530/).
 30. Vinish M, Cui W, Stafford E, et al. Dendritic cells modulate burn wound healing by enhancing early proliferation. *Wound Repair Regen.* 2016; 24(1): 6–13, doi: [10.1111/wrr.12388](https://doi.org/10.1111/wrr.12388).
 31. Wang Li, Di L, Noguchi CT. Erythropoietin, a novel versatile player regulating energy metabolism beyond the erythroid system. *Int J Biol Sci.* 2014; 10(8): 921–939, doi: [10.7150/ijbs.9518](https://doi.org/10.7150/ijbs.9518), indexed in Pubmed: [25170305](https://pubmed.ncbi.nlm.nih.gov/25170305/).
 32. Wang Y, Beekman J, Hew J, et al. Burn injury: Challenges and advances in burn wound healing, infection, pain and scarring. *Adv Drug Deliv Rev.* 2018; 123: 3–17, doi: [10.1016/j.addr.2017.09.018](https://doi.org/10.1016/j.addr.2017.09.018), indexed in Pubmed: [28941987](https://pubmed.ncbi.nlm.nih.gov/28941987/).
 33. Waterman RS, Tomchuck SL, Henkle SL, et al. A new mesenchymal stem cell (MSC) paradigm: polarization into a pro-inflammatory MSC1 or an immunosuppressive MSC2 phenotype. *PLoS One.* 2010; 5(4): e10088, doi: [10.1371/journal.pone.0010088](https://doi.org/10.1371/journal.pone.0010088), indexed in Pubmed: [20436665](https://pubmed.ncbi.nlm.nih.gov/20436665/).
 34. Wu Y, Huang S, Enhe J, et al. Bone marrow-derived mesenchymal stem cell attenuates skin fibrosis development in mice. *Int Wound J.* 2014; 11(6): 701–710, doi: [10.1111/iwj.12034](https://doi.org/10.1111/iwj.12034), indexed in Pubmed: [23409729](https://pubmed.ncbi.nlm.nih.gov/23409729/).
 35. Zhang J, La X, Fan L, et al. Immunosuppressive effects of mesenchymal stem cell transplantation in rat burn models. *Int J Clin Exp Pathol.* 2015; 8(5): 5129–5136, indexed in Pubmed: [26191208](https://pubmed.ncbi.nlm.nih.gov/26191208/).