

Investigation of the styloid process length in a Greek population

N. Zokaris¹, I. Siska², K. Natsis³, M. Piagkou⁴, N. Lazaridis³, A. Skolka⁵, E. Piehslinger⁵

¹Prosthodontics Department, 251 Hellenic Air Force General and VA Hospital, Athens, Greece

²Oral Radiology Department, 251 Hellenic Air Force General and VA Hospital, Athens, Greece

³Department of Anatomy and Surgical Anatomy, School of Medicine, Faculty of Health and Sciences, Aristotle University of Thessaloniki, Greece

⁴Department of Anatomy, Faculty of Health and Sciences, National and Kapodistrian University of Athens, Greece

⁵Prosthodontics Department, Dental School, Medical University of Vienna, Austria

[Received: 12 July 2018; Accepted: 15 August 2018]

Background: The styloid process (SP) is a slender cylindrical bony projection of the temporal bone with 2 ligaments and 3 muscles attached to it. Symptomatic SP elongation is also referred to, as Eagle's syndrome. The aim of the present study is to investigate the distribution of the SP length in a young adult Greek population.

Materials and methods: Moreover, we provide a comparison of the results by using two different methods for assessing SP elongation, as described in the literature. Finally, we explore the possibility of using orthopantomograms (OPGs), as a diagnostic aid by investigating inter-examiner, intra-examiner and inter-examination variability and we propose a limit for SP elongation measurable in OPGs.

Results: The sample comprised 805 digital OPGs, taken from student pilots and engineers entering the Hellenic Air Force Academy, from 2008 onwards. Two measuring approaches were selected, one using the temporal bone, as a cranial landmark and the other, using the external auditory meatus. The end tip of the process was always the caudal landmark. The mean SP length was 28.42 ± 8.48 mm in males and 26.04 ± 7.69 mm in females, when measured from the temporal bone. The mean SP length was 38.35 ± 8.90 mm in males and 34.24 ± 8.63 mm in females, when measured from the external auditory meatus. The length of 30 mm is most commonly used as a starting point for SP elongation. In the total sample, 30.6% of the measured SPs exceeded the length of 30 mm. In males, 33.12% of the SPs were elongated; while in females the corresponding incidence was 20%. One hundred and nineteen (14.8%) SPs were not traceable.

Conclusions: The SP is typically detectable and measurable in OPGs. An elongated SP should be kept in mind, since symptoms of elongation may overlap with clinical manifestations of temporomandibular joint disorders. (*Folia Morphol* 2019; 78, 2: 378–388)

Key words: temporomandibular disorders, Eagle's syndrome, styloid syndrome, styloid process, elongation

INTRODUCTION

The styloid process (SP) is a long osseous projection of the petrous part of the temporal bone projecting forward, downward and slightly medial. The functional unit, which is composed of 3 muscles (styloglossus, stylohyoid and stylopharyngeus) and 2 ligaments (stylohyoid and stylomandibular) attached to it, is called styloid apparatus and is derived from the second branchial arch [11]. The symptomatic SP elongation is also referred to as Eagle's syndrome [12–15] and causes cervicofacial pain, tinnitus and otalgia. This definition can be found under the headings of heterotopic ossification and/or temporal bone abnormalities. Alternative synonyms are "elongated styloid process syndrome" [13, 19, 32], "styloid–stylohyoid syndrome" [25], "carotid artery syndrome" [14] and stylalgia [27].

The stylohyoid ligament seems to be mainly involved in Eagle's syndrome pathophysiology. The ligament may be partially represented by bone, most often at its proximal extremity, or in some instances may be completely ossified [61]. The topographic anatomy of the parapharyngeal space emphasizes the importance of SP length and angulation, since possible compression and impingement of surrounding structures may appear in cases of SP elongation and/or ligaments' ossification [9, 20, 51]. On the other hand, muscles and ligaments attached to the SP regulate the movements of the mandible, hyoid bone, tongue and pharynx [45]. Mineralisation/ossification of the stylohyoid-stylomandibular ligament complex is relative common [17] and may affect function of the masticatory organ [60] (Fig. 1).

Several of the symptoms attributed to an elongated SP are common clinical manifestations of the temporomandibular joint disorders (TMD) and because of this overlap, a potential of misdiagnosis always exists [65]. Palesy et al. [49] concluded that the clinical examination of patients with cervicofacial pain and mandibular dysfunction should include the SP investigation. Detailed knowledge of variations and possible effects on suprahyoid structures is important for an accurate diagnosis of TMD and orofacial pain [34]. Vague facial pain, especially upon swallowing, turning the head or opening the mouth, dysphagia, otalgia, headache and dizziness have been associated with elongated SPs or mineralised stylohyoid ligaments [8]. Siessere et al. [59] after a comparison of functional electromyographic patterns in patients with Eagle's syndrome and healthy individuals reported muscular

hyperactivity in the patients' group attributed to the SP interference. Krennmair and Piehslinger [34] suggested that bone growth apposition or ligaments' ossification due to SP traction caused by malocclusion may lead to a decrease in the hyoid bone mobility, affecting mandibular movement. Slavicek [60] considered Eagle's syndrome, as a cause for the reduced mandibular mobility. There is however no unique statement on what seems to be the normal SP length and consequently on a proposed limit for elongation. Eagle [13] reported that the typical SP length is 25 mm. According to Stafne and Hollinshead [61], the SP varies widely in length (5–50 mm), thickness, form and shape. Langlais et al. [37] defined the typical SP length varying between 25 and 32 mm and Moffat et al. [41] demonstrated values between 1.52 and 4.77 cm. Jung et al. [29] and Monsour and Young [42] proposed 45 and 40 mm, as the limit for SP elongation.

In order to assess SP length, various imaging modalities, such as orthopantomograms (OPGs), lateral cephalometric radiographs [2, 47], anteroposterior skull radiographs, computed tomography scanning [27, 44] and anatomical methods utilising measurements in dry skulls [10, 11, 18, 38, 39, 41, 45, 50] have been used. The advantage of metric studies in dry skulls is lack of distortion or superimpositions of structures. On the other hand, it is rather hard to find numerous intact SPs, since SP is a particularly fragile part of the cranium [10].

Many radiological studies have used OPGs to evaluate SP length (Table 1), the pattern of the stylohyoid chain or the percentage of elongated complexes, however defined (Table 2), due to availability, diagnostic performance, low cost, less radiation and the particularly high sensitivity of the method in detecting SP elongation [62, 63]. Three basic methods have been described regarding the assessment of the stylohyoid complex elongation in OPGs. In the first method, Ferrario et al. [16] used the anterior nasal spine and the mastoid process, as reference landmarks. Those landmarks are connected with a line and if the complex exceeded the line, it is considered elongated. Therefore, SPs until 25 mm were normal in the OPG, if they projected above the line connecting the anterior nasal spine to the mastoid process. In the second method, Goldstein and Scopp [24] used the height of the posterior border of the mandibular ramus to define SP elongation. If the SP exceeded the 1/3 of the height, it was considered elongated. Prasad et al. [52] used this approach before deciding

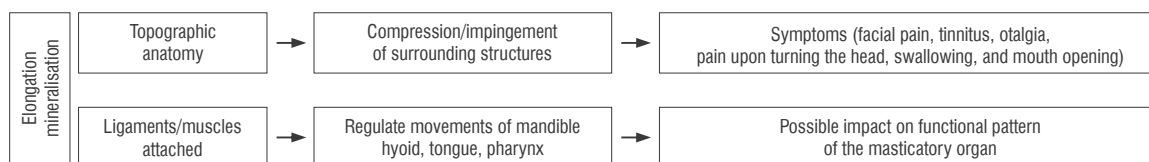


Figure 1. Impact of styloid process elongation. Possible mechanisms and results.

Table 1. Limits and mean values for styloid process (SP) elongation in papers using orthopantomograms (OPGs)

Study	Year	Limit for SP elongation	Sample/OPGs	Mean length
Kaufman et al. [31]	1970	30	484	29.49 L/29.92 R
Correl et al. [8]	1979	30	1771	43.6*
Monsour and Young [42]	1986	30	1200	29.2
Keur et al. [32]	1986	30	1135	47.9 M/44.5 F
Camarda et al. [5, 6]	1989	25	150	10
Zaki et al. [65]	1996	30	100	31.9
Bozkir et al. [4]	1999	30	200	53*
Sokler and Sandev [62]	2001	< 21/21–30/30 >	296	21.6 R/21.2 L
Yamashita [64]	2002	–	389	30.08
Krennmair and Prieslinger [35]	2003	25	420	12.6–23.2
Jung et al. [29]	2004	45	1000	31
Ilguy et al. [30]	2005	30	860	34 ± 8 L*/35 ± 15 R*
Gokce et al. [23]	2008	30	698	38.1 M*/36.6 F*
More and Asrani [43]	2010	30	500	25.41 L, 25.53 R
de Andrade et al. [2]	2012	30	50	32.98 R/33.50 L
Sancio-Goncalves et al. [57]	2013	30	78 TMD, 93 control	27.2, 28.2
Reddy et al. [55]	2013	30	260	36.7*

*Mean length of elongated SPs; F — females; L — left; M — males; R — right; TMD — temporomandibular joint disorder

to perform surgical removal. The third method is not comparative. It is a metric approach utilising anatomic landmarks corresponding to the beginning and end tip of the SP. Jung et al. [29] specified the starting point of measurement, as the centre of a circle encircling the cleft between SP and tympanic plate, while Monsour and Young [42] and Zaki et al. [65] used the point of SP emersion from the temporal bone. The end tip of the SP or the ossified part of the ligament is obviously the other landmark.

The aim of the current study is to investigate the distribution of SP length in a young adult Greek population. Moreover we provide a comparison of the results by using two different methods for assessing SP elongation, as described in the literature. Finally we explore the possibility of using OPGs, as a diagnostic aid by investigating inter-examiner, intra-examiner and inter-examination variability and we propose a limit for SP elongation measurable in OPGs.

MATERIALS AND METHODS

The sample comprised student pilots and engineers entering the Hellenic Air Force Academy, from 2008 onwards. A list of age specific candidates (17–21 years old) was provided from the records of the Centre of Aviation Medicine in Athens, located in the 251 Hellenic Air Force and VA Hospital. Upon acceptance in the Academy, all students had a thorough medical examination. An OPG combined with an intraoral and extraoral examination were part of this process. General consent to anonymously use data for possible future research purposes is typically required from all patients attending the hospital. All the dental records are kept in the Dental Department of the Centre of Aviation Medicine in Athens. Their digital copy is kept in the Oral Radiology Department of 251 Hellenic Air Force and VA Hospital, where the standardised OPG was taken (PlanmecaPromax 2002, 84 KV max/Total filtration 2.5 mm Al, Planmeca, 00880 Helsinki, Finland). Search strategy

Table 2. Prevalence of styloid process (SP) elongation from papers using orthopantomograms (OPGs)

Study	Year	Sample/OPGs	SP elongation [%]
Kaufman et al. [31]	1970	484	28%
Goldstein and Scopp [24]	1973	554	22.2%
Gossman and Tarsitano [25]	1977	4200	4%
Correl et al. [8]	1979	1771	18.2%
O'Carroll [46]	1984	479	35.3%
Monsour and Young [42]	1986	1200	21.1%
Keur et al. [32]	1986	1135	30%
Ferrario et al. [16]	1990	286	84.4%
Zaki et al. [65]	1996	100	27%
Bozkir et al. [4]	1999	200	4%
MacDonald-Jankowski [40]	2001	1662	7.8–8.6%
Scaf et al. [58]	2003	166	12.6%
Kursoglu et al. [36]	2005	55	83.6%
Ilguy et al. [30]	2005	860	3.7%
Radfar et al. [53]	2008	1000	22%
Gokce et al. [23]	2008	698	7.7%
More and Asrani [43]	2010	500	19.4%
Bagga et al. [3]	2012	2706	52.1%
Roopashri et al. [56]	2012	300	35.6%
Alpoz et al. [1]	2014	1600	28.8%

required the use of the software “PlanmecaDimaxis Pro 4.3.2”. The programme required either the entry of the name or the birth date of an individual in order to search the database for the corresponding OPG. If more than one OPG happen to have the same name or birth date, then all of them are presented in a list. In the present study the variable “birth date” was used intentionally, for anonymity purposes and in order to include people randomly attending the department for an OPG and therefore widening the sample, without affecting age or geographic distribution of the sample. Those individuals, that had the same birth date with our initial list, were labelled duplicates and were included if the examination date did not exceed 6/2015. Foreigners were excluded.

A dentist specialised in maxillofacial radiology performed panoramic imaging. For every OPG taken the exposure settings (KV and mA) were set to automatic. The patient was asked to stand up straight into the orthopantomograph and his maxillary and mandibular anterior teeth were in the corresponding notch on the bite block device. Three references laser lights (Frankfort horizontal plane light, canine light and mid-sagittal plane light) appeared on the

orthopantomograph to orientate a standardised head position.

In order to ensure the measurements' accuracy, an attempt to calculate the OPG distortion in SP area was made. For this purpose, 16 skulls were kindly provided by the Departments of Anatomy and Surgical Anatomy of the Schools of Medicine of National and Kapodistrian University of Athens and Aristotle University of Thessaloniki. Two radiological indexes were constructed using wooden prefabricated sticks and metal balls/markers of 1.5 mm diameter each. Wood was selected to ensure that no scattering would impede the measurements. The wooden rod was marked and cut with a disc to 22 mm and the metal balls were attached to each end with universal adhesive glue. From end to end, the total distance was 25 mm (Fig. 2A) and from ball centre to ball centre 23.5 mm. Each index was placed randomly to a right or left SP, parallel to its longitudinal axis and orthodontic wax was used to keep it stable (Fig. 2B). Each skull was irradiated twice. The process was repeated at different time intervals, repositioning the markers and setting the skull position according to the reference lines. Thirty-two OPGs were taken and 64 SPs/markers of




Figure 2. A. Radiological index and digital calliper; B. Index attached with orthodontic wax.

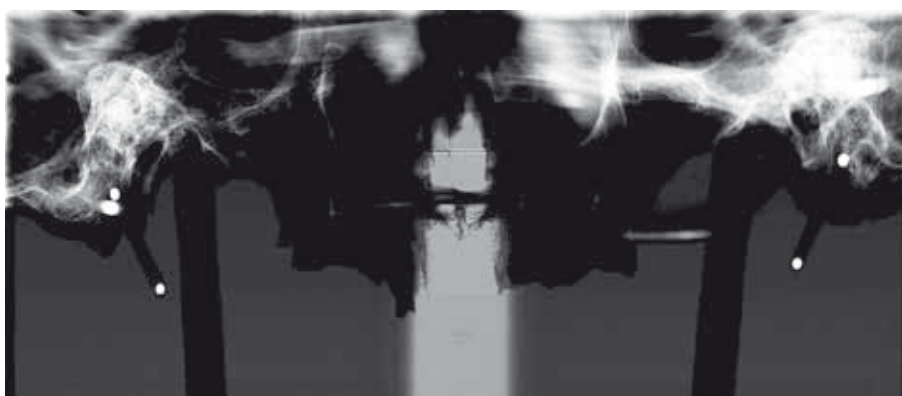


Figure 3. A panoramic radiograph of a skull with the index positioned.

25 mm standard value were measured (Fig. 3). In the few cases that the ball (always the cranial one) was not included in the image, the value was left blank. Both sides were combined to give 58 measurements in total and 6 blank. The test for the null hypothesis $\mu = 25$ was not rejected, so the distortion could be considered negligible.

For each OPG selected, the described standardised steps were followed to measure SP length:

1. Digital image opening;
2. Instant magnification;
3. Landmarks' location at the right side (starting point of measurement from a landmark caudal to cranial) and measurements' registration;
4. Landmarks' location at the left side and measurements' registration.

To assess SP length, two approaches were used [29, 45]. In the first approach [29], the landmarks used were: the centre of a circle encircling the cleft between SP and tympanic plate and the end of the SP tip. In the second approach [45] the used landmarks were: the lowest-posterior point of the external audi-

tory meatus (EAM) and the end of the SP tip. For both methods (Fig. 4), if the SP was nodular or radiopaque, then the end tip of the last caudal radiopaque part was defined as the end tip. All pictures, in which the SP was not present or its total length was not clearly depicted were marked as not traceable.

In the present study 805 OPGs were selected, obtained from 655 male (mean age 19.03 years) and 150 female patients (mean age 19.5 years). Each SP was assessed separately since SP elongation may be unilateral or bilateral. In 119 OPGs, SPs were characterised bilaterally as non-traceable. In the remaining 686 OPGs, at least one SP was traceable (Table 3). For each identifiable SP four measurements were made: measurement according to Jung et al. [29] method by the main researcher, repeated twice, measurement according to Jung et al. [29] method by the second examiner and measurement according to Natsis et al. [45] method by the main researcher.

During statistical analysis, an extra value (e) was created — by the combination of (a) and (b) values — the mean value for each SP by the two measurements of the

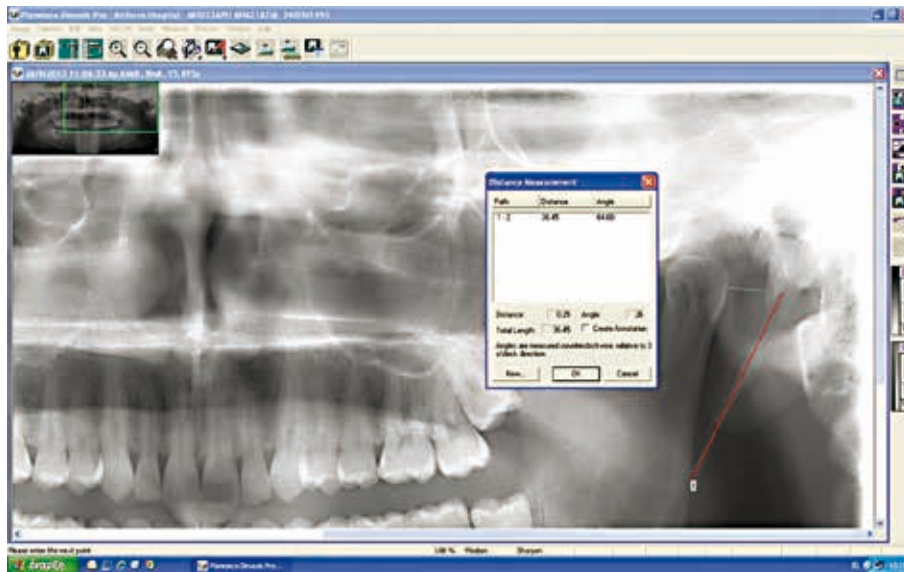


Figure 4. Measuring the styloid process length. The measured value is displayed in a drop up box. External acoustic meatus is also visible.

Table 3. Traceability of the styloid process in the study sample and between males and females according to the side of occurrence

Side of occurrence	Males	Females	Both genders
Bilaterally not traceable	86 (13.1%)	33 (22%)	119 (14.8%)
Unilaterally traceable:			
Left side	24 (3.7%)	9 (6%)	33 (4.1%)
Right side	44 (6.7%)	15 (10%)	59 (7.3%)
Bilaterally traceable	501 (76.5%)	93 (62%)	594 (73.8)
Total	655 (100%)	150 (100%)	805 (100%)

The total number of traceable styloid processes — 686

main researcher. Measuring a structure twice or more and combining the measurements to provide a mean adds to the accuracy of the process and reduces the error between measurements [2]. Comparison between a–b describes the intra-examiner variability, between a–c, the inter-examiner variability and between e–d the relationship of the two methods of measurement.

The non-parametric Mann-Whitney U test was used to compare male and female values. Kolmogorov-Smirnov test was used to determine the normality of the distributions. The non-parametric Mann-Whitney U test was used in order to compare two independent samples, right and left. Non-parametric Mann-Whitney tests comparing male versus female samples were found to be significant, therefore the two samples were not combined. The extent of agreement among repeated measurements performed by an examiner is described by the intra-examiner variability and the extent of agreement between examiners is described by the inter-examiner variability. Low variability cor-

responds to high validity of the utilised examination. Inter-examiner and intra-examiner variability were tested by means of the non-parametric Wilcoxon signed rank test. The null hypothesis, that the two measurements were not different, was also retained at significance level 5%. Differences between measurements of the two examiners were also calculated.

Inter-OPG variability was a very interesting aspect of this study. Out of the 805 individuals, 138 had taken a second OPG within the time frame of the current study. These OPGs were also assessed, separately, creating a subsample of 138 images (109 males, 19 females), which could be compared with their corresponding previous ones to evaluate how reliable the OPG can determine SP length. The time frame could certainly not justify a differentiation in length, hence the same structure was measured in two different OPGs. In such a case, the subsample could be unified regarding gender, since the point of interest was to directly check upon the accuracy of

Table 4. Descriptive statistics for the length of the styloid process (SPL), as it measured from the temporal bone (TB) and the external acoustic meatus (EAM) in males and females and in the total sample

Metric variables	Males				Females			
	SPL-R from TB	SPL-L from TB	SPL-R from EAM	SPL-L from EAM	SPL-R from TB	SPL-L from TB	SPL-R from EAM	SPL-L from EAM
N	545	525	520	497	108	102	108	103
Total	1070		1017		210		211	
Mean \pm SD	28.14 \pm 8.35	28.60 \pm 8.48	37.64 \pm 8.62	38.98 \pm 8.90	25.79 \pm 7.48	26.27 \pm 7.86	33.72 \pm 8.23	34.78 \pm 9.03
Mean \pm SD (in total)	28.42 \pm 8.48		38.35 \pm 8.90		26.04 \pm 7.69		34.24 \pm 8.63	
Median	26.32	26.83	35.58	37.32	25.27	25.11	32.60	34.17
Median (in total)	26.56		36.42		25.218		33.34	
Minimum–maximum	10.33–76.60	9.68–70.20	12.94–84.34	15.38–83.94	9.86–54.80	9.65–60.77	14.34–66.68	10.89–72.44
Percentiles:								
25	22.83	23.15	32.42	33.27	20.71	22.47	29.32	31.07
25 in total	23.07		32.79		22.09		30.31	
50	26.32	26.83	35.58	37.32	25.27	25.11	32.60	34.17
50 in total	26.56		36.42		25.21		33.34	
75	30.84	31.54	40.96	42.16	29.28	28.34	35.75	36.82
75 in total	31.50		41.47		28.75		36.49	
90	38.19	39.65	48.65	51.89	32.81	33.54	41.96	43.24
90 in total	39.01		49.70		32.52		41.75	

L — left; R — right; SD — standard deviation

OPG depicting the same structure, which definitely is not gender-related. Inter OPG variability was checked for both methods — measurements from the temporal bone and from the EAM — for the former the mean values were compared with the measurements in the second OPG. The protocol was approved by the Ethics Committee, Educational and Scientific Board of 251 Hellenic Air Force General and VA Hospital — Protocol Number 313/August 2015.

RESULTS

For the SP length assessment from the temporal bone and the EAM, descriptive statistics are presented in Table 4. The mean SP length was 28.42 ± 8.48 mm in males and 26.04 ± 7.69 mm in females, when the SP length was measured from the temporal bone. The mean SP length was 38.35 ± 8.90 mm in males and 34.24 ± 8.63 mm in females, when the SP length was measured from the EAM. SP elongation was not side-related ($p = 0.957$ and 0.175 for both measurements in males, and $p = 0.555$ and 0.359 in females). Differences between measurements of the two examiners were also calculated. The mean value of the calculated differences was 0.08 for the right SP and -0.08 for the left SP in men. The corresponding

values for females were 0.0006 and 0.09 , respectively. Differences between the two measurements by the same examiner were also calculated. The mean value for the calculated differences was 0.09 for the left SP and 0.11 for the right SP in men. The corresponding values for females were -0.11 and -0.16 , respectively. The proximity of the measurements is clearly depicted. The correlation coefficient between the two measuring methods was very high for genders, 0.931 for males and 0.952 for females. A correlation coefficient near unity means that there is a linear relationship between the two measuring methods.

The length of 30 mm is most commonly used as a starting point for SP elongation. In the total sample, 30.6% of the measured SPs exceeded the length of 30 mm (16.14% bilaterally and 14.53% unilaterally). In males, 33.12% of the SPs were elongated (18.16% bilaterally and 14.65% unilaterally), while in females the corresponding incidence was 20% (12.6% unilaterally and 7.3% bilaterally). One hundred and nineteen SPs (14.8%) were not traceable (Table 5).

DISCUSSION

In the present study, a particularly large sample of 805 OPGs was examined. In the literature sample

Table 5. Prevalence of styloid process (SP) elongation for measurements from the temporal bone. Limit was set on 30 mm

SP	Males	Females	Total
Both > 30 mm	119	11	130
Right only > 30 mm	47	13	60
Left only > 30 mm	51	6	57
Both < 30 mm	352	87	439
Both not traceable	86	33	119
Total	655	150	805

sizes vary from small (50 patients in Kursoglu et al. [36] study) to extremely wide (4200 in Gossman and Tarsitano [25] study) depending on the applied methodology and mainly on the tested variables. In the current investigation, the study population represents a random sample from Greece for three reasons: a) candidates came from all over the country; b) 251 Hellenic Air Force and VA Hospital is the only military hospital of the Air Force in the country serving the Veterans, the personnel of the Air Force (military and administrative) and also members of their families; c) people working for the Armed Forces are temporally transferred more often compared to other employees. Geographic factors mainly connected with dietary and daily habits have been correlated with the variable prevalence of elongated SP in Indians [3, 54] and Turks [23].

The mean age of the participants in our sample was 19.03 years for males and 19.5 years for females. The study is focused on young individuals in order to exclude aging as a possible factor for SP elongation or ligaments' ossification. A review of data literature concerning the relation between the stylohyoid apparatus' length and the age concludes to contradicted results. This relation is in a way dependent on the etiologic theories utilised for explaining SP elongation. Moreover, the fact that the plethora of papers subdivides their sample into different age groups makes impossible to draw conclusions. However, many papers [5, 6, 11, 35, 46, 47, 61] seem to agree that by the age of 20, the length and ossification have already been established, without excluding the potential for later stage ossification or elongation.

Prevalence of SP elongation and mean values were significantly higher in males, revealing a gender specific dependency. The extremely higher ratio of males opposed to females, especially in the students' subgroup, can easily be attributed to the military nature of the academic school selected. However, the ratio is com-

pensated in the group of duplicates, leading finally to a total of 150 females. In the study by Correl et al. [8], which was also carried in a VA centre in the United States, only 52 out of 1771 individuals were females and gender related comparisons were only descriptive. Regarding the correlation between gender and SP elongation, some papers reveal a male predominance, like in our study [26, 27, 43], others describe a female predominance [7, 17, 30, 46, 52, 63], while a third group supports a non-existing correlation [1, 16, 32, 36, 42, 45, 47, 55, 58].

As regards to the side asymmetry between left and right SP, no statistical significant differences existed for both genders. According to Stafne and Hollinshead [61], usually there is symmetry in SP length between the two sides, but sometimes there may be noteworthy differences concerning the SP position, shape and size. SP in the present study was bilaterally traceable in 76.5% of the males and 62% of the females. From all cases of elongation, 54.8% were bilateral for males and 36.6% for females. The symmetrical nature of this anatomic feature has been supported by several authors [1, 40]. Regarding the unilateral and bilateral SP elongation, Ferrario et al. [16] reported that the SP is often bilaterally elongated. Correl et al. [8] reported an incidence of bilateral elongation of 16%, while the unilateral one was 2.25%. Zaki et al. [65] reported that from 27 out of 100 cases with at least one SP elongation, 16 cases were bilateral and 11 unilateral. Ghosh and Dubey [21] mentioned that an incidence of 57.1% of surgically treated patients showed bilateral SP elongation. Bagga et al. [3] and More and Asrani [43] reported a bilateral SP elongation in 79.5% and 68%. O'Carroll [46] reported a bilateral calcification in 61% and a unilateral one in 17.53%. Side asymmetry was reported by Natsis et al. [45] with the right side exhibiting higher values of elongated SP. Andrade et al. [2] reported a slight tendency for the occurrence of elongation in the left side. Scaf et al. [58] found unilateral elongation to be the rule, with the majority of the cases (76.5%) in the right side and only 9.5% being bilateral. Bilateral elongation is usually not involved with bilateral symptoms [33, 52].

Styloid process elongation is the main reason for clinical symptoms. An OPG still remains in the front line, to detect SP elongation if Eagle's syndrome is suspected [28, 58, 63], as it has the advantage to discern distinctly the entire SP length and its angulation [21, 22]. Andrade et al. [2] also refer to the sensitivity

of OPGs due to head positioning. In the current study, three lines were used to orientate the head position in relation to the Frankfurt horizontal plane, the midline plane and the canine plane. Distortions, magnifications and overlapping must always be kept in mind. An attempt to calculate distortion in the present study was made to argue that measurements were as exact as possible. The measured SP length may vary with the process angulation itself [1, 22] and that is why the radiological index constructed to calculate the distortion was adjusted across the longitudinal axis of the examined skulls. Jung et al. [29] used only two skulls to calibrate their measurements, while Monsour and Young [42] used three, all placed in position by three different radiographers. In the present study 16 skulls were used and irradiated twice ending up with 64 possible measurements. Distortion could be considered negligible since the constructed index was 25 mm and the mean of calibration measurements was 24.7 mm.

Several authors [16, 24, 40] utilised comparative approaches to estimate SP elongation, supporting that measuring in OPGs is inaccurate. However, researchers utilising a metric approach measure what is depicted as a SP, without claiming that the measurement is the exact actual length of the SP. The desired is the identification of an elongated SP in an OPG, thus considered in the differential diagnosis for the orofacial pain of the patient. OPG is a valuable adjunct in diagnostic procedure and clinicians should be able to recognise SP elongation.

A rather unique feature of the present study was the comparison of the same structure in different OPGs. In the literature only Omnell et al. [47] compared cephalometric radiographs of the same individuals. That was actually a way to verify the preciseness of the OPGs, as a diagnostic aid in measuring SP elongation since in the current study the time frame was not wide enough to support differentiation in length of the same individual. In the present study, of the whole sample, 138 individuals had been irradiated twice. The hypothesis of equality was tested by means of Wilcoxon signed rank test and was always retained — either for measurements from the temporal bone or the EAM. The existed differences in the number of measurements in males and females between the two methods is attributed to the fact that sometimes the EAM was not clearly depicted in the field of the OPG, while the point of SP emersion from the temporal bone was clear, or inversely. The

difference in values is due to the part of the SP hidden by the vaginal process. The typical SP length reaches the value of 30 mm [20]. Eagle [13] considered the normal SP length to be 25 mm. According to Stafne and Hollinshead [61], the SP widely varies in length (5–50 mm), thickness, form and shape. Moffat et al. [41] regarded the normal range as being from 1.52 to 4.77 cm. Iannetti [28] considered normal values varying from 20 to 35 mm and Reddy et al. [55] from 20 to 30 mm. The normal length varies considerably [23] and an attempt for grouping existing data is presented in Table 4.

The use of different landmarks or even different methods for assessing SP length is the main reason for the diversities found in the literature regarding elongation (Table 5). Several authors use comparative approaches, while others proceed with measuring of the stylohyoid chain, either from the lower margin of the temporal bone or the EAM. In comparative approaches, other landmarks such as the mastoid process [16], the posterior border of the mandibular ramus [24] or even the mandibular foramen [40] are used to form imaginary planes that represent limits for SP elongation. In the current study two methods were used to compare the results and the accuracy of each method and to end up with a possible correlation model between the used two methods that could be applied to transform findings of other studies and make results comparable. The selected methods by Jung et al. [29] and Natsis et al. [45] were those selected due to the detailed description of the measuring process.

Jung et al. [29] suggested the use of the 90th percentile, as the limit for SP elongation (length's distribution was not normal). The length distribution of the current study was not normal and the values for the 90th percentile were 39 mm for males and 32.5 mm for females — lower than Jung et al. [29] which were 47 mm and 45 mm, respectively. For the EAM measurements no proposed limit in the literature exists but if we also consider the 90th percentile, then the corresponding values are 49.7 mm for males and 41.8 mm for females. Mean values were 38 mm and 34 mm, respectively. De Andrade et al. [2], who also used a very similar measuring approach, reported mean values around 33 mm. Natsis et al. [45] measured the SP emersion (floor of EAM) until its tip, after drilling the entire part of the vaginal process and the outer part of the EAM. It is not easy to explain the differences between populations if methodological differences are excluded. Diet, habits, geographical

parameters or even systematic conditions [3, 23, 48] have been shown to interfere with the SP length, while the theory one adopts for elongation may also justify variability. Obviously, the lack of a clear formulated and verified hypothesis regarding SP elongation explains the difficulty in attributing differences between samples to specific reasons with certainty.

CONCLUSIONS

Within the limitations of the current study the following conclusions can be drawn:

- Orthopantomograms are a valuable and reliable aid in Eagle's syndrome diagnosis. Inter and intra-examiner agreement, as well as inter-examination reproducibility was high;
- Both EAM and point of SP emersion from the temporal bone can be used as anatomical landmarks in stylohyoid complex measurements. Difference corresponds to the hidden part by the vaginal process. The correlation coefficient between the two methods was very high for both genders;
- The study concluded that a gender specific dependency of length and SP elongation had significantly higher values in males;
- Styloid process elongation was not side-related;
- Almost 31% of the examined OPGs revealed at least one elongated SP.

Styloid process is normally both detectable and measurable in OPGs. Even if the measurement may lack the absolute preciseness, an elongated SP is usually clearly depicted and must be kept in mind. Since symptoms of elongation may overlap with symptoms of TMD and since OPGs are routinely used, dental professionals must be familiar with this clinical and radiological entity.

Acknowledgements

We thank the Statistician Prof. Machaira-Kolyva Fotini for her valuable assistance in the statistical analysis.

REFERENCES

1. Alpoz E, Akar GC, Celik S, et al. Prevalence and pattern of stylohyoid chain complex patterns detected by panoramic radiographs among Turkish population. *Surg Radiol Anat.* 2014; 36(1): 39–46, doi: [10.1007/s00276-013-1137-x](https://doi.org/10.1007/s00276-013-1137-x), indexed in Pubmed: [23689822](https://pubmed.ncbi.nlm.nih.gov/23689822/).
2. de Andrade KM, Rodrigues CA, Watanabe PC, et al. Styloid process elongation and calcification in subjects with TMD: clinical and radiographic aspects. *Braz Dent J.* 2012; 23(4): 443–450, indexed in Pubmed: [23207864](https://pubmed.ncbi.nlm.nih.gov/23207864/).
3. Bagga MB, Kumar CA, Yeluri G. Clinoradiologic evaluation of styloid process calcification. *Imaging Sci Dent.* 2012; 42(3): 155–161, doi: [10.5624/isd.2012.42.3.155](https://doi.org/10.5624/isd.2012.42.3.155), indexed in Pubmed: [23071965](https://pubmed.ncbi.nlm.nih.gov/23071965/).
4. Bozkir MG, Boğa H, Dere F. The evaluation of elongated styloid process in panoramic radiographs in edentulous patients. *Turkish J Med Sci.* 1999; 29: 481–486.
5. Camarda AJ, Deschamps C, Forest D, et al. I. Stylohyoid chain ossification: a discussion of etiology. *Oral Surg Oral Med Oral Pathol.* 1989; 67(5): 508–514, indexed in Pubmed: [2497419](https://pubmed.ncbi.nlm.nih.gov/2497419/).
6. Camarda AJ, Deschamps C, Forest D, et al. II. Stylohyoid chain ossification: a discussion of etiology. *Oral Surg Oral Med Oral Pathol.* 1989; 67(5): 515–520, indexed in Pubmed: [2497420](https://pubmed.ncbi.nlm.nih.gov/2497420/).
7. Ceylan A, Köybaşıoğlu A, Celenk F, et al. Surgical treatment of elongated styloid process: experience of 61 cases. *Skull Base.* 2008; 18(5): 289–295, doi: [10.1055/s-0028-1086057](https://doi.org/10.1055/s-0028-1086057), indexed in Pubmed: [19240828](https://pubmed.ncbi.nlm.nih.gov/19240828/).
8. Correll RW, Jensen JL, Taylor JB, et al. Mineralization of the stylohyoid-stylomandibular ligament complex. A radiographic incidence study. *Oral Surg Oral Med Oral Pathol.* 1979; 48(4): 286–291, indexed in Pubmed: [116179](https://pubmed.ncbi.nlm.nih.gov/116179/).
9. Costantinides F, Vidoni G, Bodin C, et al. Eagle's syndrome: signs and symptoms. *Cranio.* 2013; 31(1): 56–60, doi: [10.1179/crn.2013.008](https://doi.org/10.1179/crn.2013.008), indexed in Pubmed: [23461263](https://pubmed.ncbi.nlm.nih.gov/23461263/).
10. De Paz FJ, Rueda C, Barbosa M, et al. Biometry and statistical analysis of the styloid process. *Anat Rec (Hoboken).* 2012; 295(5): 742–747, doi: [10.1002/ar.22452](https://doi.org/10.1002/ar.22452), indexed in Pubmed: [22467546](https://pubmed.ncbi.nlm.nih.gov/22467546/).
11. Dwight T. Stylo-hyoid ossification. *Ann Surg.* 1907; 46(5): 721–735, indexed in Pubmed: [17862068](https://pubmed.ncbi.nlm.nih.gov/17862068/).
12. Eagle WW. Elongated Styloid Processes: report of two cases. *Arch Otolaryngol Head Neck Surg.* 1937; 25(5): 584–587, doi: [10.1001/archotol.1937.00650010656008](https://doi.org/10.1001/archotol.1937.00650010656008).
13. Eagle WW. Elongated styloid process; further observations and a new syndrome. *Arch Otolaryngol.* 1948; 47(5): 630–640, indexed in Pubmed: [18894764](https://pubmed.ncbi.nlm.nih.gov/18894764/).
14. Eagle WW. Symptomatic elongated styloid process; report of two cases of styloid process-carotid artery syndrome with operation. *Arch Otolaryngol.* 1949; 49(5): 490–503, indexed in Pubmed: [18131173](https://pubmed.ncbi.nlm.nih.gov/18131173/).
15. Eagle WW. Elongated styloid process; symptoms and treatment. *AMA Arch Otolaryngol.* 1958; 67(2): 172–176, indexed in Pubmed: [13497389](https://pubmed.ncbi.nlm.nih.gov/13497389/).
16. Ferrario VF, Sigurtá D, Daddona A, et al. Calcification of the stylohyoid ligament: incidence and morphoquantitative evaluations. *Oral Surg Oral Med Oral Pathol.* 1990; 69(4): 524–529, indexed in Pubmed: [2326043](https://pubmed.ncbi.nlm.nih.gov/2326043/).
17. Fini G, Gasparini G, Filippini F, et al. The long styloid process syndrome or Eagle's syndrome. *J Craniomaxillofac Surg.* 2000; 28(2): 123–127, doi: [10.1054/jcms.2000.0128](https://doi.org/10.1054/jcms.2000.0128), indexed in Pubmed: [10958426](https://pubmed.ncbi.nlm.nih.gov/10958426/).
18. Frommer J. Anatomic variations in the stylohyoid chain and their possible clinical significance. *Oral Surg Oral Med Oral Pathol.* 1974; 38(5): 659–667, indexed in Pubmed: [4530957](https://pubmed.ncbi.nlm.nih.gov/4530957/).
19. Fritz M. Elongated styloid process: a cause of obscure throat symptoms. *Arch Otolaryngol Head Neck Surg.* 1940; 31(6): 911–918, doi: [10.1001/archotol.1940.00660010926002](https://doi.org/10.1001/archotol.1940.00660010926002).
20. Fusco DJ, Asteraki S, Spetzler RF. Eagle's syndrome: embryology, anatomy, and clinical management. *Acta Neurochir (Wien).* 2012; 154(7): 1119–1126, doi: [10.1007/s00701-012-1385-2](https://doi.org/10.1007/s00701-012-1385-2), indexed in Pubmed: [22638594](https://pubmed.ncbi.nlm.nih.gov/22638594/).
21. Ghosh LM, Dubey SP. The syndrome of elongated styloid process. *Auris Nasus Larynx.* 1999; 26(2): 169–175, indexed in Pubmed: [10214896](https://pubmed.ncbi.nlm.nih.gov/10214896/).
22. Ghosh S, Vengal M, Pai KM, et al. Remodeling of the antegonial angle region in the human mandible: a panoramic radiographic cross-sectional study. *Med Oral Patol Oral Cir Bucal.* 2010; 15(5): e802–e807, indexed in Pubmed: [20383108](https://pubmed.ncbi.nlm.nih.gov/20383108/).
23. Gokce C, Sisman Y, Ertas ET, et al. Prevalence of styloid process elongation on panoramic radiography in the Turkey population from cappadocia region. *Eur J Dent.* 2008; 2(1): 18–22, indexed in Pubmed: [19212504](https://pubmed.ncbi.nlm.nih.gov/19212504/).
24. Goldstein GR, Scopp IW. Radiographic interpretation of calcified stylomandibular and stylohyoid ligaments. *J Prosthet Dent.* 1973; 30(3): 330–334, indexed in Pubmed: [4516436](https://pubmed.ncbi.nlm.nih.gov/4516436/).
25. Gossman JR, Tarsitano JJ. The styloid-stylohyoid syndrome. *J Oral Surg.* 1977; 35(7): 555–560, indexed in Pubmed: [406372](https://pubmed.ncbi.nlm.nih.gov/406372/).
26. Gözül R, Yener N, Calgüner E, et al. Morphological characteristics of styloid process evaluated by computerized axial tomography. *Ann Anat.* 2001; 183(6): 527–535, doi: [10.1016/S0940-9602\(01\)80060-1](https://doi.org/10.1016/S0940-9602(01)80060-1), indexed in Pubmed: [11766524](https://pubmed.ncbi.nlm.nih.gov/11766524/).
27. Härmä R. Styralgia: clinical experiences of 52 cases. *Acta Otolaryngol.* 1967; Suppl 224: 149–155, indexed in Pubmed: [5992663](https://pubmed.ncbi.nlm.nih.gov/5992663/).

28. Iannetti G. Clinical-Radiographic analysis of eagle syndrome atheroma of the carotid artery detected on a lateral radiograph. *J Craniofac Surg.* 2014; 25: 1578–1579.
29. Jung T, Tschernitschek H, Hippen H, et al. Elongated styloid process: when is it really elongated? *Dentomaxillofac Radiol.* 2004; 33(2): 119–124, doi: [10.1259/dmfr/13491574](https://doi.org/10.1259/dmfr/13491574), indexed in Pubmed: [15314005](https://pubmed.ncbi.nlm.nih.gov/15314005/).
30. Ilgüy M, Ilgüy D, Güler N, et al. Incidence of the type and calcification patterns in patients with elongated styloid process. *J Int Med Res.* 2005; 33(1): 96–102, doi: [10.1177/147323000503300110](https://doi.org/10.1177/147323000503300110), indexed in Pubmed: [15651721](https://pubmed.ncbi.nlm.nih.gov/15651721/).
31. Kaufman SM, Elzay RP, Irish EF. Styloid process variation. Radiologic and clinical study. *Arch Otolaryngol.* 1970; 91(5): 460–463, indexed in Pubmed: [5442737](https://pubmed.ncbi.nlm.nih.gov/5442737/).
32. Keur JJ, Campbell JP, McCarthy JF, et al. The clinical significance of the elongated styloid process. *Oral Surg Oral Med Oral Pathol.* 1986; 61(4): 399–404, indexed in Pubmed: [3458151](https://pubmed.ncbi.nlm.nih.gov/3458151/).
33. Koivumäki A, Marinescu-Gava M, Järnstedt J, et al. Trauma induced eagle syndrome. *Int J Oral Maxillofac Surg.* 2012; 41(3): 350–353, doi: [10.1016/j.ijom.2011.12.031](https://doi.org/10.1016/j.ijom.2011.12.031), indexed in Pubmed: [22244077](https://pubmed.ncbi.nlm.nih.gov/22244077/).
34. Krennmair G, Piehslinger E. The incidence and influence of abnormal styloid conditions on the etiology of craniomandibular functional disorders. *Cranio.* 1999; 17(4): 247–253, indexed in Pubmed: [10650396](https://pubmed.ncbi.nlm.nih.gov/10650396/).
35. Krennmair G, Piehslinger E. Variants of ossification in the stylohyoid chain. *Cranio.* 2003; 21(1): 31–37, indexed in Pubmed: [12555929](https://pubmed.ncbi.nlm.nih.gov/12555929/).
36. Kursoglu P, Unalan F, Erdem T. Radiological evaluation of the styloid process in young adults resident in Turkey's Yeditepe University faculty of dentistry. *Oral Surg Oral Med Oral Pathol Oral Radiol Endod.* 2005; 100(4): 491–494, doi: [10.1016/j.tripleo.2005.05.061](https://doi.org/10.1016/j.tripleo.2005.05.061), indexed in Pubmed: [16182171](https://pubmed.ncbi.nlm.nih.gov/16182171/).
37. Langlais RP, Miles DA, Van Dis ML. Elongated and mineralized stylohyoid ligament complex: a proposed classification and report of a case of Eagle's syndrome. *Oral Surg Oral Med Oral Pathol.* 1986; 61(5): 527–532, indexed in Pubmed: [3459129](https://pubmed.ncbi.nlm.nih.gov/3459129/).
38. Leite HF, Niccoli Filho WD, Liberti EA, et al. [Prevalence of elongated styloid process in human skulls]. *Rev Odontol UNESP.* 1988; 17(1): 145–151, indexed in Pubmed: [3151022](https://pubmed.ncbi.nlm.nih.gov/3151022/).
39. Lengelé BG, Dhém AJ. Length of the styloid process of the temporal bone. *Arch Otolaryngol Head Neck Surg.* 1988; 114(9): 1003–1006, indexed in Pubmed: [3408565](https://pubmed.ncbi.nlm.nih.gov/3408565/).
40. MacDonald-Jankowski DS. Calcification of the stylohyoid complex in Londoners and Hong Kong Chinese. *Dentomaxillofac Radiol.* 2001; 30(1): 35–39, doi: [10.1038/sj/dmfr/4600574](https://doi.org/10.1038/sj/dmfr/4600574), indexed in Pubmed: [11175271](https://pubmed.ncbi.nlm.nih.gov/11175271/).
41. Moffat DA, Ramsden RT, Shaw HJ. The styloid process syndrome: aetiological factors and surgical management. *J Laryngol Otol.* 1977; 91(4): 279–294, indexed in Pubmed: [856922](https://pubmed.ncbi.nlm.nih.gov/856922/).
42. Monsour PA, Young WG. Variability of the styloid process and stylohyoid ligament in panoramic radiographs. *Oral Surg Oral Med Oral Pathol.* 1986; 61(5): 522–526, indexed in Pubmed: [3086788](https://pubmed.ncbi.nlm.nih.gov/3086788/).
43. More CB, Asrani MK. Evaluation of the styloid process on digital panoramic radiographs. *Indian J Radiol Imaging.* 2010; 20(4): 261–265, doi: [10.4103/0971-3026.73537](https://doi.org/10.4103/0971-3026.73537), indexed in Pubmed: [21423900](https://pubmed.ncbi.nlm.nih.gov/21423900/).
44. Murtagh RD, Caracciolo JT, Fernandez G. CT findings associated with Eagle syndrome. *AJNR Am J Neuroradiol.* 2001; 22(7): 1401–1402, indexed in Pubmed: [11498437](https://pubmed.ncbi.nlm.nih.gov/11498437/).
45. Natsis K, Repousi E, Nouisios G, et al. The styloid process in a Greek population: an anatomical study with clinical implications. *Anat Sci Int.* 2015; 90(2): 67–74, doi: [10.1007/s12565-014-0232-3](https://doi.org/10.1007/s12565-014-0232-3), indexed in Pubmed: [24664363](https://pubmed.ncbi.nlm.nih.gov/24664363/).
46. O'Carroll MK. Calcification in the stylohyoid ligament. *Oral Surg Oral Med Oral Pathol.* 1984; 58(5): 617–621, indexed in Pubmed: [6595625](https://pubmed.ncbi.nlm.nih.gov/6595625/).
47. Omnell KA, Gandhi C, Omnell ML. Ossification of the human stylohyoid ligament: a longitudinal study. *Oral Surg Oral Med Oral Pathol Oral Radiol Endod.* 1998; 85(2): 226–232, indexed in Pubmed: [9503461](https://pubmed.ncbi.nlm.nih.gov/9503461/).
48. Öztaş B, Orhan K. Investigation of the incidence of stylohyoid ligament calcifications with panoramic radiographs. *J Investig Clin Dent.* 2012; 3(1): 30–35, doi: [10.1111/j.2041-1626.2011.00081.x](https://doi.org/10.1111/j.2041-1626.2011.00081.x), indexed in Pubmed: [22298518](https://pubmed.ncbi.nlm.nih.gov/22298518/).
49. Palesy P, Murray GM, De Boever J, et al. The involvement of the styloid process in head and neck pain: a preliminary study. *J Oral Rehabil.* 2000; 27(4): 275–287, indexed in Pubmed: [10792587](https://pubmed.ncbi.nlm.nih.gov/10792587/).
50. Patil S. Morphometric study of the styloid process of temporal bone. *J Clin Diagn Res.* 2014; 8: 4–6, doi: [10.7860/jcdr/2014/9419.4867](https://doi.org/10.7860/jcdr/2014/9419.4867).
51. Piagkou M, Anagnostopoulou S, Kouladouros K, et al. Eagle's syndrome: a review of the literature. *Clin Anat.* 2009; 22(5): 545–558, doi: [10.1002/ca.20804](https://doi.org/10.1002/ca.20804), indexed in Pubmed: [19418452](https://pubmed.ncbi.nlm.nih.gov/19418452/).
52. Prasad KC, Kamath MP, Reddy KJ, et al. Elongated styloid process (Eagle's syndrome): a clinical study. *J Oral Maxillofac Surg.* 2002; 60(2): 171–175, indexed in Pubmed: [11815916](https://pubmed.ncbi.nlm.nih.gov/11815916/).
53. Radfar L, Amjadi N, Aslani N, et al. Prevalence and clinical significance of elongated calcified styloid processes in panoramic radiographs. *Gen Dent.* 2008; 56(6): e29–e32, indexed in Pubmed: [21444269](https://pubmed.ncbi.nlm.nih.gov/21444269/).
54. Rath G, Anand C. Abnormal styloid process in a human skull. *Surg Radiol Anat.* 1991; 13(3): 227–229, indexed in Pubmed: [1754958](https://pubmed.ncbi.nlm.nih.gov/1754958/).
55. Reddy RS, Sai Kiran Ch, Sai Madhavi N, et al. Prevalence of elongation and calcification patterns of elongated styloid process in south India. *J Clin Exp Dent.* 2013; 5(1): e30–e35, doi: [10.4317/jced.50981](https://doi.org/10.4317/jced.50981), indexed in Pubmed: [24455048](https://pubmed.ncbi.nlm.nih.gov/24455048/).
56. Roopashri G, Vaishali MR, David MP, et al. Evaluation of elongated styloid process on digital panoramic radiographs. *J Contemp Dent Pract.* 2012; 13(5): 618–622, indexed in Pubmed: [23250163](https://pubmed.ncbi.nlm.nih.gov/23250163/).
57. Sancio-Gonçalves FC, de Abreu MH, Netto Soares JM, et al. Stylohyoid complex ossification in temporomandibular disorder: a case-control study. *J Prosthet Dent.* 2013; 109(2): 79–82, doi: [10.1016/S0022-3913\(13\)60019-0](https://doi.org/10.1016/S0022-3913(13)60019-0), indexed in Pubmed: [23395332](https://pubmed.ncbi.nlm.nih.gov/23395332/).
58. Scaf G, Freitas DQ, De Loffredo LDCM. Diagnostic reproducibility of the elongated styloid process. *J Appl Oral Sci.* 2003; 11(2): 120–124, indexed in Pubmed: [21409324](https://pubmed.ncbi.nlm.nih.gov/21409324/).
59. Siéssere S, Vitti M, de Sousa LG, et al. Changes in masticatory muscles activity associated with Eagle's syndrome. *Electromyogr Clin Neurophysiol.* 2006; 46(4): 223–228, indexed in Pubmed: [16929628](https://pubmed.ncbi.nlm.nih.gov/16929628/).
60. Slavicek R. Clinical functional analysis with the aid of instrumental devices. *The Masticatory Organ.* English Ed. GAMMA Medizinisch. 2002: 384.
61. Stafne EC, Hollinshead WH. Roentgenographic observations on the stylohyoid chain. *Oral Surg Oral Med Oral Pathol.* 1962; 15: 1195–1200, indexed in Pubmed: [13978697](https://pubmed.ncbi.nlm.nih.gov/13978697/).
62. Sokler K, Sandev S. New classification of the styloid process length-clinical application on the biological base. *Coll Antropol.* 2001; 25(2): 627–632, indexed in Pubmed: [11811294](https://pubmed.ncbi.nlm.nih.gov/11811294/).
63. Vieira EM, Guedes OA, Morais SDe, et al. Prevalence of elongated styloid process in a central Brazilian population. *J Clin Diagn Res.* 2015; 9(9): ZC90–ZC92, doi: [10.7860/JCDR/2015/14599.6567](https://doi.org/10.7860/JCDR/2015/14599.6567), indexed in Pubmed: [26501021](https://pubmed.ncbi.nlm.nih.gov/26501021/).
64. Yamashita M. Radiographic images of the styloid process. *J Osaka Odontol Soc.* 2002; 65: 165–180.
65. Zaki HS, Greco CM, Rudy TE, et al. Elongated styloid process in a temporomandibular disorder sample: prevalence and treatment outcome. *J Prosthet Dent.* 1996; 75(4): 399–405, indexed in Pubmed: [8642526](https://pubmed.ncbi.nlm.nih.gov/8642526/).