

Ponticulus posticus in a cohort of orthodontic children and adolescent patients with different sagittal skeletal anomalies: a comparative cone beam computed tomography investigation

İ.Ş. Bayrakdar¹, Ö. Miloğlu², S. Yeşiltepe², A.B. Yılmaz²

¹Department of Oral and Maxillofacial Radiology, Faculty of Dentistry, Eskisehir Osmangazi University, Eskisehir, Turkey

²Department of Oral and Maxillofacial Radiology, Faculty of Dentistry, Ataturk University, Erzurum, Turkey

[Received: 2 July 2017; Accepted: 4 August 2017]

Background: The objective of this study was to evaluate the prevalence and characteristics of ponticulus posticus (PP) in groups with sagittal skeletal anomalies in a Turkish population using cone beam computed tomography (CBCT).

Materials and methods: A total of 181 CBCT images were evaluated according to gender, side and characteristics of PP in the three different sagittal skeletal groups.

Results: The average age of the patients was 13.88 ± 2.99 years (ranging 8–18 years). The study population consisted of 104 (57.5%) females and 77 (42.5%) males. PP was detected in 66 (36.5%) patients. Unilateral and bilateral PP was identified in 29 (43.9%) and 37 (56.1%) patients, respectively. The prevalence of PP in the atlas vertebrae was found to be higher in males than in females and this was statistically significant ($p \leq 0.05$). PP was most frequently detected in class III patients (25, 13.8%). Statistically significant differences between the different sagittal skeletal groups were observed ($p \leq 0.05$).

Conclusions: Ponticulus posticus is a common anomaly in Turkish populations and is associated with different sagittal skeletal patterns. The highest frequency of PP was found in angle class III patients. (Folia Morphol 2018; 77, 1: 65–71)

Key words: ponticulus posticus, malocclusions, cone beam computed tomography

INTRODUCTION

Ponticulus posticus (PP) is a bony variation of the atlas that consists of a complete or partial calcified bridge over the vertebral groove of the posterior arch [4, 28].

Ponticulus posticus, meaning “little bony bridge” in Latin, is described using various names, including arcuate foramen, Kimmerle’s anomaly, foramen arcuale, foramen sagittal, foramen atlantoideum posterius, retroarticular vertebral artery and canalis vertebralis [3, 4, 10, 23, 29, 34]. It has been shown in studies

in the literature that PP is of clinical significance and that an understanding of PP is especially important for the management of cervical spine surgery. PP has been associated with vertebrobasilar insufficiency, headaches, cervical pain syndrome, migraines and hearing loss. The use of lateral mass screws to fixate the atlas has also become an important anatomical procedural variation to the lateral mass screw procedure used for the treatment of atlantoaxial instability (excessive movement at the junction between the atlas and axis vertebrae). This variation causes many

Address for correspondence: S. Yeşiltepe, Assistant Research, Department of Oral and Maxillofacial Radiology, Faculty of Dentistry, Ataturk University, 25240, Erzurum, Turkey, e-mail: dt_selin@yahoo.com

neurological symptoms, including balance problems, blurred vision, migraines, tinnitus and vertigo [3–5, 21, 24, 31–33].

The incidence of PP has been assessed in many different study populations in the literature with the use of cephalometric radiography, computed tomography (CT), cone beam CT (CBCT) and cadaver dissection. It has also been evaluated in relation to dental malocclusion, the elongated styloid process, and cleft lips and palates [4, 6, 32, 33].

Adisen and Misirlioglu [1] conducted a systematic review of several studies in which the relationship between cervical vertebrae morphology and mandible position was evaluated and sought to determine the prevalence of PP in various dental malocclusion groups. No such association was observed. The recommendation was that the expression of PP in different dentoskeletal patterns should be investigated in future studies [1]. Although we assumed that different sagittal skeletal patterns of PP would be found, to the best of our knowledge the prevalence and characteristics of PP found within different sagittal skeletal patterns has not been assessed to date in any study. Thus, the study objective was to evaluate the prevalence and characteristics of PP in groups with sagittal skeletal anomalies including skeletal class I, II or III in a Turkish population using CBCT.

MATERIALS AND METHODS

A retrospective study was designed, consisting of CBCT images of 181 patients presenting at the Faculty of Dentistry, Ataturk University, Erzurum, Turkey. All the patients had been referred for diagnosis and orthodontic treatment. Patients with trauma, congenital anomalies and syndromic conditions, like cleft lip and palate, were excluded from the study. Images in which the cervical vertebrae could not properly be seen were also excluded from the study.

A total of 181 CBCT images of patients aged 8–18 years (a mean age of 13.88 ± 2.99 years) were examined. The study population comprised 77 male and 104 female patients. CBCT imaging was performed using flat-panel CBCT equipment (NewTom 3G®; Quantitative Radiology [QR], Verona, Italy). The patient was placed in a horizontal position with the Frankfort horizontal plane perpendicular to the table. A scan of the patient's head was performed using 360° rotation with an X-ray tube-detector system. The scan lasted for 36 s. The scanner operated at a maximum output of 110 kVp and 15 mAs,

a 0.16 mm voxel size was used and the exposure time was 5.4 s. QR-NNT® (version 2.21) software (Quantitative Radiology) was used to evaluate the CBCT images.

The presence or absence and PP characteristics were determined by examining the images of the sagittal sections. Initially, the three-dimensional (3D) image was reconstructed and the direction of the PP was determined on 3D imaging. PP direction was adjusted on the axial image using the rendering mode for multiplanar reconstruction in the QR-NNT® software. Images of the sagittal sections were used to detect PP based on its direction in relation to the atlas vertebrae. In this study, a complete PP was considered to be as one steady bridge extending from the posterior facet of the lateral mass to the anterior facet of the posterior tubercle. A partial PP was taken to be one that did not quite extend from the posterior lateral mass to the posterior tubercle (Figs. 1, 2).

The anteroposterior skeletal relationship of the maxilla and mandible was classified as skeletal class I, II or III, using A point-nasion-B point (ANB) angle measurements (an ANB angle of $0-4^\circ$ [class I], an ANB angle of $> 4^\circ$ [class II] and an ANB angle of $< 0^\circ$ [class III]) identified on CBCT imaging (sagittal viewing plane).

Two oral and maxillofacial radiologists with experience of CBCT imaging performed the evaluation and categorisation of PP. Conflict regarding the categorisation decisions taken was resolved by consensus. SPSS® (version 20.0) for Windows® (SPSS Inc., Chicago, USA) was used for the statistical analysis. The χ^2 test was used to evaluate PP differences between the groups. A p-value of 0.050 was considered to represent statistical significance.

RESULTS

The average age of the 181 patients was 13.88 ± 2.99 years (a range of 8–18 years). The study population consisted of 104 (57.5%) females and 77 (42.5%) males. The mean age of the females was 14.36 ± 2.73 years and that of the males, 13.25 ± 3.25 years. PP was detected in 66 (36.5%) of the 181 subjects. Unilateral and bilateral PP was identified in 29 (43.9%) and 37 (56.1%) patients, respectively. The distribution of PP in the atlas vertebrae was shown to be higher in males than that in females. The prevalence of PP in the atlas vertebrae was found to be higher in males than in females and this was statistically significant ($p \leq 0.05$). The distribution of PP according to gender, side and characteristics is summarised in Tables 1 and 2.

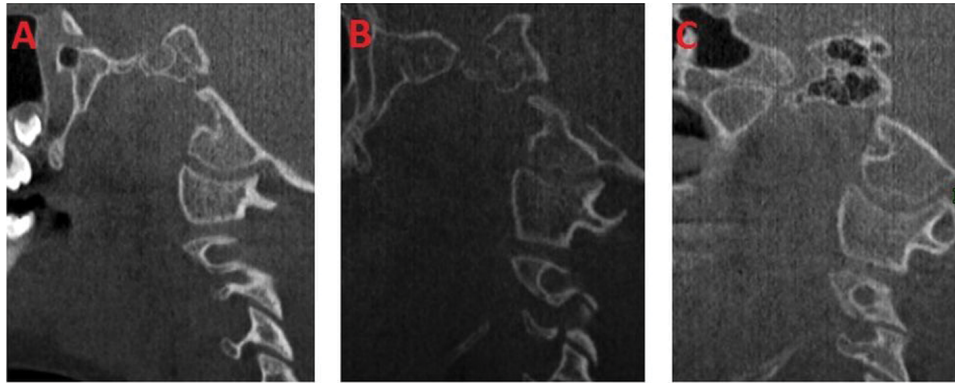


Figure 1. Sagittal cone beam computed tomography images; **A.** Absence of ponticulus posticus; **B.** Partial ponticulus posticus; **C.** Complete ponticulus posticus.

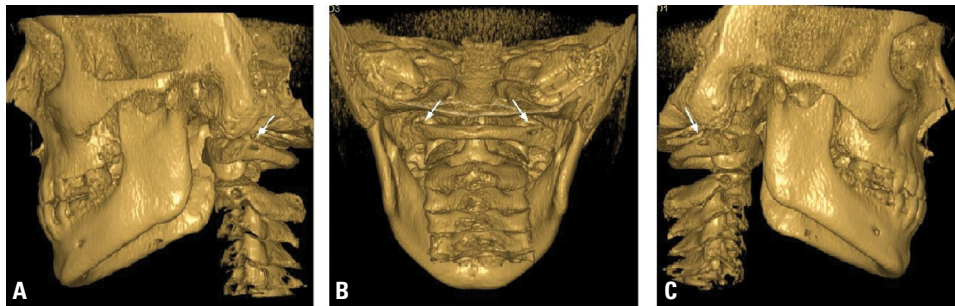


Figure 2. A–C. Three-dimensional images of bilateral complete ponticulus posticus.

Table 1. Distribution of ponticulus posticus (PP) according to gender

PP	Gender		Total	P
	Female	Male		
Absent	76 (42.0%)	39 (21.5%)	115 (63.5%)	0.003*
Present	28 (15.5%)	38 (21.0%)	66 (36.5%)	
Total	104 (57.5%)	77 (42.5%)	181(100%)	

*p < 0.05: statistically significantly different

Table 2. Details of the ponticulus posticus (PP) according to characteristics and side

PP	Male	Female	Total
Bilateral absent	39 (50.7%)	76 (73.1%)	115 (63.5%)
Right absent-left complete	0 (0.0%)	1 (0.9%)	1 (0.6%)
Right absent-left partial	7 (9.1%)	9 (8.7%)	16 (8.8%)
Bilateral complete	5 (6.5%)	2 (1.9%)	7 (3.9%)
Right complete-left partial	1 (1.3%)	2 (1.9%)	3 (1.7%)
Right partial-left absent	6 (7.8%)	6 (5.8%)	12 (6.6%)
Right partial-left complete	2 (2.6%)	3 (2.9%)	5 (2.8%)
Bilateral partial	17 (22.1%)	5 (4.8%)	22 (12.2%)

Table 3. Distribution of the ponticulus posticus (PP) according to different sagittal skeletal pattern

PP	Sagittal skeletal pattern			Total	P
	Class I	Class II	Class III		
Absent	54 (29.8%)	37 (20.4%)	24 (13.3%)	115 (63.5%)	
Present	19 (10.5%)	22 (12.2%)	25 (13.8%)	66 (36.5%)	0.019*
Total	73 (40.3%)	59 (32.6%)	49 (27.1%)	181 (100%)	

*p < 0.05: statistically significant difference

PP was most frequently detected in class III patients (25, 13.8%) and then in class II (22, 12.2%) and class I patients (19, 10.5%). Statistically significant differences between the different sagittal skeletal groups were observed ($p \leq 0.05$). The distribution of PP according to the different sagittal skeletal pattern groups is summarised in Table 3.

DISCUSSION

Although the origin and clinical significance of PP are not well-defined, it is nevertheless important to understand its prevalence and morphological characteristics. The embryological origin of the variation is unclear. The presence of a lamellar pattern within the bone matrix and cortex, signifying endochondral ossification, suggests that PP may arise from the dorsal arch of atlas. The foramen of the first cervical nerve is frequently seen in most vertebrates, suggestive of another possible indication. It has been reported that PP could be the result of complete or incomplete ossification of the posterior atlanto-occipital membrane over the vertebral artery groove. It could develop to protect the portion of the vertebral artery during head and neck movement [15, 24, 34].

Ponticulus posticus is a simple anatomical variation that seems to occur in different clinical situations. PP has been studied widely because of its important anatomical location and the involvement of critical structures. PP has been associated with headaches, vertebrobasilar insufficiency, cervical pain syndrome, shoulder or arm pain, migraine without aura and acute hearing loss [1, 6, 14, 15]. Lamberty and Zivanovic [25] demonstrated that it is a causative mechanism in headaches, vertigo, Barré-Liéou syndrome, eye pain and photophobia owing to the compression of the vertebral artery.

In their radiological study, Takaaki et al. [37] demonstrated that the incidence of PP was higher in patients with at least one narrow disc space. An

association between PP and the elongated styloid process has also been reported [32]. It was shown in a study by Leonardi et al. [26] that calcification of the atlanto-occipital ligament should be considered a major criterion for nevoid basal cell carcinoma syndrome. Elsewhere, Friedrich reported that PP was a frequent radiographic finding on lateral cephalograms in nevoid basal cell carcinoma syndrome [13].

To evaluate the prevalence of PP, different techniques, such as lateral cephalometric radiographs, CT, CBCT, cadaver dissection or the examination of dried atlas specimens, have been used in various populations. The prevalence rate of PP has been reported to be 1–46% [4, 33]. In 2014, Elliott and Tanweer [10] performed a meta-analysis of studies relating to this anatomical variation and reported that the overall mean prevalence of PP was 17%; 19% for cadavers, 17% on CT scans and 17% on lateral radiographs. Complete and partial PP occurs in 10% and 9% of cases, respectively. It is bilateral in 5% and unilateral in 8% of cases. A meta-analysis study conducted by Pękala et al. [30] reported that the overall prevalence of a complete foramen arcuale was 9.1% versus an incomplete foramen arcuale, which was 13.6%. The complete foramen arcuale was found to be most common in North Americans (11.3%) and Europeans (11.2%), and least prevalent among Asians (7.5%). In males (10.4%) the complete foramen arcuale was more common than in females (7.3%) but an incomplete foramen arcuale was more commonly seen in females (18.5%) than in males (16.7%). They suggest preoperative screening with CT as the gold standard for detecting the presence of a foramen arcuale. Generally, a statistically significant difference between males and females with regard to PP incidence has not been found. A study was performed by Sharma et al. [34] in which lateral cephalometric radiographs were used to identify PP of the atlas in 858 Indian orthodontic patients, aged 8–22 years. In this

study, complete PP was found in 4% of the subjects, with a higher prevalence in males than in females. Paraskevas et al. [28] reported that the development of PP relates to age and the progressive mineralisation of the bony bridge from partial to complete ossification over time. Kendrick and Biggs [19] conducted a study using lateral cephalometric radiographs to evaluate PP in 353 young Caucasian orthodontic patients, aged 6–17 years. Some degree of PP was seen in 16% of these subjects. There was no possible gender predilection. The youngest girl and boy with PP were aged 6 years, 7 months and 6 years, 4 months, respectively. This suggests that age is not a criterion for the occurrence of PP.

Buyuk et al. [5] were the first to evaluate the presence of PP in orthodontic patients using CBCT. They examined 3D CBCT images of a Turkish subpopulation and realised that as much as 43% of the patient population had PP. They concluded that its presence should be carefully determined prior to screw placement in the lateral mass of the atlas in order to avoid vertebral artery injury. The use of lateral radiographs to identify PP is used in most studies. Thus, making an attempt to determine whether PP is bi- or unilateral is not typical [4, 33].

Atlantoaxial instability is a widespread problem and is caused by a variety of situations. Posterior atlantoaxial fusion surgery is an effective treatment in this regard. The C1 lateral mass screw insertion procedure is the most common treatment option used for C1 fixation [4, 7, 9, 16, 17, 34, 38]. As complete PP constitutes a thickened posterior arch, the selection of an entry point through the cranium is required. This procedure can easily damage the vertebral artery, resulting in life-threatening complications, such as a stroke, thrombosis, embolism or arterial dissection [4, 7, 10, 19, 21, 34]. Thus, PP is a major clinical variation, potentially involving numerous complications.

An association between cervical vertebral anomalies and mandible position has been reported in several studies in the literature [8, 12, 22, 27]. Kamak and Yildirim [18] examined the distribution of cervical vertebral anomalies in dental malocclusions and did not find a statistically significant correlation between the two. Adisen and Misirlioglu [1] investigated any differences in PP within different groups with dental malocclusion using lateral radiography. PP was most frequently found in angle class III patients, followed by class II and I patients. A statistically significant difference in

the prevalence of PP was not reported for any of the malocclusion groups. A higher incidence of PP was found in patients aged 10–19 years than in any other age group and PP was predominantly observed in males. The classification and evaluation of orthodontic malocclusions are usually performed based on differences in clinical manifestations, and cephalometric morphology and aetiology. The ability to accurately evaluate skeletal rather than dental malocclusion is greater because the former is unaffected by caries, dental extractions, impaction and tooth-size conflicts. Furthermore, the anterior cranial base regions are stable after 7 years of age, meaning that they are considered to be reliable cranial-base cephalometric and skeletal landmark areas [2, 35]. In the literature, previous studies were reported that there was correlation between cervical vertebrae anomalies and vertebrae morphology, craniofacial malformations, and skeletal malocclusions. The prevalence of cervical vertebral anomalies were higher in patients with severe skeletal malocclusion including skeletal class I, I or III [11, 34]. During the early prenatal period, occurrence of these differences are still unclear. Because of the fact that notochord in the development of cervical vertebral bodies and basilar part of occipital bone that comprised of posterior part of cranial base. Since the cervical vertebrae and cranial base have similar embryonic origin, and the jaws are related to the cranial base, it could be considered as a cause of link between the cervical vertebral anomalies and skeletal malocclusions.

CONCLUSIONS

The prevalence and characteristics of PP was evaluated in groups with different sagittal skeletal anomalies (skeletal class I, II or III) in a Turkish population using ANB angle measurements adapted for dental malocclusion in the current study. PP was found to be a common variation. A greater incidence of PP was observed in ANB angle class III patients. Statistically significant differences were noted in relation to different sagittal skeletal patterns within the groups.

Acknowledgements

All procedures followed were in accordance with the ethical standards of the responsible committee on human experimentation (institutional and national) and with the Helsinki Declaration of 1975, as revised in 2008 [10].

REFERENCES

- Adisen MZ, Misirlioglu M. Prevalence of ponticulus posticus among patients with different dental malocclusions by digital lateral cephalogram: a comparative study. *Surg Radiol Anat.* 2017; 39(3): 293–297, doi: 10.1007/s00276-016-1728-4, indexed in Pubmed: 27515304.
- Afrand M, Ling CP, Khosrotehrani S, et al. Anterior cranial-base time-related changes: A systematic review. *Am J Orthod Dentofacial Orthop.* 2014; 146(1): 21–32. e6, doi: 10.1016/j.ajodo.2014.03.019, indexed in Pubmed: 24974995.
- Afsharpour S, Hoiriis KT, Fox RB, et al. An anatomical study of arcuate foramen and its clinical implications: a case report. *Chiropr Man Therap.* 2016; 24: 4, doi: 10.1186/s12998-016-0082-2, indexed in Pubmed: 26811743.
- Bayrakdar IS, Miloglu O, Altun O, et al. Cone beam computed tomography imaging of ponticulus posticus: prevalence, characteristics, and a review of the literature. *Oral Surg Oral Med Oral Pathol Oral Radiol.* 2014; 118(6): e210–e219, doi: 10.1016/j.oooo.2014.09.014, indexed in Pubmed: 25457896.
- Buyuk SK, Sekerci AE, Benkli YA, et al. A survey of ponticulus posticus: Radiological analysis of atlas in an orthodontic population based on cone-beam computed tomography. *Niger J Clin Pract.* 2017; 20(1): 106–110, doi: 10.4103/1119-3077.178916, indexed in Pubmed: 27958256.
- Chen CH, Chen YK, Wang CK. Prevalence of ponticuli posticus among patients referred for dental examinations by cone-beam CT. *Spine J.* 2015; 15(6): 1270–1276, doi: 10.1016/j.spinee.2015.02.031, indexed in Pubmed: 25720728.
- Chitroda PK, Katti G, Baba IA, et al. Ponticulus posticus on the posterior arch of atlas, prevalence analysis in symptomatic and asymptomatic patients of gulbarga population. *J Clin Diagn Res.* 2013; 7(12): 3044–3047, doi: 10.7860/JCDR/2013/6795.3847, indexed in Pubmed: 24551723.
- D'Attilio M, Epifania E, Ciuffolo F, et al. Cervical lordosis angle measured on lateral cephalograms; findings in skeletal class II female subjects with and without TMD: a cross sectional study. *Cranio.* 2004; 22(1): 27–44, doi: 10.1179/crn.2004.005, indexed in Pubmed: 14964336.
- Elgafy H, Pompo F, Vela R, et al. Ipsilateral arcuate foramen and high-riding vertebral artery: implication on C1-C2 instrumentation. *Spine J.* 2014; 14(7): 1351–1355, doi: 10.1016/j.spinee.2014.01.054, indexed in Pubmed: 24509004.
- Elliott RE, Tanweer O. The prevalence of the ponticulus posticus (arcuate foramen) and its importance in the Goel-Harms procedure: meta-analysis and review of the literature. *World Neurosurg.* 2014; 82(1-2): e335–e343, doi: 10.1016/j.wneu.2013.09.014, indexed in Pubmed: 24055572.
- Faruqui S, Fida M, Shaikh A. Cervical vertebral anomalies in skeletal malocclusions: a cross-sectional study on orthodontic patients at the Aga Khan University Hospital, Pakistan. *Indian J Dent Res.* 2014; 25(4): 480–484, doi: 10.4103/0970-9290.142542, indexed in Pubmed: 25307913.
- Festa F, Tecco S, Dolci M, et al. Relationship between cervical lordosis and facial morphology in Caucasian women with a skeletal class II malocclusion: a cross-sectional study. *Cranio.* 2003; 21(2): 121–129, indexed in Pubmed: 12723858.
- Friedrich RE. Ponticulus posticus is a frequent radiographic finding on lateral cephalograms in nevoid basal cell carcinoma syndrome (Gorlin-Goltz syndrome). *Anticancer Res.* 2014; 34(12): 7395–7399, indexed in Pubmed: 25503179.
- Geist JR, Geist SMRY, Lin LM. A cone beam CT investigation of ponticulus posticus and lateralis in children and adolescents. *Dentomaxillofac Radiol.* 2014; 43(5): 20130451, doi: 10.1259/dmfr.20130451, indexed in Pubmed: 24785819.
- Gibelli D, Cappella A, Cerutti E, et al. Prevalence of ponticulus posticus in a Northern Italian orthodontic population: a lateral cephalometric study. *Surg Radiol Anat.* 2016; 38(3): 309–312, doi: 10.1007/s00276-015-1554-0, indexed in Pubmed: 26365050.
- Goel A, Desai KI, Muzumdar DP. Atlantoaxial fixation using plate and screw method: a report of 160 treated patients. *Neurosurgery.* 2002; 51(6): 1351–1357, indexed in Pubmed: 12445339.
- Goel A. Screws, facets, and atlantoaxial instability. *World Neurosurg.* 2013; 80(5): 514–515, doi: 10.1016/j.wneu.2012.05.020, indexed in Pubmed: 22641187.
- Kamak H, Yildirim E. The distribution of cervical vertebrae anomalies among dental malocclusions. *J Craniovertebr Junction Spine.* 2015; 6(4): 158–161, doi: 10.4103/0974-8237.167857, indexed in Pubmed: 26692691.
- Kendrick GS, Biggs NL. Incidence of the ponticulus posticus of the first cervical vertebra between ages six to seventeen. *Anat Rec.* 1963; 145: 449–453, indexed in Pubmed: 14031912.
- Kim KH, Park KW, Manh TH, et al. Prevalence and morphologic features of ponticulus posticus in Koreans: analysis of 312 radiographs and 225 three-dimensional CT scans. *Asian Spine J.* 2007; 1(1): 27–31, doi: 10.4184/asj.2007.1.1.27, indexed in Pubmed: 20411149.
- Kim SH, Shin HC, Shin DAH, et al. Early clinical experience with the mobi-C disc prosthesis. *Yonsei Med J.* 2007; 48(3): 457–464, doi: 10.3349/ymj.2007.48.3.457, indexed in Pubmed: 17594154.
- Koletsis DD, Halazonetis DJ. Cervical vertebrae anomalies in orthodontic patients: a growth-based superimpositional approach. *Eur J Orthod.* 2010; 32(1): 36–42, doi: 10.1093/ejo/cjp049, indexed in Pubmed: 19525440.
- Koutsouraki E, Avdelidi E, Michmizos D, et al. Kimmerle's anomaly as a possible causative factor of chronic tension-type headaches and neurosensory hearing loss: case report and literature review. *Int J Neurosci.* 2010; 120(3): 236–239, doi: 10.3109/00207451003597193, indexed in Pubmed: 20374094.
- Krishnamurthy A, Nayak SR, Khan S, et al. Arcuate foramen of atlas: incidence, phylogenetic and clinical significance. *Rom J Morphol Embryol.* 2007; 48(3): 263–266, indexed in Pubmed: 17914493.
- Lamberty BG, Zivanović S. The retro-articular vertebral artery ring of the atlas and its significance. *Acta Anat (Basel).* 1973; 85(1): 113–122, indexed in Pubmed: 4197316.

26. Leonardi R, Santarelli A, Barbato E, et al. Atlanto-occipital ligament calcification: a novel sign in nevoid basal cell carcinoma syndrome. *Anticancer Res.* 2010; 30(10): 4265–4267, indexed in Pubmed: 21036751.
27. Segatto E, Segatto A, Braunitzer G, et al. Sagittal spinal posture in relation to craniofacial morphology. *Angle Orthod.* 2006; 76(4): 625–631, doi: 10.1043/0003-3219(2006)076[0625:SSPIRT]2.0.CO;2, indexed in Pubmed: 16808569.
28. Paraskevas G, Papaziogas B, Tsonidis C, et al. Gross morphology of the bridges over the vertebral artery groove on the atlas. *Surg Radiol Anat.* 2005; 27(2): 129–136, doi: 10.1007/s00276-004-0300-9, indexed in Pubmed: 15800734.
29. Pyo J, Lowman RM. The ponticulus posticus of the first cervical vertebra. *Radiology.* 1959; 72(6): 850–854, doi: 10.1148/72.6.850, indexed in Pubmed: 13668093.
30. Pękala PA, Henry BM, Pękala JR, et al. Prevalence of foramen arcuale and its clinical significance: a meta-analysis of 55,985 subjects. *J Neurosurg Spine.* 2017; 27(3): 276–290, doi: 10.3171/2017.1.SPINE161092, indexed in Pubmed: 28621616.
31. Sabir H, Kumbhare S, Rout P. Evaluation of ponticulus posticus on digital lateral cephalograms and cone beam computed tomography in patients with migraine and healthy individuals: a comparative study. *Oral Surg Oral Med Oral Pathol Oral Radiol.* 2014; 118(3): 348–354, doi: 10.1016/j.oooo.2014.04.016, indexed in Pubmed: 25151589.
32. Sekerci AE, Soylu E, Arikan MP, et al. Is there a relationship between the presence of ponticulus posticus and elongated styloid process? *Clin Imaging.* 2015; 39(2): 220–224, doi: 10.1016/j.clinimag.2014.11.016, indexed in Pubmed: 25497077.
33. Sekerci AE, Soylu E, Arikan MP, et al. Prevalence and morphologic characteristics of ponticulus posticus: analysis using cone-beam computed tomography. *J Chiropr Med.* 2015; 14(3): 153–161, doi: 10.1016/j.jcm.2015.06.003, indexed in Pubmed: 26778928.
34. Sharma V, Chaudhary D, Mitra R. Prevalence of ponticulus posticus in Indian orthodontic patients. *Dentomaxillofac Radiol.* 2010; 39(5): 277–283, doi: 10.1259/dmfr/16271087, indexed in Pubmed: 20587651.
35. Silva MB, Gois BC, Sant’Anna EF. Evaluation of the reliability of measurements in cephalograms generated from cone beam computed tomography. *Dental Press J Orthod.* 2013; 18(4): 53–60, indexed in Pubmed: 24262417.
36. Sonnesen L. Associations between the cervical vertebral column and craniofacial morphology. *Int J Dent.* 2010; 2010: 295728, doi: 10.1155/2010/295728, indexed in Pubmed: 20628592.
37. Takaaki M, Masanori O, Hidenori U, et al. Ponticulus posticus: Its clinical significance. *Acta Med Kinki Univ.* 1979; 4: 427–430.
38. Zhang XL, Huang DG, Wang XD, et al. The feasibility of inserting a C1 pedicle screw in patients with ponticulus posticus: a retrospective analysis of eleven patients. *Eur Spine J.* 2017; 26(4): 1058–1063, doi: 10.1007/s00586-016-4589-y, indexed in Pubmed: 27246351.