

Prevalence and morphometric analysis of idiopathic osteosclerosis in a Chilean population

R. Fuentes^{1, 2}, A. Arias^{1, 2, 3, 4}, N. Astete³, C. Farfán³, I. Garay¹, F. Dias^{1, 2}

¹Department of Integral Adults Dentistry, Dental School, Universidad de La Frontera, Temuco, Chile

²Research Centre in Dental Sciences (CICO), Dental School, Universidad de La Frontera, Temuco, Chile

³Master's Program in Dentistry, Dental School, Universidad de La Frontera, Temuco, Chile

⁴Universidad Adventista de Chile, Chillán, Chile

[Received: 14 June 2017; Accepted: 4 August 2017]

Background: The aim of this study was to analyse the prevalence and morphometric parameters of idiopathic osteosclerosis (IO) in a Chilean population. IO is an intraosseous growth of compact, benign, unilocular, non-expandable bone that is referred to as an anatomical variation.

Materials and methods: A cross-sectional study was performed using 1000 digital panoramic radiographs of adults in which data on the location (maxillary/mandibular, right/left hemiarcades), shape, position to the dental apex, and the prevalence of IOs were observed in relation to gender and age. The morphometric parameters evaluated were area, height, width, and the linear distances of the IO up to the midline and at the base of the mandible.

Results: The overall prevalence was 2.8% (27 individuals), with the majority of cases in women (66.7%) in the second, third, and fifth decades of life, but without significant differences. All cases were present in the mandible (100%), usually in the left hemiarcade (59.3%), molar (48.2%) and premolar (44.4%) regions; at the height of the dental apices (65.5%), with an irregular shape (40.7%) and round (37%). The area of the IOs was $33.9 \pm 20.1 \text{ mm}^2$, with a height of $7.7 \pm 3.1 \text{ mm}$, width of $6.6 \pm 3.1 \text{ mm}$, and the distance from the IO to the mandible median line was $26.6 \pm 10.7 \text{ mm}$ and $9.7 \pm 3.7 \text{ mm}$ to the mandibular base.

Conclusions: All the data observed corroborate with previous studies; the IO does not present a large difference in the Chilean population evaluated compared to previous studies carried out in other populations. (Folia Morphol 2018; 77, 2: 272–278)

Key words: idiopathic osteosclerosis, prevalence, morphometry, Chilean population, digital panoramic radiographs

INTRODUCTION

Idiopathic osteosclerosis (IO) also called enostosis, bone islets, or periapical osteopetrosis [2], is an intraosseous and localised increment in the production of compact bone tissue located in both the maxillary and mandibular bone but preferring the premolar-molar area [11]. At the beginning of the twentieth century,

the IO began to be documented, referring to it as an anatomical variant [5]. IO is considered a benign, unilocular, and non-expansive lesion, with unknown aetiology and not attributable to any inflammatory process, dysplasia, neoplasia, or systemic disorder in its main characteristic [10], including the fact that it cannot be clearly attributed to identifiable sources of osteogenesis [4].

In terms of prevalence, it varies between 2.3% [12] and 11.8% [13], observed in schoolchildren, adolescents, and adults; there is no gender preference. However, some studies show a marked inclination in females [8, 10, 11]. Diagnosis of these lesions requires a radiographic and histopathological analysis to differentiate it from mainly radicular rest, condensing osteitis, cemental apical dysplasia, ossifying fibromas, osteomas, osteoblastomas, and cementoblastomas [2].

Digital panoramic radiography is a routine examination instrument for the clinician that possesses a high reliability to investigate and differentiate IOs from other radiopacities. Facing a real diagnostic doubt, cone-beam computed tomography represents the best method for confirming the location and state of radiopaque lesions of the jaw [1], but its cost is much higher and its disponibility in the clinic is lower. In dental radiography, the IO is observed as a radiopaque and localised area, with sizes ranging from 2 mm to 30 mm, with defined or diffuse limits, with round, elliptical, and irregular shape [2]. The objective of the present study was to determine the prevalence of IO and its morphometric characteristics in a digital panoramic radiograph sample obtained from a Chilean population.

MATERIALS AND METHODS

A cross-sectional descriptive study was carried out in 1000 digital panoramic radiographies (ratio 1:1) obtained from January to December of 2015 at the Dental Clinic of the School of Dentistry of the Universidad de La Frontera, Temuco, Chile. The digital radiographs were taken with a standard technique using the PAX-400C orthopantomograph (VATECH, Korea, 2010). This study was approved by the Scientific Ethics Committee (CEC) of Universidad de La Frontera (Folio no. 015/2014).

The use of the radiographs was allowed by the patients to whom the purpose of the research was explained, and they were asked to sign an informed consent. The authors would like to emphasise that the identity of these individuals was respected and protected. The radiographs analysed in this study corresponded to patients of known age and gender. The following exclusion criteria were applied to the total radiograph sample:

- radiographs with poor image quality (distortion or alteration of contrasts);
- evidence of intraosseous pathologies that affect the visibility of the area under study;

- presence of titanium plates and orthognathic surgery.

To correctly identify IOs, the following radiopacities were specifically excluded:

- radiopaque lesions associated with tooth apices with large restorations or deep caries lesions due to being a chronic inflammation process that can be associated with condensing osteitis;
- areas with mixed radiopacities located in relation to the tooth apex, where no periodontal space is observed, because of the association with periapical cementum dysplasia or benign fibrous lesions;
- dental remnants of a primary or permanent tooth;
- radiopacities associated with exostosis or torus (maxillar and/or mandibular);
- isolated radiopacities in edentulous areas that may be associated with excessive ossification at a post-surgical site.

All digital panoramic radiographs were projected onto a 29-inch LED monitor (LG, model 29UM67, resolution of 2560 × 1080 pixels). Two examiners previously calibrated with a dentomaxillofacial radiology specialist performed the examination. The calibration process was based on the calculation of the kappa coefficient (k) to identify the IOs and on the calculation of the intraclass correlation coefficient (ICC) for the measurements of distances. To perform the measurements, ImageJ software (version 1.45) was used to draw lines and to measure areas, distances, and angles. First, the area of the lesion was measured using the polygonal selection tool and through straight lines, variables such as width and length of the lesion were analysed (Fig. 1A) to apply classification criteria. Second, a reference median line (L1) was drawn from the anterior nasal spine to the inferior border of the mandible, and a second perpendicular line (L2) was drawn to measure the shortest distance from the IO to the median line or L1 (Fig. 1B). Finally, the distance between the IO and the lower edge of the mandible was measured through a third perpendicular line (L3) (Fig. 1C).

The following variables were analysed:

- the relationship of IOs with the teeth was based on Geist and Katz's [4] criteria. The IOs were classified as (1) "interradicular" if the lesion was limited to the area between the roots, (2) "apical and interradicular" if the radiopacities were detected at the apices and exhibited significant extension between the roots, (3) "apical" if the lesions were predominately located around the root apices,

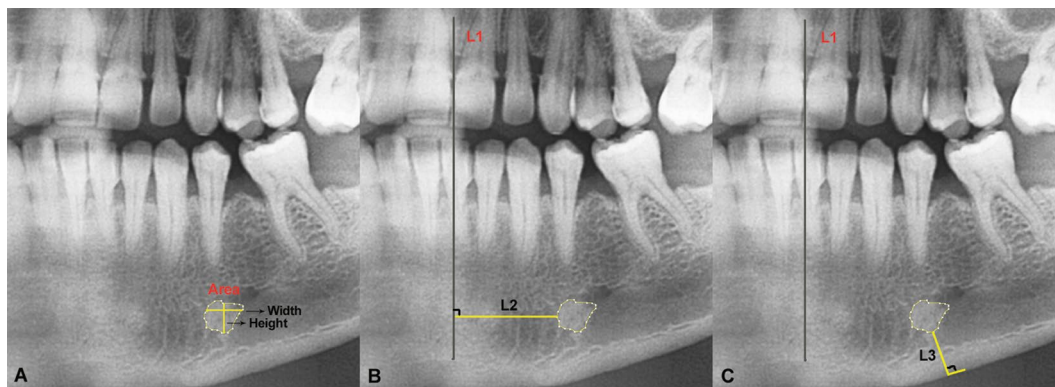


Figure 1. Morphometric analysis of idiopathic osteosclerosis (IO) using ImageJ; **A.** IO area, width, and height; **B.** L2 represents the shortest distance from the lesion to the midline (L1); **C.** L3 represents the shortest distance from the lesion to the base of the mandible (perpendicular).

and (4) “separate” if the radiopacities were apical to and clearly separated from the teeth and lamina dura.

— the shape of the IOs (round, elliptical, or irregular) [2].

The prevalence of IOs between different genders and age groups (decades) were compared using the χ^2 test ($p = 0.05$) through the statistical software SigmaPlot 12.0. The morphometric data were presented using boxplot graphs to better visualise the distribution of the values obtained in each analysed morphometric parameter. In addition, the mean \pm standard deviation, median (Q1: 25%; Q3: 75%), and the total range of variation were also presented in the present study.

RESULTS

Once the exclusion criteria had been applied, 957 digital panoramic radiographs were included. The ICC in the interoperator concordance analysis was 99% (very good concordance), while the k coefficient was 100%. The prevalence of IO was 29 cases in 27 (2.82%) individuals in a population aged 13 to 57 years, with an average age of 30.9 years. In women, 18 (66.7%) cases were observed between 13 and 52 years of age and 9 (33.3%) cases in men between 15 to 57 years of age.

Even with a large majority of cases in females, there was no significant difference when comparing the prevalence between genders ($p = 0.219$). The distribution of cases by age group showed that 25.9% of the cases were in people in the second decade of life (11–20 years), 33.3% in the third decade (21–30 years), 7.4% in the fourth (31–40 years) and sixth decades (51–60 years), and 25.9% in the fifth decade (41–50 years) (Fig. 2A). The statistical evaluation of the age groups showed no differences ($p = 0.483$),

even with a large majority of cases in the second and third decades of life.

All 27 (100%) cases were observed in the mandible; 11 (40.7%) were in the right and 16 (59.3%) were in the left hemiarch. One (3.7%) case was observed in the incisor tooth region, 1 (3.7%) case in the canine region, 12 (44.4%) in the premolar region, and 13 (48.2%) in the molar region. Regarding their position in relation to the tooth, 1 (3.4%) case was in the apical and interradicular position, 1 (3.4%) was in the interradicular position, 8 (27.6%) were separate from the tooth, and 19 (65.5%) were in the apical position to the dental apices. According to their classification by the shape of the structure, 10 (37%) cases were round, 6 (22.2%) elliptical, and 11 (40.7%) irregular.

Morphometric analysis

Data from the morphometric analysis of the IOs obtained from digital panoramic radiographs are presented below. The mean area of the IOs was $33.9 \pm 20.1 \text{ mm}^2$, with a non-normal distribution whose median value was 29.5 mm^2 (Q1: 19.7, Q3: 40.1 mm^2). The values of this parameter presented a variation from 11.5 to 93.2 mm^2 among the 29 cases analysed from digital panoramic radiographs (Fig. 2B).

The morphometric data regarding IO height showed values from 3.3 to 15.6 mm, with a mean of $7.7 \pm 3.1 \text{ mm}$; these values presented a non-normal distribution with a median of 7.4 mm (Q1: 5.4, Q3: 8.9 mm) (Fig. 2C). The width of the IOs revealed a mean of $6.6 \pm 3.1 \text{ mm}$, with normal distribution and values ranging from 3.3 to 10.6 mm and median 6.2 mm (Q1: 5.34, Q3: 8 mm) (Fig. 2D).

The linear distance data revealed values of 10.5 to 45.9 mm from the IO to the mandibular midline;

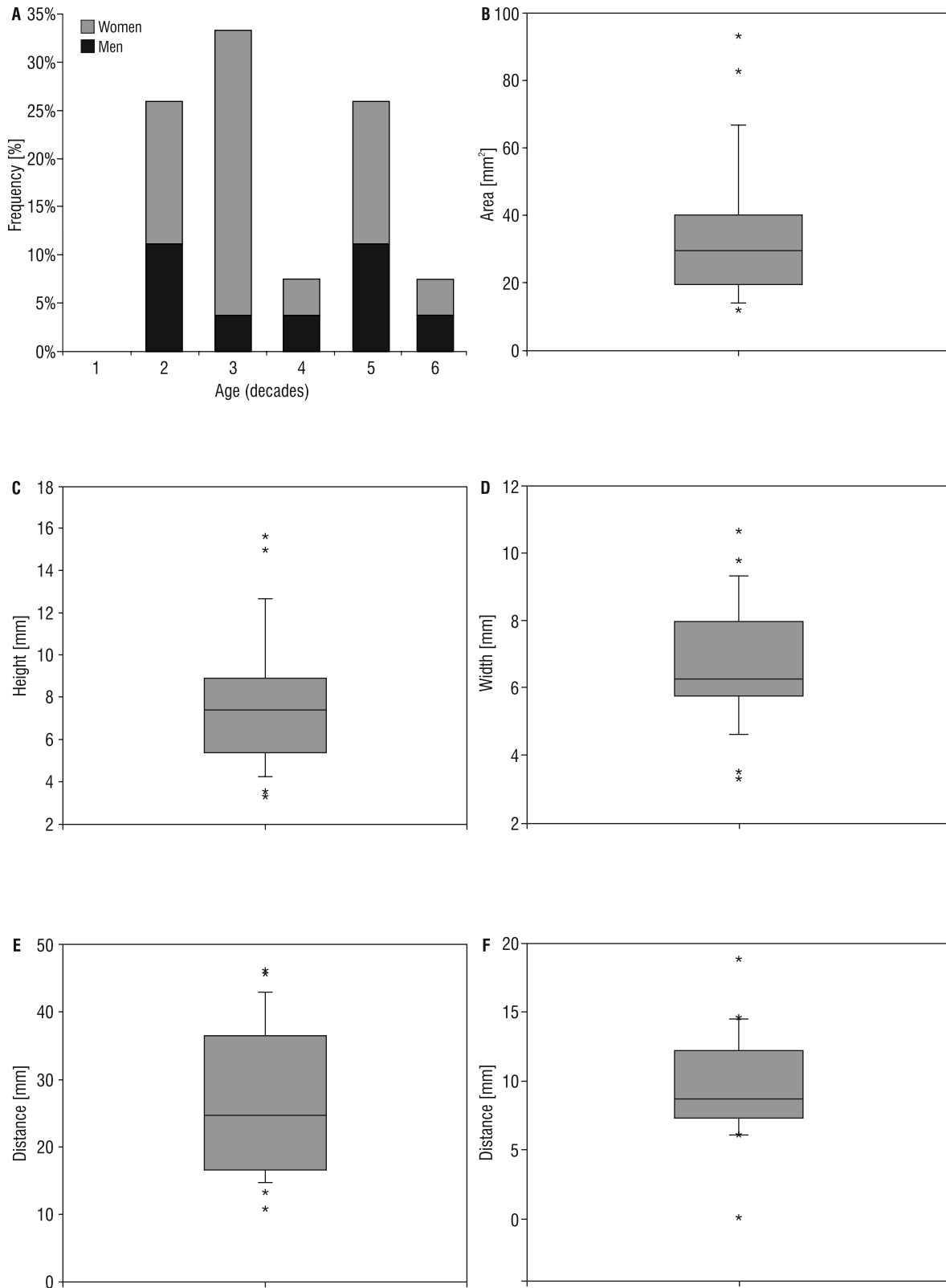


Figure 2. Prevalence of idiopathic osteosclerosis (IO) cases; **A.** Distribution of IO cases in different genders and age groups (decades of life). Morphometric analysis; **B.** Distribution of the area of IO cases; **C.** Height distribution of IO cases; **D.** Width distribution of IO cases; **E.** Distribution of the linear distance from the IO to the mandibular midline; **F.** Distribution of the linear distance from the IO to the base of the mandible.

Table 1. Summary of prevalence of idiopathic osteosclerosis (IOs) reported in different populations

Study	Country	Sample	Prevalence of OIs
Solanki et al. 2015 [13]	India	750 panoramic radiographs	11.8%
Kawai et al. 1992 [7]	Japan	1205 panoramic radiographs	9.7%
Moshfeghi et al. 2013 [11]	Iran	787 radiographs	9.5%
Halse and Molven, 2002 [6]	Norway	210 radiographs	7.6%
Farhadi et al. 2016 [3]	Iran	411 panoramic radiographs	7.5%
Yonetsu et al. 1997 [18]	Japan	1047 panoramic radiographs	6.1%
Williams and Brooks, 1998 [17]	United States	1585 panoramic radiographs	5.7%
Geist and Katz, 1990 [4]	United States	1921 panoramic radiographs	5.5%
MacDonald-Jankowski, 1999 [8]	China (Hong Kong, 1981)	985 panoramic radiographs	6.7%
	China (Hong Kong, 1990)	977 panoramic radiographs	5.5%
	United Kingdom (London, 1990)	985 panoramic radiographs	2.7%
	United Kingdom (Edinburgh, 1993)	193 panoramic radiographs	4.1%
Miloglu et al. 2009 [10]	Turkey	6154 panoramic radiographs	2.4%
Petrikowski and Peters, 1997 [12]	Canada	2991 panoramic radiographs	2.3%

for data with normal distribution, the mean value was 26.6 ± 10.7 mm and the median was 24.7 mm (Q1: 16.8, Q3: 36.5 mm) (Fig. 2E). The distance from the lesion to the inferior border of the mandible presented values ranging from 0.04 to 18.8 mm with a normal distribution whose mean was 9.7 ± 3.7 mm and a median of 8.8 mm (Q1: 7.3, Q3: 12.2 mm) (Fig. 2F).

DISCUSSION

Many studies have evaluated the prevalence of OIs in different populations, which varies between 11.8% and 2.3% (Table 1). Our results revealed 29 cases of radiographic findings in 27 individuals, corresponding to a prevalence of 2.8% of IO, a relatively low percentage in the literature. Although there are studies that reported prevalence values similar to those revealed in our study, a wide variation in this data is noted. This variation may be due to genetic and environmental factors of each population; however, we cannot disregard that this disagreement may be due to difficulties of definition and identification of this anatomical alteration by these research groups, or even the quality of the radiographic examinations.

In general terms, Eastern populations have a higher prevalence of OIs compared to Western populations [7, 8, 11–13, 17], with a female predilection but without significant differences compared to men [3, 4, 6, 7, 10–12, 17, 18]. Contrary to these results,

Mcdonnel [9] showed a preference in women of this radiopacity with 67.3%; however, it is a controversial study due to mistakenly encompassing other radioactivities of clearly different origin than the IOs. In addition, MacDonald-Jankowski [8] revealed a different prevalence by gender in two populations, Chinese women and British men. According to our results, the prevalence of IO cases was higher in women (66.7%) than in men (33.3%), but without significant differences; thus, our results are in agreement with most of the previous studies in the literature. In addition, our results showed a higher prevalence in individuals in the second, third, and fifth decades of life, just like the previous study by Kawai et al. [7], but without significant difference.

Only a few recent studies have evaluated the IO shape [3, 10, 11], reporting that the round and irregular shapes were the most predominant, which agreed with the observations of our study, where the irregular (40.74%) and round (37.04%) shapes were more frequent. All the IO cases reported in our study were located in the mandible; 59.3% were located in the left and 40.7% in the right hemiarchs. The most frequent location was observed at the molar (48.15%) and premolar (44.43%) regions. The data found corroborates with other studies where IO cases are usually found in the mandible, above 90% [3, 4, 7, 9, 11, 18]. Only one study [9] reported the IO prevalence in the hemiarchs, also showing a predominance in the

left side (53.2%). The middle and posterior regions of the mandible have been the most affected by IOs, and the molar region remains the most prevalent [7, 9, 18] followed by the premolar region [3, 4, 10, 11, 17]; these data also agreed with our study data.

The literature documents that IOs are located more frequently at the separate or apical level of the teeth [3, 4, 7, 10, 11]. The relationship observed in our study was “apical” (65.51%), similar to results by Geist and Katz [4] and Farhadi et al. [3], followed by the “separated” position of the teeth (27.58%), similar to Kawai et al. [7], Miloglu et al. [10] and Moshfeghi et al. [11] which were the most prevalent relationships. The “interradicular” and “apical and interradicular” positions were the least frequent, different from data reported by Williams et al. [17] in which the interradicular position was the most prevalent of all at 42%.

In addition to data on the prevalence, shape, and location of IOs, our study also performed morphometric evaluations of these anatomical variants. It was observed that the area of these lesions presented a wide variation, with a mean value of $33.9 \pm 20.1 \text{ mm}^2$. The linear distance data of IOs to the midline revealed a mean value of $26.6 \pm 10.8 \text{ mm}$, considering the distortion of the panoramic radiographs, which corroborates with the previous observations of this study regarding the location of the lesions in the posterior areas of the premolars and molars. The distance from these lesions to the lower border of the mandible revealed an average value of $9.7 \pm 3.7 \text{ mm}$. In addition, measurements of height and width were performed with mean values of $7.7 \pm 3.1 \text{ mm}$ and $6.6 \pm 3.1 \text{ mm}$, respectively, showing a predominance of height over width. The previous studies that performed morphometric evaluations of IOs [8, 15, 17] analysed parameters of linear measures called “size” or “diameter”. The values found ranged from 1 to 22 mm [17], from 3.2 to 8.8 mm [8], and from 1.5 to 18 mm [15], and mean values of $6.4 \pm 2.8 \text{ mm}$ [16], and $6.84 \pm 3.1 \text{ mm}$ [14]. The values of height and width in our study presented averages similar to those reported in these studies, besides the amplitude of variation (height of 3.3 to 15.6 mm, width of 3.3 to 10.6 mm) within the aforementioned variation. A study of the height and width of these anatomical variations [17] with a mean of 5.8 mm in height and 5.5 mm in width also shows a predominance of height. Other morphometric data could not be compared since no previous reports were found in the literature. However, these morphometric

parameters served to improve the description and understanding of these anatomical variations.

The main limitation of this study is related to the use of panoramic radiographs to evaluate the IOs, mainly with respect to the morphometric analyses due to the possible distortions and the two-dimensional analysis. However, we justify the use of this modality of analysis due to the greater availability of cases compared to other methods of evaluation.

CONCLUSIONS

The prevalence of IO was 2.8% among the patients evaluated, presenting most frequently in the mandible in the area of the premolars and molars. Without significant difference by gender and age, but with preference in women and individuals, all these data along with the morphometric parameters evaluated corroborate with most of the previous studies. Thus, this anatomical variation does not present large differences between the Chilean population evaluated and the other populations previously described in the literature.

Funding

Financial support (partially) by the Office of Research, Universidad de La Frontera.

REFERENCES

1. Araki M, Hashimoto K, Kawashima S, et al. Radiographic features of enostosis determined with limited cone-beam computed tomography in comparison with rotational panoramic radiography. *Oral Radiol.* 2006; 22(1): 27–33, doi: [10.1007/s11282-006-0044-9](https://doi.org/10.1007/s11282-006-0044-9).
2. Bsoul S, Alborz S, Terezhalmay G, et al. Idiopathic osteosclerosis (enostosis, dense bone islands, focal periapical osteopetrosis). *Quintessence Int.* 2004; 35(7): 590–591.
3. Farhadi F, Ruhani MR, Zarandi A. Frequency and pattern of idiopathic osteosclerosis and condensing osteitis lesions in panoramic radiography of Iranian patients. *Dent Res J (Isfahan).* 2016; 13(4): 322–326, indexed in Pubmed: [27605989](https://pubmed.ncbi.nlm.nih.gov/27605989/).
4. Geist JR, Katz JO. The frequency and distribution of idiopathic osteosclerosis. *Oral Surg Oral Med Oral Pathol.* 1990; 69(3): 388–393, indexed in Pubmed: [2314866](https://pubmed.ncbi.nlm.nih.gov/2314866/).
5. Greenspan A. Bone island (enostosis): current concept — a review. *Skeletal Radiol.* 1995; 24(2): 111–115, indexed in Pubmed: [7747175](https://pubmed.ncbi.nlm.nih.gov/7747175/).
6. Halse A, Molven O. Idiopathic osteosclerosis of the jaws followed through a period of 20-27 years. *Int Endod J.* 2002; 35(9): 747–751, doi: [10.1046/j.1365-2591.2002.00561.x](https://doi.org/10.1046/j.1365-2591.2002.00561.x), indexed in Pubmed: [12449025](https://pubmed.ncbi.nlm.nih.gov/12449025/).
7. Kawai T, Hirakuma H, Murakami S, et al. Radiographic investigation of idiopathic osteosclerosis of the jaws in Japanese dental outpatients. *Oral Surg Oral Med Oral Pathol.* 1992; 74(2): 237–242, indexed in Pubmed: [1508535](https://pubmed.ncbi.nlm.nih.gov/1508535/).

8. MacDonald-Jankowski DS. Idiopathic osteosclerosis in the jaws of Britons and of the Hong Kong Chinese: radiology and systematic review. *Dentomaxillofac Radiol.* 1999; 28(6): 357–363, doi: [10.1038/sj/dmfr/4600485](https://doi.org/10.1038/sj/dmfr/4600485), indexed in Pubmed: [10578190](https://pubmed.ncbi.nlm.nih.gov/10578190/).
9. McDonnell D. Dense bone island. A review of 107 patients. *Oral Surg Oral Med Oral Pathol.* 1993; 76(1): 124–128, indexed in Pubmed: [8351108](https://pubmed.ncbi.nlm.nih.gov/8351108/).
10. Miloglu O, Yalcin E, Buyukkurt MC, et al. The frequency and characteristics of idiopathic osteosclerosis and condensing osteitis lesions in a Turkish patient population. *Med Oral Patol Oral Cir Bucal.* 2009; 14(12): e640–e645, indexed in Pubmed: [19680185](https://pubmed.ncbi.nlm.nih.gov/19680185/).
11. Moshfeghi M, Azimi F, Anvari M. Radiologic assessment and frequency of idiopathic osteosclerosis of jawbones: an interpopulation comparison. *Acta Radiol.* 2014; 55(10): 1239–1244, doi: [10.1177/0284185113515210](https://doi.org/10.1177/0284185113515210), indexed in Pubmed: [24316662](https://pubmed.ncbi.nlm.nih.gov/24316662/).
12. Petrikowski CG, Peters E. Longitudinal radiographic assessment of dense bone islands of the jaws. *Oral Surg Oral Med Oral Pathol Oral Radiol Endod.* 1997; 83(5): 627–634, indexed in Pubmed: [9159826](https://pubmed.ncbi.nlm.nih.gov/9159826/).
13. Solanki J, Jain R, Singh R, et al. Prevalence of Osteosclerosis Among Patients Visiting Dental Institute in Rural Area of Western India. *J Clin Diagn Res.* 2015; 9(8): ZC38–ZC40, doi: [10.7860/JCDR/2015/11439.6319](https://doi.org/10.7860/JCDR/2015/11439.6319), indexed in Pubmed: [26436044](https://pubmed.ncbi.nlm.nih.gov/26436044/).
14. Tenorio-Estrada JK, Quezada-Marquez MM, Evangelista-Alva A. Imaginological idiopathic osteo-sclerosis characteristic of the jaws evaluated with cone beam computed tomography. *Rev Estomatol Herediana.* 2015; 25(2): 100–111.
15. Tolentino Ed, Gusmão PH, Cardia GS, et al. Idiopathic Osteosclerosis of the Jaw in a Brazilian Population: a Retrospective Study. *Acta Stomatol Croat.* 2014; 48(3): 183–192, doi: [10.15644/asc48/3/2](https://doi.org/10.15644/asc48/3/2), indexed in Pubmed: [27688365](https://pubmed.ncbi.nlm.nih.gov/27688365/).
16. Verzak Z, Celap B, Modrić VE, et al. The prevalence of idiopathic osteosclerosis and condensing osteitis in Zagreb population. *Acta Clin Croat.* 2012; 51(4): 573–577, indexed in Pubmed: [23540165](https://pubmed.ncbi.nlm.nih.gov/23540165/).
17. Williams TP, Brooks SL. A longitudinal study of idiopathic osteosclerosis and condensing osteitis. *Dentomaxillofac Radiol.* 1998; 27(5): 275–278, doi: [10.1038/sj/dmfr/4600362](https://doi.org/10.1038/sj/dmfr/4600362), indexed in Pubmed: [9879216](https://pubmed.ncbi.nlm.nih.gov/9879216/).
18. Yonetsu K, Yuasa K, Kanda S. Idiopathic osteosclerosis of the jaws: panoramic radiographic and computed tomographic findings. *Oral Surg Oral Med Oral Pathol Oral Radiol Endod.* 1997; 83(4): 517–521, indexed in Pubmed: [9127388](https://pubmed.ncbi.nlm.nih.gov/9127388/).